

## Approach to persistent ascites after liver transplantation

Ana Ostojic, Igor Petrovic, Hrvoje Silovski, Iva Kosuta, Maja Sremac, Anna Mrzljak

**Specialty type:** Transplantation

**Provenance and peer review:**

Invited article; Externally peer reviewed.

**Peer-review model:** Single blind

**Peer-review report's scientific quality classification**

Grade A (Excellent): 0

Grade B (Very good): 0

Grade C (Good): C, C

Grade D (Fair): 0

Grade E (Poor): 0

**P-Reviewer:** Tang W, China;

Tuysuz U, Turkey

**Received:** July 6, 2022

**Peer-review started:** July 6, 2022

**First decision:** July 28, 2022

**Revised:** August 8, 2022

**Accepted:** September 2, 2022

**Article in press:** September 2, 2022

**Published online:** September 27, 2022



**Ana Ostojic, Maja Sremac, Anna Mrzljak**, Department of Gastroenterology and Hepatology, University Hospital Center Zagreb, Zagreb 10000, Croatia

**Igor Petrovic, Hrvoje Silovski**, Department of Hepatobiliary Surgery and Transplantation, University Hospital Center Zagreb, Zagreb 10000, Croatia

**Iva Kosuta**, Department of Intensive Care Medicine, University Hospital Center Zagreb, Zagreb 10000, Croatia

**Corresponding author:** Anna Mrzljak, FEBG, PhD, Associate Professor, Department of Gastroenterology and Hepatology, University Hospital Center Zagreb, Kišpatičeva ulica 12, Zagreb 10000, Croatia. [anna.mrzljak@gmail.com](mailto:anna.mrzljak@gmail.com)

### Abstract

Persistent ascites (PA) after liver transplantation (LT), commonly defined as ascites lasting more than 4 wk after LT, can be expected in up to 7% of patients. Despite being relatively rare, it is associated with worse clinical outcomes, including higher 1-year mortality. The cause of PA can be divided into vascular, hepatic, or extrahepatic. Vascular causes of PA include hepatic outflow and inflow obstructions, which are usually successfully treated. Regarding modifiable hepatic causes, recurrent hepatitis C and acute cellular rejection are the leading ones. Considering predictors for PA, the presence of ascites, refractory ascites, hepatorenal syndrome type 1, spontaneous bacterial peritonitis, hepatic encephalopathy, and prolonged ischemic time significantly influence the development of PA after LT. The initial approach to patients with PA should be to diagnose the treatable cause of PA. The stepwise approach in evaluating PA includes diagnostic paracentesis, ultrasound with Doppler, and an echocardiogram when a cardiac cause is suspected. Finally, a percutaneous or transjugular liver biopsy should be performed in cases where the diagnosis is unclear. PA of unknown cause should be treated with diuretics and paracentesis, while transjugular intrahepatic portosystemic shunt and splenic artery embolization are treatment methods in patients with refractory ascites after LT.

**Key Words:** Liver transplantation; Liver transplantation complications, Ascites; Hepatic graft inflow obstructions; Hepatic graft outflow obstructions; Acute cellular rejection

©The Author(s) 2022. Published by Baishideng Publishing Group Inc. All rights reserved.

**Core Tip:** Despite being relatively rare, persistent ascites after liver transplantation is associated with worse clinical outcomes. Therefore, it is of primary concern to promptly diagnose and treat modifiable causes of ascites. Early evaluation should include ultrasound with Doppler and diagnostic paracentesis. Common treatable causes include hepatic inflow and outflow obstruction, recurrent hepatitis C infection, and acute cellular rejection. Ascites of unknown cause should be treated with diuretics and paracentesis, while transjugular intrahepatic portosystemic shunt and splenic artery embolization can be used in patients with refractory ascites. The latter option represents a novel treatment modality with promising results.

**Citation:** Ostojic A, Petrovic I, Silovski H, Kosuta I, Sremac M, Mrzljak A. Approach to persistent ascites after liver transplantation. *World J Hepatol* 2022; 14(9): 1739-1746

**URL:** <https://www.wjgnet.com/1948-5182/full/v14/i9/1739.htm>

**DOI:** <https://dx.doi.org/10.4254/wjh.v14.i9.1739>

## INTRODUCTION

Ascites represents the most common manifestation of decompensated cirrhosis[1]. About 5% to 10% of patients with compensated cirrhosis develop ascites annually[1]. The presence of ascites in a patient with cirrhosis is associated with a poor prognosis, as transplant-free survival is about 50% at 1 year and 20% after 5 years after decompensation[2,3]. Splanchnic arterial vasodilation secondary to nitric oxide that results in reduced effective circulatory volume and renal sodium retention is the principal cause of ascites formation in cirrhotic patients[4,5]. Portal hypertension and an increase in hepatic lymph formation also contribute to these complications of cirrhosis[4,5]. Liver transplantation (LT) is the best treatment option for patients with decompensated cirrhosis and ascites, as it induces resolution of ascites by reversing hemodynamic derangements and functional renal impairment. However, small to moderate ascites after liver transplantation is frequent in the early postoperative period and usually resolve within 2 to 4 wk after transplantation[5]. Persistent ascites after LT, commonly defined as ascites lasting more than 4 wk after LT, is an infrequent complication with a reported incidence of 5-7% [6,7]. Despite being relatively rare, it is associated with worse clinical outcomes, including higher morbidity and reduced 1-year survival[6,7].

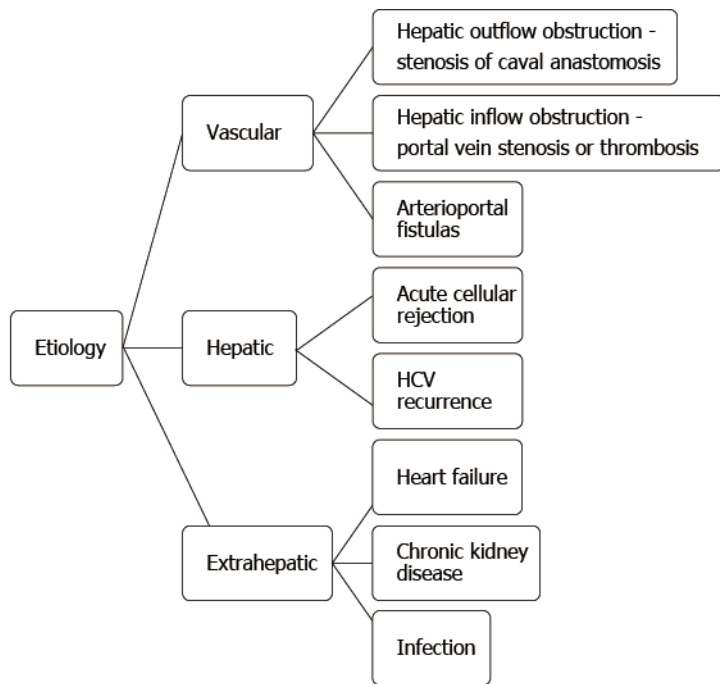
## ETIOLOGY

The etiology of persistent ascites after LT can be divided into vascular, hepatic, and extrahepatic causes (Figure 1).

### Vascular causes

Vascular causes of persistent ascites (PA) include hepatic outflow and inflow obstructions[8]. Inferior vena cava stenosis is a rare complication after LT, with a reported incidence of 1%[9]. This commonly iatrogenic complication is usually located at the anastomosis site or just superior to it[9]. According to the results of Cirera *et al*[6], the principal mechanism for massive ascites formation after LT is postsinusoidal portal hypertension secondary to hepatic vein outflow difficulty. In their work, from the hemodynamic data, the gradient between free hepatic vein pressure and right atrial pressure was significantly greater in patients who developed ascites than in patients who did not. However, ascites only was detected when the wedged hepatic venous pressure that mirrors sinusoidal pressure overcomes the threshold of 12 mmHg. Because evident stenosis or thrombosis in the studied population was detected in just 1 patient with ascites, hepatic vein outflow difficulty was probably due to a kinking of inferior caval vein or graft malposition. This explanation is supported by the resolution of ascites after reconstruction of caval anastomosis in some patients. Furthermore, in the same study, inferior vena cava preservation with the piggyback technique was performed more frequently in patients with PA after LT (72% *vs* 41%;  $P = 0.01$ )[6]. After analysis of these results, they changed the piggyback technique that previously included the origin of the left and medium hepatic veins to all three hepatic veins to ease venous graft drainage. Following this change, massive ascites in their patients have become extremely rare. The study by Nishida *et al*[10] confirmed that outflow obstruction due to stenosis of caval anastomosis is the cause of PA after LT, regardless of the type of vena cava anastomosis piggyback or caval anastomosis.

Portal vein stenosis and portal vein thrombosis are rare causes of PA after LT, with an incidence of 1%-2%[11]. Bonnel *et al*[12] showed that portal vein thrombosis after LT is more common in patients with prior PVT history. Hepatic artery to portal vein fistula is an infrequent complication after LT, and according to published case reports, patients with this type of vascular abnormality can present with ascites[8]. Arteriportal fistulas are associated with percutaneous transhepatic procedures such as



Risk factors	
Pretransplant	Perioperative
Ascites	Prolonged cold ischemic time
Refractory ascites	Spleen/graft ratio, graft recipient weight ratio
Hepatorenal-syndrome type 1	
Spontaneous bacterial peritonitis	
Hepatic encephalopathy	

DOI: 10.4254/wjh.v14.i9.1739 Copyright ©The Author(s) 2022.

Figure 1 Etiology and risk factors of persistent ascites after liver transplantation.

percutaneous liver biopsies and percutaneous transhepatic cholangiograms with or without percutaneous biliary drain placement[13].

**Hepatic causes**

Acute cellular rejection with decreased liver vascular compliance during the rejection episode is one of the proposed mechanisms of ascites formation after LT[14,15]. This theory is supported by the results of the study by Gadano *et al*[16], where patients with severe acute rejection had a higher hepatic venous pressure gradient than those with moderate or mild rejection. Following the treatment of acute cellular rejection, ascites usually resolves[17].

Stewart *et al*[5] demonstrated that cirrhosis induced by hepatitis C as well as recurrent hepatitis C contribute to PA after LT. Based on histologic findings, most patients with recurrent hepatitis C and PA had cirrhosis or bridging fibrosis, well-known factors associated with portal hypertension and ascites. However, it should be emphasized that PA can develop in patients with recurrent hepatitis C without significant fibrosis[18-20].

In the study by Lan *et al*[18] among 173 hepatitis C virus (HCV) transplants, 18 patients (10%) developed posttransplant ascites, with two-thirds of ascites episodes occurring without significant fibrosis. In the retrospective study of 82 liver transplant recipients with HCV recurrence, 17% of patients developed refractory ascites, and in some patients, refractory ascites occurred in the absence of advanced fibrosis[19]. In the same study, positive cryoglobulinemia that was systematically tested ( $P = 0.02$ ) and perisinusoidal fibrosis at 1 year ( $P = 0.02$ ) were independently associated with posttransplant ascites[19]. These results indicate that liver microangiopathy is involved in the development of ascites in patients with recurrent HCV after LT. Nevertheless, this cause of PA will most likely become uncommon in the era of widespread use of direct-acting antivirals.

Considering pretransplant predictors for PA, the presence of ascites, refractory ascites, hepato-renal syndrome type 1, spontaneous bacterial peritonitis, and hepatic encephalopathy significantly influence the development of PA after LT[5,7,19]. Male sex was also found to be a strong risk factor for PA after LT[6]. However, data on sex as a risk factor for this complication are conflicting[18]. Factors associated

with the surgical procedure, such as cold ischemic (CI) time and size of the graft, contribute to PA after LT[5,21]. Several studies have shown that prolonged CI significantly influences PA development after LT[5,6,18]. Considering that CI time plays a significant part in the ischemic injury of the liver that primarily damages sinusoidal endothelium and results in increased hepatic resistance, PA can be expected if CI is prolonged[17,18]. A retrospective study involving 439 patients after living donor liver transplantation found that recipient spleen to graft volume ratio > 1.3, left lobe graft and graft recipient weight ratio < 0.8 were risk factors for persistent massive ascites after LT[22]. In the same study, pretransplant serum creatinine > 1.5 mg/dL and more than 1000 mL ascites at laparotomy were also risk factors for PA after LT. These five perioperative risk factors were used to develop the clinical scoring system (range from 0 to 7) for predicting PA after LT. Based on their internal validation, a cut-off of 4 points might be used as decision-changing, but only in cases of liver donor transplantation[22]. Finally, based on published case reports, PA after LT can occur due to sinusoidal obstruction syndrome, or it can be tacrolimus-induced[23,24].

### Extrahepatic causes

The workup of patients with PA after LT should be directed to exclude extrahepatic causes of ascites, such as heart failure, chronic renal disease, malignancy, or infection[17]. Finally, the etiology of PA after LT can remain unknown. One hypothesis is that this type of ascites result from persisting collateral circulation and large splanchnic blood volume resulting from a disproportion between portal venous blood volume and liver uptake[25-27].

---

## PROGNOSIS

The major negative impact of persistent ascites after LT is reduced patient survival[7,18]. In a retrospective study including 585 patients, PA was associated with reduced 1-year survival (92.3% vs 75.8%,  $P = 0.05$ )[7]. Nishida *et al*[10] showed that the mortality rate was nearly 8.6 times higher in patients with refractory ascites after LT while it was ongoing. However, the additional risk of death disappeared if the refractory ascites disappeared. In the same study, patients with an unknown reason for refractory ascites after LT had a significantly higher rate of RA disappearance[10]. Furthermore, persistent ascites after LT is associated with renal impairment, increased incidence of peritonitis and prolonged hospitalization[6].

---

## EVALUATION

Blood analysis should be performed to evaluate liver and renal function, including complete blood cell counts, liver enzymes, albumin level, immunosuppressant level, and renal parameters. There should be a low threshold to evaluate for viral causes, primarily hepatitis C, due to relatively high incidence and available treatment options. In cases where cardiac etiology is clinically possible, N-terminal pro B-type natriuretic peptide (NTproBNP) level should be measured. The next step should be a diagnostic paracentesis, primarily to evaluate for infections such as bacterial peritonitis. A serum to ascites albumin gradient should be determined. However, its use for the assessment of portal hypertension is limited in post-transplantation settings[17].

As proposed earlier, the next step in the evaluation should be an ultrasound of the abdomen with included Doppler to assess for mechanical obstructions (vascular pathology). During the examination, it is recommended to measure liver graft and spleen size and calculate spleen to graft volume ratio as it might influence the treatment modalities, depending on the final diagnosis[8,17,28]. Angiography and invasive hemodynamic evaluation should be performed as a confirmation method for suspected mechanical obstruction[8]. In most common cases of hepatic vein stenosis, an invasively measured gradient greater than three mmHg is considered significant[8,29]. An echocardiogram should be done when a cardiac cause is suspected or in cases of elevated NTproBNP levels.

A percutaneous or transjugular liver biopsy should be performed in cases where the diagnosis is unclear, when there is a high probability of rejection, or when the presence of hepatitis and fibrosis should be assessed[8,17]. Despite both available options, in our opinion, the transjugular approach is more relevant due to the additional information regarding invasive pressure gradients[8,10,30].

---

## TREATMENT

As aforementioned, the etiology of PA can be divided into vascular, hepatic, and extrahepatic. That being said, the primary goal of therapy should be directed toward the initial cause when one is known and it is modifiable. However, during diagnostic evaluation or when the cause of PA is unknown, the treatment approach to ascites after LT should follow the same principles as those in the pretransplant

**Table 1 Overview of etiology, diagnosis, and treatment options for persistent ascites after liver transplantation**

Etiology		Diagnosis	Treatment option <sup>1</sup>
Vascular	Hepatic outflow obstruction	Ultrasound of the abdomen with Doppler; Angiography and invasive hemodynamic evaluation	Balloon angioplasty +/- stent implantation; Surgical reconstruction
	Hepatic inflow obstruction		
	Arterioportal fistulas		
Hepatic	Acute cellular rejection	Evaluate liver function; Biopsy	Modify immunosuppressive therapy
	HCV recurrence	HCV serology; Biopsy	Antiviral drugs
Extrahepatic	Heart failure	NTproBNP; Echocardiogram	Treatment according to specialist recommendations
	Chronic kidney disease	Evaluate kidney function; Ultrasound	
	Infection	Paracentesis; Determine site of the infection	Antibiotics
Unknown cause or refractory ascites		Perform all above mentioned diagnostic procedures	Transjugular intrahepatic portosystemic shuntS- plenic artery embolization <sup>2</sup>

<sup>1</sup>All patients should be treated with diuretics, antiminerocorticoid drugs or furosemide, in conjunction with a moderate restriction of sodium intake.

<sup>2</sup>Consider splenic artery embolization as the first treatment option when the initial spleen to liver volume ratio is > 0.5.

HCV: Hepatitis C virus; NTproBNP: N-terminal pro B-type natriuretic peptide.

setting. Patients with moderate ascites should be treated with diuretics, anti-mineralocorticoid drugs or furosemide, in conjunction with a moderate restriction of sodium intake[4]. Large-volume paracentesis followed by plasma volume expansion is indicated in patients with large ascites or the case of refractory ascites[4]. Transjugular intrahepatic portosystemic shunt (TIPS) and splenic artery embolization (SAE) are treatment methods in patients with refractory ascites of unknown cause after LT. In a retrospective study by Saad *et al*[31], transplantation did not pose a technical challenge to TIPS creation. However, data on TIPS success in managing refractory ascites after LT are variable[31]. Nevertheless, most studies report 16% to 58% success, which is lower than in the pretransplant population[8]. This lower success of TIPS after LT can be due to the different pathophysiology of ascites after LT[8].

SAE is an emerging option for the treatment of PA after liver transplantation. The procedure itself has been widely used in multiple pathologies, including hematologic disorders and splenic trauma, just as in settings of chronic liver disease[32-34]. The idea behind the procedure is to cause a splenic infarction, which leads to decreased flow through the spleen with a consequent reduction in portal vein flow, portal pressure and hepatic congestion[28,35,36]. Based on published reports, the procedure is effective when the initial spleen to liver volume ratio is > 0.5[28,35,37,38]. Efficacy of the SAE can be almost immediately observed as the reduction in portal vein velocities. The procedure is considered relatively safe. In the largest report presented by Presser *et al*[38], only 1 of 54 patients developed post-splenectomy syndrome. However, severe complications have been described, including splenic abscess and perforation or pancreatitis[35]. It has been recommended to perform proximal rather than distal SAE, as it induces a reduction of the flow while allowing distal revascularization, minimizing the risk of complications[8].

Vascular complications causing stenosis are considered completely curable when diagnosed and treated promptly[17]. The most common of those, stenosis of the hepatic vein, is easily treated with plain balloon angioplasty. Successful procedure results in immediate resolution of pressure gradient followed by early clinical resolution of ascites[8,29]. However, a stent should be placed in cases who are irresponsive to balloon angioplasty or those who develop “restenosis” due to recoil[39,40]. The procedure is safe without significant complications and can be performed irrespective of the type of surgical anastomosis made. The same approach is used in the case of portal vein stenosis with a similar success rate. A somewhat higher risk of primarily bleeding complications relates to the transhepatic approach. However, they can be successfully treated with embolization[41]. On the other hand, stenosis of the inferior vena cava is usually iatrogenic or connected to scar formation. Because of this, larger balloons with multiple inflations are needed to achieve adequate results. For the same reason, stent placement is more common than other types of stenosis[8].

Hepatic causes, including recurrent hepatitis C and acute cellular rejection, should be treated following the latest guidelines. In the case of peritonitis, empirical intravenous antibiotics should be started immediately as the prognosis of patients with bacterial peritonitis as a cause of ascites after LT is associated with poor outcomes[10]. A brief overview of etiology, diagnosis and treatment options is summarized in Table 1.

## CONCLUSION

In summary, persistent ascites after LT is an infrequent complication associated with higher morbidity and mortality. The PA can result from vascular complications, or hepatic and extrahepatic diseases can cause it. The initial approach to the patient with PA should be directed to diagnose a modifiable cause and treat accordingly. If the etiology of PA remains unknown, treatment of ascites includes diuretics and paracentesis. TIPS or SAE should be offered when conservative treatment fails. TIPS in posttransplant settings is less effective for the treatment of ascites, while SAE is emerging as a potential alternative treatment option that is considered relatively safe.

## FOOTNOTES

**Author contributions:** Ostojic A contributed to the literature review, analysis, and interpretation of the data, drafting of the initial manuscript, and final approval of the manuscript; Petrovic I, Silovski H, Kosuta I, and Sremac M contributed to the analysis and interpretation of the data, and final approval of the manuscript; Mrzljak A contributed to the conception and design of the manuscript, critical revised the initial manuscript, and approved the final manuscript.

**Supported by** the Croatian Science Foundation, Emerging and Neglected Hepatotropic Viruses after Solid Organ and Hematopoietic Stem Cell Transplantation (to Mrzljak A), No. IP-2020-02-7407.

**Conflict-of-interest statement:** The authors have no conflicts of interest to declare.

**Open-Access:** This article is an open-access article that was selected by an in-house editor and fully peer-reviewed by external reviewers. It is distributed in accordance with the Creative Commons Attribution NonCommercial (CC BY-NC 4.0) license, which permits others to distribute, remix, adapt, build upon this work non-commercially, and license their derivative works on different terms, provided the original work is properly cited and the use is non-commercial. See: <https://creativecommons.org/licenses/by-nc/4.0/>

**Country/Territory of origin:** Croatia

**ORCID number:** Ana Ostojic 0000-0003-4234-4461; Igor Petrovic 0000-0002-9642-3774; Hrvoje Silovski 0000-0001-7884-8923; Iva Kosuta 0000-0002-1342-8722; Maja Sremac 0000-0002-3211-4569; Anna Mrzljak 0000-0001-6270-2305.

**S-Editor:** Wu YXJ

**L-Editor:** Filipodia

**P-Editor:** Wu YXJ

## REFERENCES

- 1 **Ginés P**, Quintero E, Arroyo V, Terés J, Bruguera M, Rimola A, Caballería J, Rodés J, Rozman C. Compensated cirrhosis: natural history and prognostic factors. *Hepatology* 1987; **7**: 122-128 [PMID: 3804191 DOI: 10.1002/hep.1840070124]
- 2 **Arroyo V**, Ginés P, Planas R, Panés J, Rodés J. Management of patients with cirrhosis and ascites. *Semin Liver Dis* 1986; **6**: 353-369 [PMID: 3544228 DOI: 10.1055/s-2008-1040617]
- 3 **European Association for the Study of the Liver**. EASL clinical practice guidelines on the management of ascites, spontaneous bacterial peritonitis, and hepatorenal syndrome in cirrhosis. *J Hepatol* 2010; **53**: 397-417 [PMID: 20633946 DOI: 10.1016/j.jhep.2010.05.004]
- 4 **European Association for the Study of the Liver**. EASL Clinical Practice Guidelines for the management of patients with decompensated cirrhosis. *J Hepatol* 2018; **69**: 406-460 [PMID: 29653741 DOI: 10.1016/j.jhep.2018.03.024]
- 5 **Stewart CA**, Wertheim J, Olthoff K, Furth EE, Brensinger C, Markman J, Shaked A. Ascites after liver transplantation--a mystery. *Liver Transpl* 2004; **10**: 654-660 [PMID: 15108257 DOI: 10.1002/Lt.20106]
- 6 **Cirera I**, Navasa M, Rimola A, García-Pagán JC, Grande L, Garcia-Valdecasas JC, Fuster J, Bosch J, Rodes J. Ascites after liver transplantation. *Liver Transpl* 2000; **6**: 157-162 [PMID: 10719013 DOI: 10.1002/Lt.500060219]
- 7 **Gotthardt DN**, Weiss KH, Rathenber V, Schemmer P, Stremmel W, Sauer P. Persistent ascites after liver transplantation: etiology, treatment and impact on survival. *Ann Transplant* 2013; **18**: 378-383 [PMID: 23881303 DOI: 10.12659/AOT.883982]
- 8 **Pereira K**, Salsamendi J, Fan J. An Approach to Diagnosis and Endovascular Treatment of Refractory Ascites in Liver Transplant: A Pictorial Essay and Clinical Practice Algorithm. *Exp Clin Transplant* 2015; **13**: 387-393 [PMID: 26450461]
- 9 **Sakamoto S**, Egawa H, Kanazawa H, Shibata T, Miyagawa-Hayashino A, Haga H, Ogura Y, Kasahara M, Tanaka K, Uemoto S. Hepatic venous outflow obstruction in pediatric living donor liver transplantation using left-sided lobe grafts: Kyoto University experience. *Liver Transpl* 2010; **16**: 1207-1214 [PMID: 20879019 DOI: 10.1002/lt.22135]
- 10 **Nishida S**, Gaynor JJ, Nakamura N, Butt F, Illanes HG, Kadono J, Neff GW, Levi DM, Moon JJ, Selvaggi G, Kato T, Ruiz P, Tzakis AG, Madariaga JR. Refractory ascites after liver transplantation: an analysis of 1058 liver transplant patients at a single center. *Am J Transplant* 2006; **6**: 140-149 [PMID: 16433768 DOI: 10.1111/j.1600-6143.2005.01161.x]

- 11 **Funaki B**, Rosenblum JD, Leef JA, Hackworth CA, Szymiski GX, Alonso EM. Angioplasty treatment of portal vein stenosis in children with segmental liver transplants: mid-term results. *AJR Am J Roentgenol* 1997; **169**: 551-554 [PMID: 9242775 DOI: 10.2214/ajr.169.2.9242775]
- 12 **Bonnell AR**, Bunchorntavakul C, Rajender Reddy K. Transjugular intrahepatic portosystemic shunts in liver transplant recipients. *Liver Transpl* 2014; **20**: 130-139 [PMID: 24142390 DOI: 10.1002/lt.23775]
- 13 **Saad WE**. Arterioportal fistulas in liver transplant recipients. *Semin Intervent Radiol* 2012; **29**: 105-110 [PMID: 23729980 DOI: 10.1055/s-0032-1312571]
- 14 **Noble-Jamieson G**, Jamieson N, Barnes ND. Ultrafiltration for intractable ascites after liver transplantation. *Arch Dis Child* 1991; **66**: 988-989 [PMID: 1929500 DOI: 10.1136/adc.66.8.988]
- 15 **Mabrut JY**, de la Roche E, Adham M, Ducerf C, Baulieux J. [Peritoneovenous diversion using the LeVeen shunt in the treatment of refractory ascites after liver transplantation]. *Ann Chir* 1998; **52**: 612-617 [PMID: 9805798]
- 16 **Gadano A**, Hadengue A, Widmann JJ, Vachierey F, Moreau R, Yang S, Soupison T, Sogni P, Degott C, Durand F. Hemodynamics after orthotopic liver transplantation: study of associated factors and long-term effects. *Hepatology* 1995; **22**: 458-465 [PMID: 7635413 DOI: 10.1002/hep.1840220214]
- 17 **Jenkins M**, Satoskar R. Ascites After Liver Transplantation. *Clin Liver Dis (Hoboken)* 2021; **17**: 317-319 [PMID: 33968396 DOI: 10.1002/cld.1050]
- 18 **Lan BY**, Landry GM, Tan VO, Bostrom A, Feng S. Ascites in hepatitis C liver transplant recipients frequently occurs in the absence of advanced fibrosis. *Am J Transplant* 2008; **8**: 366-376 [PMID: 18093276 DOI: 10.1111/j.1600-6143.2007.02046.x]
- 19 **Tripon S**, Francoz C, Albuquerque A, Paradis V, Boudjema H, Voitot H, Belghiti J, Valla D, Durand F. Interactions between virus-related factors and post-transplant ascites in patients with hepatitis C and no cirrhosis: role of cryoglobulinemia. *Transpl Int* 2015; **28**: 162-169 [PMID: 25267442 DOI: 10.1111/tri.12466]
- 20 **Blasco A**, Forns X, Carrión JA, Garcia-Pagán JC, Gilibert R, Rimola A, Miquel R, Bruguera M, García-Valdecasas JC, Bosch J, Navasa M. Hepatic venous pressure gradient identifies patients at risk of severe hepatitis C recurrence after liver transplantation. *Hepatology* 2006; **43**: 492-499 [PMID: 16496308 DOI: 10.1002/hep.21090]
- 21 **Ito T**, Kiuchi T, Yamamoto H, Oike F, Ogura Y, Fujimoto Y, Hirohashi K, Tanaka AK. Changes in portal venous pressure in the early phase after living donor liver transplantation: pathogenesis and clinical implications. *Transplantation* 2003; **75**: 1313-1317 [PMID: 12717222 DOI: 10.1097/01.TP.0000063707.90525.10]
- 22 **Wu YJ**, Wang SH, Elsarawy AM, Chan YC, Chen CL, Cheng BC, Li LC, Chiu CH, Lee YW, Lin YC, Wee SY, Pan CC, Kao YY, Chen YH, Lin HW, Lin LM, Lin CC. Prediction of the Development of Persistent Massive Ascites After Living Donor Liver Transplantation Using a Perioperative Risk Score. *Transplantation* 2018; **102**: e275-e281 [PMID: 29621060 DOI: 10.1097/TP.0000000000002174]
- 23 **Kitajima K**, Vaillant JC, Charlotte F, Eyraud D, Hannoun L. Intractable ascites without mechanical vascular obstruction after orthotopic liver transplantation: etiology and clinical outcome of sinusoidal obstruction syndrome. *Clin Transplant* 2010; **24**: 139-148 [PMID: 19222508 DOI: 10.1111/j.1399-0012.2009.00971.x]
- 24 **Hosseini M**, Aliakbarian M, Akhavan-Rezayat K, Shadkam O, Milani S. Tacrolimus-induced Ascites after Liver Transplant. *Int J Organ Transplant Med* 2018; **9**: 102-104 [PMID: 30834095]
- 25 **Torres E**, Barros P, Calmet F. Correlation between serum-ascites albumin concentration gradient and endoscopic parameters of portal hypertension. *Am J Gastroenterol* 1998; **93**: 2172-2178 [PMID: 9820392 DOI: 10.1111/j.1572-0241.1998.00615.x]
- 26 **Dittrich S**, Yordi LM, de Mattos AA. The value of serum-ascites albumin gradient for the determination of portal hypertension in the diagnosis of ascites. *HepatoGastroenterology* 2001; **48**: 166-168 [PMID: 11268957]
- 27 **Herzog D**, Martin S, Lallier M, Alvarez F. Ascites after orthotopic liver transplantation in children. *Pediatr Transplant* 2005; **9**: 74-79 [PMID: 15667616 DOI: 10.1111/j.1399-3046.2005.00259.x]
- 28 **Meighani A**, Jafri SM, Raoufi M, Salgia R. Splenic Artery Embolization for Treatment of Refractory Ascites After Liver Transplantation. *ACG Case Rep J* 2016; **3**: 136-138 [PMID: 26958571 DOI: 10.14309/crj.2016.25]
- 29 **Kubo T**, Shibata T, Itoh K, Maetani Y, Isoda H, Hiraoka M, Egawa H, Tanaka K, Togashi K. Outcome of percutaneous transhepatic venoplasty for hepatic venous outflow obstruction after living donor liver transplantation. *Radiology* 2006; **239**: 285-290 [PMID: 16567488 DOI: 10.1148/radiol.2391050387]
- 30 **King A**, Masterton G, Gunson B, Olliff S, Redhead D, Mangat K, Oniscu G, Hayes P, Tripathi D. A case-controlled study of the safety and efficacy of transjugular intrahepatic portosystemic shunts after liver transplantation. *Liver Transpl* 2011; **17**: 771-778 [PMID: 21714062 DOI: 10.1002/lt.22281]
- 31 **Saad WE**, Darwish WM, Davies MG, Kumer S, Anderson C, Waldman DL, Schmitt T, Matsumoto AH, Angle JF. Transjugular intrahepatic portosystemic shunts in liver transplant recipients: technical analysis and clinical outcome. *AJR Am J Roentgenol* 2013; **200**: 210-218 [PMID: 23255764 DOI: 10.2214/AJR.11.7653]
- 32 **Salerno F**, Cammà C, Enea M, Rössle M, Wong F. Transjugular intrahepatic portosystemic shunt for refractory ascites: a meta-analysis of individual patient data. *Gastroenterology* 2007; **133**: 825-834 [PMID: 17678653 DOI: 10.1053/j.gastro.2007.06.020]
- 33 **Guan YS**, Hu Y. Clinical application of partial splenic embolization. *ScientificWorldJournal* 2014; **2014**: 961345 [PMID: 25538966 DOI: 10.1155/2014/961345]
- 34 **Hadduck TA**, McWilliams JP. Partial splenic artery embolization in cirrhotic patients. *World J Radiol* 2014; **6**: 160-168 [PMID: 24876920 DOI: 10.4329/wjr.v6.i5.160]
- 35 **Chang CY**, Singal AK, Ganeshan SV, Schiano TD, Lookstein R, Emre S. Use of splenic artery embolization to relieve tense ascites following liver transplantation in a patient with paroxysmal nocturnal hemoglobinuria. *Liver Transpl* 2007; **13**: 1532-1537 [PMID: 17969202 DOI: 10.1002/Lt.21317]
- 36 **Kim H**, Suh KS, Jeon YM, Park MS, Choi Y, Mori S, Hong G, Lee HW, Yi NJ, Lee KW. Partial splenic artery embolization for thrombocytopenia and uncontrolled massive ascites after liver transplantation. *Transplant Proc* 2012; **44**: 755-756 [PMID: 22483487 DOI: 10.1016/j.transproceed.2012.01.066]

- 37 **Quintini C**, D'Amico G, Brown C, Aucejo F, Hashimoto K, Kelly DM, Eghtesad B, Sands M, Fung JJ, Miller CM. Splenic artery embolization for the treatment of refractory ascites after liver transplantation. *Liver Transpl* 2011; **17**: 668-673 [PMID: [21618687](#) DOI: [10.1002/lt.22280](#)]
- 38 **Presser N**, Quintini C, Tom C, Wang W, Liu Q, Diago-Usó T, Fujiki M, Winans C, Kelly D, Aucejo F, Hashimoto K, Eghtesad B, Miller C. Safety and efficacy of splenic artery embolization for portal hyperperfusion in liver transplant recipients: a 5-year experience. *Liver Transpl* 2015; **21**: 435-441 [PMID: [25604488](#) DOI: [10.1002/lt.24081](#)]
- 39 **Cheng YF**, Ou HY, Yu CY, Tsang LL, Huang TL, Chen TY, Hsu HW, Concerjero AM, Wang CC, Wang SH, Lin TS, Liu YW, Yong CC, Lin YH, Lin CC, Chiu KW, Jawan B, Eng HL, Chen CL. Interventional radiology in living donor liver transplant. *World J Gastroenterol* 2014; **20**: 6221-6225 [PMID: [24876742](#) DOI: [10.3748/wjg.v20.i20.6221](#)]
- 40 **Darcy MD**. Management of venous outflow complications after liver transplantation. *Tech Vasc Interv Radiol* 2007; **10**: 240-245 [PMID: [18086429](#) DOI: [10.1053/j.tvir.2007.09.018](#)]
- 41 **Miraglia R**, Maruzzelli L, Caruso S, Milazzo M, Marrone G, Mamone G, Carollo V, Gruttadauria S, Luca A, Gridelli B. Interventional radiology procedures in adult patients who underwent liver transplantation. *World J Gastroenterol* 2009; **15**: 684-693 [PMID: [19222091](#) DOI: [10.3748/wjg.15.684](#)]





Published by **Baishideng Publishing Group Inc**  
7041 Koll Center Parkway, Suite 160, Pleasanton, CA 94566, USA  
**Telephone:** +1-925-3991568  
**E-mail:** [bpgoffice@wjgnet.com](mailto:bpgoffice@wjgnet.com)  
**Help Desk:** <https://www.f6publishing.com/helpdesk>  
<https://www.wjgnet.com>

