

13th International Biomedical
/ CROATIAN STUDENT SUMMIT /

INNOVATIONS HEALTH

April 18-21, 2017

University of Zagreb
School of Medicine

1917–2017
100 godina Medicinskog
fakulteta Sveučilišta
u Zagrebu



13th
International Biomedical
Croatian Student Summit

CROSS13

Zagreb, April 18-21, 2017

**PROGRAMME BOOK
&
BOOK OF ABSTRACTS**

EDITOR-IN-CHIEF:

Filip Đerke

Sandro Gašpar

School of Medicine, University of Zagreb

PUBLISHER:

University of Zagreb

School of Medicine,

Šalata 3, Zagreb, CRO

FOR PUBLISHER

Marijan Klarica MD, PhD

School of Medicine, University of Zagreb

WEB:

cross.mef.hr/en



1917–2017

100 Years of School of
Medicine, University
of Zagreb

IN NOVATIONS **HEALTH**

1

**MEETING
INFORMATION**

2

**SCIENTIFIC
PROGRAMME**

3

ABSTRACTS

COMMITTEES

ORGANISED BY



1917–2017
100 Years of School of
Medicine, University
of Zagreb

UNIVERSITY OF ZAGREB
SCHOOL OF MEDICINE

STUDENT COUNCIL UNIVERSITY OF ZAGREB SCHOOL OF MEDICINE

ORGANISING COMMITTEE

Deni Rkman, *President*
Kristian Dominik Rudež, *Vice President*
Marko Stručić, *Vice President*

Marin Boban, *member*
Tihana Duić, *member*
Leo Dumbović, *member*
Filip Đerke, *member*
Luka Filipović-Grčić, *member*
Sara Fruk, *member*
Iva Hižar, *member*
Nadia Hoteit, *member*

Anton Malbašić, *member*
Drago Marijanović, *member*
Petra Marinić, *member*
Ana Mašić, *member*
Filip Njavro, *member*
Lorena Karla Rudež, *member*
Tomislav Smoljo, *member*
Kristina Stamenković, *member*

TEHNICAL SUPPORT

Romano Antunović
Zlatan Ibradžić
Goran Međimurec
Yannick Mudrovčić

SCIENTIFIC COMMITTEE

Filip Đerke, *President*

Ana Bojko, *member*
Lorena Bosnar, *member*
Igor Radanović, *member*
Paulo Zekan, *member*

Marijan Klarica, *ex-officio member*
Boris Brkljačić, *ex-officio member*
Smiljka Vikić-Topić, *ex-officio member*
Luka Grgar, *ex-officio member*

Bojan Jerbić, *ex-officio member*
Maria Brbić, *ex-officio member*
Bojan Biočina, *ex-officio member*
Ivica Lukšić, *ex-officio member*
Igor Filipčić, *ex-officio member*
Davor Ježek, *ex-officio member*
Tamara Kralj, *ex-officio member*
Lovorka Grgurević, *ex-officio member*
Željko Krznarić, *ex-officio member*

CROSS THROUGH THE YEARS

CROSS name	Year	Topic	Organising Committee
CROSS 13	2017	Innovations in Health	Filip Đerke, Deni Rkman (president), Kristian Dominik Rudež, Marko Stručić
CROSS 12	2016	Hormones and Behaviour	Filip Đerke, Sandro Gašpar (president), Ana Mašić, Filip Njavro
CROSS 11	2015	Infectious Diseases	Romano Antunović (president), Ana Mašić, Stipe Pelajić
CROSS 10	2014	Oncology	Fran Novak, Luka Opašić, Tamara Tačigin (president), Dorja Vočanec
CROSS 9	2013	Emergency Medicine	Ivan Čulina, Mario Mašić (president), Luka Opašić
CROSS 8	2012	Surgery	Vilma Dembitz, Vedran Dodig (president), Ivana Stipić
CROSS 7	2011	Sports Medicine	Vilma Dembitz, Vedran Dodig, Dora Fabijanović, Oliver Šuman (president)
CROSS 6	2010	Heart	Danko Relić, Josip Varvodić (president)
CROSS 5	2009	General topic	Matija Romić (president)
CROSS 4	2008	General topic	Ivan Vukoja (president)
CROSS 3	2007	General topic	Tomo Lucijanić, Zvonimir Misir, Božidar Perić (president), Goran Sedmak, Lana Vasung
CROSS 2	2006	General topic	Fadi Almahriq (president), Miro Bakula, Jakov Ivković, Božidar Perić, Goran Sedmak
CROSS 1	2005	General topic	Mislav Čavka (president), Tomislav Madžar

WELCOME MESSAGE FROM THE PRESIDENT OF CROSS

Dear friends and colleagues,
I want you all a warm welcome to the Croatian Student Summit 13. It is a great honor to be a part of such great student Congress. This year, we have invested a lot of time and effort to make this Congress outstanding and even more enjoyable. Our pleasure is to make our School of Medicine proud with our dedication and commitment. We are pleased and grateful to have the opportunity to provide such a meeting in our city - Zagreb. CROSS is recognized abroad and it is our duty to develop it further in that direction. As students and young scientists, we should strive for active participation in various studies and other scientific work in order to develop a way of thinking and gain the much needed experience in the earliest days of our academic life. Through the years, we try to gather the most perspective students and young scientists and present you the most interesting researches in certain areas. The idea is to connect scientific, professional and social parts in one single and complete unit. Our desire is that Croatian Student Summit becomes and continues to be a place of innovational ideas and traditional place where we can represent our scientific work. It gives me the greatest pleasure, as a president of Organizing committee, that I can contribute to CROSS with my work and new ideas.

In the 21st century, medicine and technology should work on multidisciplinary approach more than ever. We have many questions to be answered and answers to be questioned. New discoveries and the development of sci-

ence are a result of us trying to find an answer to the challenges and obstacles which medicine faces us with. The real beauty of technological advancement is that it helps us reach our full potential. It opens up an endless number of possibilities and with further studying and investing, it makes medicine even more efficient. That is why for this year's topic we chose Innovations in Health, where you will have an opportunity to see and hear some of the greatest accomplishments of modern medicine.

My thanks goes out to all members of Organizing committee, Science committee and all lecture professors who have helped make this year's Congress success. I would like to extend a special thanks to the dean of School of Medicine in Zagreb, Marijan Klarica, MD, PhD and to the whole School of Medicine, but also to the Student Council University of Zagreb for great support. We can learn from each other, together each of us can prosper and grow. Your time is precious, so invest it in a way you think that one day you will be proud and satisfied.

I am delighted to open Croatian Student Summit 13 and I wish you all a very successful Congress.



Deni Rkman,
President of the Croatian Student Summit

WELCOME MESSAGE FROM THE PRESIDENT OF SCIENTIFIC COMMITTEE OF CROSS

Dear Colleagues,

The 13th Croatian Student Summit (CROSS), taking place 18-21 April 2017 in Zagreb, Croatia, is a major meeting of the medical students in Croatia dedicated to promoting and presenting students researches. On behalf of the Scientific Committee, it is my great pleasure to welcome you to this occasion.

In CROSS 13 we focus explicitly on innovations in healthcare and medicine. There is no greater source for living longer and more prosperous lives. In the 21st century, medical innovation will dramatically improve health outcomes, reduce the cost of health care, and stimulate global economic growth, leading us to improvement of quality of life of each person. Health care is rich in evidence-based innovations, yet even when such innovations are implemented successfully in one location, they often disseminate slowly. Diffusion of innovations is a major challenge in all industries including health care. As there are so many amazing things going on in medicine and healthcare worldwide, some of the fastest growing areas are: artificial intelligence, growing organs, food development, nanorobotics inside human body, hospitals of the future, virtual environment, etc.

Through a variety of session types, including Plenary Lectures, Workshops, and other programmes, CROSS 13 will meet the needs of all participants, from 1st year medical students to the most esteemed experts.

Abstracts published in this Book of Abstracts should be representative for our medical students and science

during the last 12 months' period. Beside that, we are happy to include a lot of abstracts from foreign colleagues as well, having in mind importance of the international visibility of our CROSS.

Last year we changed the entire format and feel of the 12th CROSS, with a focus on serving attendees in new and invaluable ways. Attendees took notice, and excitement in the air was palpable. For 2017, we have further developed this vision and have added even more changes to the program. As always you can expect top education programming and the most innovative scientific research in the field, with an anticipated 90+ abstracts.

Last but not least, our Croatian Student Summit is the oldest Croatian student congress in Croatia, our Student Council has been organising it since 2005. This congress, as all other student congresses this year, will be a part of School of Medicine's centenary celebration. Therefore, I would like to express my sincere gratitude to all who actively contributed to this Congress as well to all members of the Student Council.

Value, choice, customization, and innovation. That's the new Croatian Student Summit everyone is talking about. I am looking forward to hearing what you have to say about it when we see each other in Zagreb!



Filip Đerke,
*President of the Scientific Committee of
the Croatian Student Summit*

WELCOME MESSAGE FROM THE PRESIDENT OF STUDENT COUNCIL

Dear Participants,

As a president of Student council, University of Zagreb, School of medicine, it is a great privilege to welcome you to our 13th CROatian Student Summit in Zagreb.

I am very pleased to say that CROSS has already become a traditional event, widely known in academic community, which provides young students and scientists a perfect opportunity to gain new skills and experiences necessary for their future careers. When we first started with this project in 2005, the main idea was to give students a great chance to present their scientific work and broaden their knowledge in the field of biomedicine. Also, we are very proud that, throughout these 13 years, CROSS gained international recognition with participants from all over the Europe.

It is always a great satisfaction to see so many talented and hard-working students and young scientists, here in one place, University of Zagreb, School of Medicine, gathered around one theme. Also, CROSS is an excellent place to develop important skills for our future profession and to establish many connections with our colleagues, students and professors, from all over the Europe.

I want to take this opportunity and thank the Dean of School of Medicine, University of Zagreb, Marijan Klarica, PhD, PE and Student council, University of Zagreb for their generous support. Without them,

our lecture professors and, of course, members of Organization and Scientific committee, this great story wouldn't be possible.

At the end, I would like to emphasize one thing. Although the main focus should be on gaining useful knowledge for your future professional challenges, don't forget to have fun. Zagreb is known as the city of young, so, between the scientific activities, you should use every possible chance to explore various cultural events and exciting nightlife of this beautiful city.

Thank you and best regards,



Filip Njavro,
*President, Student Council, University
of Zagreb School of Medicine*

CROSS HISTORY

The Croatian Student Summit is an annual student summit organized by the student council in collaboration with University of Zagreb School of Medicine. It is already a part of our Faculty's tradition, celebrating its thirteenth anniversary this year. It all started in the fall of 2004, when a group of enthusiasts infatuated with medicine and science decided to improve the students' standard by organizing a rather demanding project aimed at giving young scientists a chance to present their work. The Congress takes place at the University of Zagreb, School of Medicine and has received its support from the very beginning. The altruistic assistance of a number of professors and the diligent work of a group of students allowed the project to come to life. In order to achieve international level and to allow other countries from the region and the world to participate, the Congress is held in English language. From the very first CROSS, our colleagues from Hungary, Italy, Romania, Bosnia and Herzegovina, Macedonia, Poland, Bulgaria, Scotland, the USA and many other countries have recognized the big potential of the project. With every year, the number of international delegates participating at the Congress increases. We are proud of our long tradition. Throughout the years, many topics were a part of our Congress. We have provided an opportunity for students and young scientists to present their achievements and share their work with their colleagues. We have created a place for students to acquire knowledge which is not taught by the standard curriculum and which cannot be found in faculty text books. At the University of Zagreb School of Medicine, we encourage scientific research, co-operation and exchange of ideas. Each year we try to improve the Congress – make it more competitive and interesting. Our continuity, numerous awards and an increasing number of participants are the best indicator that we are on the

right track. This Congress shows that students with desire, willingness and commitment can play a significant role in the scientific world. We are proud of the names that have led CROSS all these years and that have left a mark on our School of Medicine. We are grateful for their contribution in promoting scientific student activities and events. Vision and enthusiasm led to the fact that the Croatian Student Summit has become an indispensable scientific event in Croatia, recognized in Europe and the world.

CROATIAN STUDENT SUMMIT 13

This year's topic "Innovations in Health" offers our participants a unique opportunity to get familiar with the newest achievements in medicine. Through our workshops organized by students and lectures held by some of our country's most prestigious professors, students can appreciate true value of this kind of meeting as well as gain deeper understanding of medicine's current frontiers. Beside passive participation, the participants are also welcomed to present their own research.

As every year, this year the student council tried to improve the quality of the summit by keeping the strong points from previous years as well as introducing novelties into its organization. Last year e-Posters were introduced and very welcomed by the presenters and the public and thus we have decided to continue this practice. We sincerely hope you will enjoy the biggest Croatian Student Summit yet and look forward to seeing you again next year at CROSS 14.

Marko Stručić and Kristian Dominik Rudež,
CROSS 13 Vice Presidents

SCIENTIFIC PROGRAMME OUTLINE

TUESDAY
APRIL 18, 2017

12:00 - 17:00
REGISTRATION

17:00 - 18:00
OPENING CEREMONY
PLENARY

18:00 - 20:00
NETWORKING RECEPTION

WEDNESDAY
APRIL 19, 2017

10:00 - 12:00
ZAGREB SIGHTSEEING
TOUR

10:30 - 12:00
REGISTRATION

12:00 - 13:15
POSTER SESSION 1

13:00 - 13:45
LUNCH

14:00 - 15:30
PLENARY
MULTIDISCIPLINARY

15:30 - 17:00
WORKSHOP SESSION 1

THURSDAY
APRIL 20, 2017

FRIDAY
APRIL 21, 2017

12:00 - 13:15
POSTER SESSION 2

12:00 - 13:15
POSTER SESSION 3

13:00 - 13:45
LUNCH

13:00 - 13:45
LUNCH

14:00 - 15:30
PLENARY
CLINICAL MEDICINE

14:00 - 15:30
PLENARY
BASIC MEDICAL SCIENCES

15:30 - 17:00
WORKSHOP SESSION 2

15:30 - 17:00
WORKSHOP SESSION 3

20:00 - ...
GALLA DINNER

22:00 - ...
AFTER PARTY

GENERAL INFORMATION

VENUE

University of Zagreb, School of Medicine
Šalata 3, 10000 Zagreb
Republic of Croatia

BADGES

All participants are required to wear their badges throughout the congress.

GUEST ATTENDANCE POLICY

All event activities (including workshops and meal functions) are exclusively reserved for registered attendees. Non-registered guests (including children, family members, colleagues, etc.) are not allowed in any of the event areas. Badges provided at registration are required for entrance into all functions and will be strictly enforced.

REGISTRATION DESK

Registration desk will be open as follows:

Tuesday, April 18 12:00 – 17:00

Wednesday, April 19 08:00 – 12:00

SOCIAL MEDIA

You are invited to follow CROSS13 on the social media for updates and news, to share experiences and practices, or to simply ask for opinions. Scan the QR code to join us on Facebook.

Don't forget to use the hashtag #CROSS13 to share your experience at CROSS13!



LIABILITY AND INSURANCE

The Congress Organising Committee and School of Medicine cannot accept liability for personal accidents or loss of or damage to private property of participant. Participants are advised to take out their own personal travel and health insurance for their trip.

CERTIFICATE OF ATTENDANCE

Certificate of attendance will be distributed the last day of CROSS13 (Friday, April 21).

EPOSTER ORAL PRESENTATIONS

ePoster Sessions, with ePosters specifically chosen by the Scientific Committee will be discussed during the Poster Sessions. These posters do not require printing or production of materials – as your work will be presented electronically.

ePoster presentations will take place at the ePoster stations in the Exhibition Area and each ePoster Walk Session is planned to have about 10 ePoster presentations of about 5 minutes each.

Plan your presentation accordingly and leave a minute for questions at the end of your presentation.

*All ePosters will appear on plasma stations in the Poster Area and are available for electronic viewing at all times for participants.

TEHNIICAL INFORMATION

ePOSTER VIEWING SCREENS

Electronic Posters or ePosters are similar to traditional paper posters, but displayed on-site on a large LCD television screen and are available for electronic viewing at all times for participants.

ePosters will be available at the ePoster stations at the Congress, on the CROSS 13 website during the Congress and in an online archive for one year following the Congress. Viewers will be able to easily find and browse ePosters and download the posters in PDF format when permitted by the presenter. These posters do not require printing or production of materials – as your work will be presented electronically.

All authors will be contacted for all preparation details and technical aspects of ePosters.

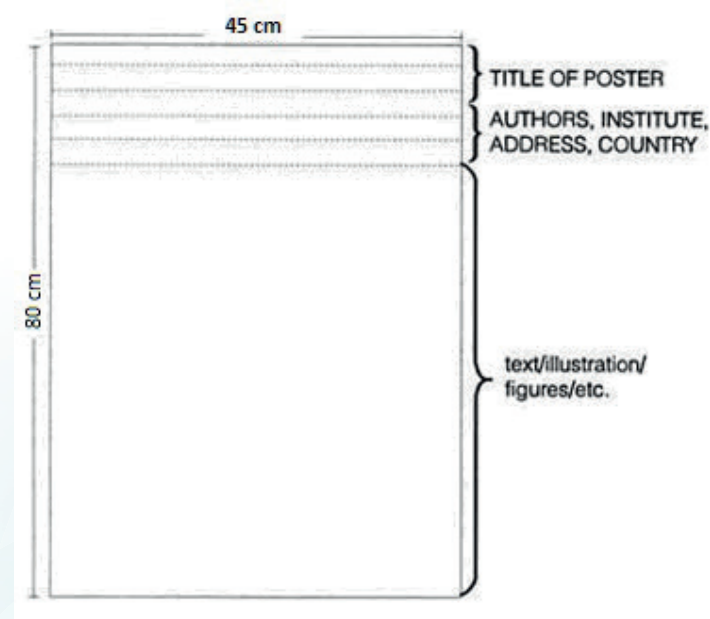
ePOSTER ORAL PRESENTATION

A variety of the abstracts have been selected for poster walk presentation during ePoster Walk Sessions. ePoster Walk sessions will take place throughout the Congress date at the ePoster Area located in the Poster Area. Each ePoster Walk Session is planned to have about 10 ePoster presentations of about 5 minutes each. Please check the CROSS 2017 online Programme for additional information regarding the posters chosen for ePoster Walk Sessions.

INSTRUCTIONS FOR THE PREPARATION OF ePOSTERS

Please submit your poster as a 1-page PDF-file in portrait orientation.

File format:	PDF
In Pixels:	1080 width x 1920 height (portrait orientation)
In Cm:	45cm width x 80cm height (portrait orientation)
Min.font size:	16



To upload your poster please follow the following steps:

1. Create your poster with one of the provided templates.
2. Export your poster as a PDF-file (File > Save as > PDF-file).
3. Click on the link in your invitation e-mail.
4. Upload your poster.

RULES FOR SUBMISSION

All abstracts and ePosters must be submitted in English.

The CROSS Science Committee will review all abstracts. Following the information regarding acceptance, scheduling information will be sent to the abstract submitter.

The Congress Abstract Book will include plenary lectures, satellite symposium abstracts, workshop abstracts and all accepted oral and poster presentations (including case-report submissions).

All abstracts must be submitted and presented in clear English with accurate grammar and spelling of quality suitable for publication. If you need help, please arrange for the review of your abstract by a colleague who is a native English speaker, by a university specific publications office (or a similar facility), or by a copy editor, prior to submission.

Abstracts must be original and must not be or have been published or presented at any other meeting prior to the Congress. Abstracts containing updated information or modified data to previously published or presented abstracts will not be considered or accepted for presentation.

Please note that each person may submit up to 3 abstracts as a presenting author.

Upon submission, the Abstract Submitter confirms that the abstract has been previewed and that all information is correct, and accepts

that the content of this abstract cannot be modified or corrected after final submission and is aware that it will be published exactly as submitted.

Submission of the abstract constitutes the authors' consent to publication (e.g. Congress Abstract Book, CROSS website, Programmes, other promotion, etc.).

The Abstract Submitter warrants and represents that he/she is the sole owner or has the rights for all the information and content ("Content") provided to CROSS 13 ("Organisers"). The publication of the abstract does not infringe any third party rights including, but not limited to, intellectual property rights.

The Abstract Submitter grants the Organisers a royalty-free, perpetual, irrevocable nonexclusive license to use, reproduce, publish, translate, distribute, and display the Content.

The Organisers reserve the right to remove from any publication an abstract which does not comply with the above.

Upon submission the Abstract Submitter confirms that the contact details saved in the system are those of the corresponding author, who will be notified about the status of the abstract. The corresponding author is responsible for informing the other authors about the status of the abstract.

NETWORKING EVENTS

NETWORKING RECEPTION

School of Medicine
in front of the Čačković hall
Tuesday, April 18, 2017
18:00 - 20:00

GALLA DINNER

School of Public Health "Andrija Štampar"
Rockfeller street 4, Zagreb
Thursday, April 20, 2017
20:00 - 22:30

AFTER PARTY

secret location
Friday, April 21, 2017
22:00 - ...

ZAGREB SIGHTSEEING TOUR

Meeting point: School of Medicine
Main entrance
Wednesday, April 19, 2017
10:00 - 12:00

13th International Biomedical
/ CROATIAN STUDENT SUMMIT /



INNOVATIONS

HEALTH

SCIENTIFIC
PROGRAMME

SCIENTIFIC PROGRAMME

- TUESDAY, APRIL 18, 2017

12:00 - 17:00

School of Medicine, Šalata 3 (*in front of Čačković Hall*)
REGISTRATION

17:00 - 18:00

School of Medicine, Šalata 3
Čačković Hall

OPENING CEREMONY

Welcome message from the Dean of School of Medicine

Welcome message from the President of CROSS 13

Welcome message from the President of Student Council School of Medicine

Welcome message from the Minister of Science and Education of the Republic of Croatia

Welcome message from the Vice President of the Croatian Medical Association

PLENARY LECTURES

M.SC. SMILJKA VIKIĆ-TOPIĆ

University of Zagreb School of Medicine, Research and Technology Transfer Office

Institutional support for Innovations

LUKA GRGAR, *student of medicine*

University of Zagreb School of Medicine

Guardiancath - intermittent hydrophilic urinary catheter combined with an antiseptic agent

18:00 - 20:00

School of Medicine, Šalata 3 (*in front of Čačković Hall*)
Networking reception

SCIENTIFIC PROGRAMME

- WEDNESDAY, APRIL 19, 2017

10:00 - 12:00

School of Medicine, Šalata 3 (*in front of Čačković Hall*)
REGISTRATION

10:00 - 12:00

School of Medicine, Šalata 3 (*in front of Main Entrance*)
Zagreb Sightseeing Tour

12:00 - 13:15

School of Medicine, Šalata 3 (*in front of Čačković Hall*)
POSTER SESSION 1

13:00 - 13:45

School of Medicine, Šalata 3 (*in front of Čačković Hall*)
LUNCH

14:00 - 15:30

School of Medicine, Šalata 3
Čačković Hall

PLENARY LECTURES

PROF. BOJAN JERBIĆ, PHD

University of Zagreb, Faculty of Mechanical Engineering and Naval Architecture

MEDICAL ROBOTICS – Reshaping Future in Synergy with Technology

MARIA BRBIĆ

Ruder Bosković Institute

The landscape of microbial phenotypic traits and associated genes

15:30 - 17:00

School of Medicine, Šalata 4
CEPAMET

WORKSHOP SESSION:

StEPP EMERGENCY MEDICINE SESSION

WORKSHOP SESSION:

ORAL HEALTH 101

15:30 - 17:00

School of Medicine, Šalata 4
CEPAMET

WORKSHOP SESSION:

STUDENT PULMONARY SECTION

SCIENTIFIC PROGRAMME

- THURSDAY, APRIL 20, 2017

12:00 - 13:15

School of Medicine, Šalata 3 (*in front of Čačković Hall*)
POSTER SESSION 2

13:00 - 13:45

School of Medicine, Šalata 3 (*in front of Čačković Hall*)
LUNCH

14:00 - 15:30

School of Medicine, Šalata 3
Čačković Hall

PLENARY LECTURES

PROF. BOJAN BIOČINA, MD, PhD

University of Zagreb School of Medicine, University Hospital Centre Zagreb, Zagreb, Croatia

Technological Advancement of Cardiac Surgery

ASS. PROF. IVICA LUKŠIĆ, MD, PhD

University of Zagreb School of Medicine, Dubrava University Hospital, Zagreb, Croatia

Technological Advancement of Maxillofacial Surgery

PROF. IGOR FILIPČIĆ, MD, PhD

University of Zagreb School of Medicine, Sveti Ivan Psychiatric Hospital, Zagreb, Croatia

Clinical application of the TMS in Psychiatry and Neurology

15:30 - 17:00

School of Medicine, Šalata 4
CEPAMET

WORKSHOP SESSION:

STUDENT CARDIOLOGY SECTION

WORKSHOP SESSION:

BPC 157 RESEARCH GROUP SESSION

15:30 - 17:00

School of Medicine, Šalata 3
NEW HALL

WORKSHOP SESSION:

STUDENT SURGICAL SECTION

SCIENTIFIC PROGRAMME

- FRIDAY, APRIL 21, 2017

12:00 - 13:15

School of Medicine, Šalata 3 (*in front of Čačković Hall*)
POSTER SESSION 3

13:00 - 13:45

School of Medicine, Šalata 3 (*in front of Čačković Hall*)
LUNCH

14:00 - 15:30

School of Medicine, Šalata 3
Čačković Hall

PLENARY LECTURES

PROF. DAVOR JEŽEK, MD, PhD

University of Zagreb, School of Medicine, Dept. Histology and Embryology; University Hospital Zagreb,

Is there a hope for infertile men with azoospermia – modern diagnostics & therapy

TAMARA KRALJ, MD, PhD CANDIDATE

University of Zagreb School of Medicine,

BPC 157 - New vistas

PROF. LOVORKA GRGUREVIĆ, MD, PhD

University of Zagreb School of Medicine, Department of Anatomy

Osteogrow - new therapy

15:30 - 17:00

School of Medicine, Šalata 4
CEPAMET

WORKSHOP SESSION:

STUDENTS' SECTION FOR THE PROMOTION OF HEALTHY NUTRITION AND LIFESTYLE

WORKSHOP SESSION:

STUDENT PEDIATRIC SECTION

15:30 - 17:00

University hospital centre Zagreb
KIŠPATIĆ STREET 12

WORKSHOP SESSION:

STUDENT SURGICAL SECTION

CASE REPORTS

C1 CALCIPHYLAXIS IN A PATIENT WITHOUT RENAL DISEASE

Ajda Anzic, Ajda Skarlovnik

C2 COMBINED DIABETES TYPE 2 AND DEPRESSION

Ajda Anzic, Vilma Urbancic Rovan

C3 MANAGEMENT OF A PATIENT WITH SUDDEN ONSET OF SEVERE HYPERTENSION

Andrej Hostnik, Barbara Salobir

C4 CARDIAC CONTRACTILITY MODULATION IN A PATIENT WITH NYHA III NON-ISCHEMIC DILATED CARDIOMYOPATHY

Andrej Hostnik, Igor Zupan

C5 DIAGNOSING CHRONIC COCAINE ABUSE BY CHEST X-RAY

Anže Jerman, Domen Plut

C6 HEMIARTHROPLASTY OF POSTTRAUMATIC SHOULDER OSTEOARTHRITIS 20 YEARS AFTER GUNSHOT INJURY – A CASE REPORT

Cene Kopač, Benjamin Marjanović

C7 IDIOPATHIC RESTRICTIVE CARDIOMYOPATHY DISCOVERED AFTER RADIOFREQUENCY ABLATION OF ATRIAL FLUTTER – A CASE REPORT

Cene Kopač, Jerneja Tasič

C8 MYOPERICARDITIS WITH COMPLICATIONS IN DIABETIC PATIENT, A CASE REPORT

Hamady Ibrahim Maiga, MD; Lana Novič, MD; Primož Dolenc, MD, BS; Jana Brguljan Hitij, MD, PhD

C9 HEMATOGENIC HIP PROSTHESIS INFECTION

Jošt Janša, Rok Šparovec

C10 CARDIOVERTER-DEFIBRILLATOR (ICD) IMPLANTATION IN A PREGNANT WOMAN WITH HYPERTROPHIC NON-OBSTRUCTIVE CARDIOMYOPATHY (HOCM) AND ANTIPHOSPHOLIPID SYNDROME

Matej Župan, Igor Župan

C11 SUCCESSFUL DELIVERY IN PATIENT WITH PAROXYSMAL NOCTURNAL HAEMOGLOBINURIA ON ECULIZUMAB THERAPY AFTER TWO MISCARRIAGES

Matej Župan, Irena Preložnik

C12 PERIPHERAL MYELIN PROTEIN 22 DISORDER AND ASPARTOACYLASE DEFICIENCY - WHAT WHEN THEY ARE RELATED

Nora Pušeljić, Ema Poznić, Silvija Pušeljić

C13 A CASE OF REPEATED VAGINAL PROLAPSE IN CAUCASIAN WOMAN

Petra Bukovec, Kristina Drusany Starič, Andrej Zore

C14 THROMBOPOIETIN RECEPTOR AGONIST ROMIPLOSTIM FOR PATIENT WITH CHRONIC ITP AND IMPROVEMENT OF QUALITY OF LIFE – A CASE REPORT

Romana Kendžel, Ana Dominiković, Dražen Pulanić

C15 SPONTANEOUS ECTOPIC PREGNANCY AFTER LEFT ADNEXECTOMY AND RIGHT TUBAL STERILISATION

Rebeka Hiršel

C16 FOURNIER'S GANGRENE AFTER THE EXTRACTION OF ACNE

Rebeka Hiršel

C17 CASE REPORT: SPLENIC RUPTURE DUE TO BLUNT ABDOMINAL TRAUMA

Rok Šparovec, Jošt Janša

C18 ACUTE ENCEPHALITIS OF UNKNOWN CAUSE IN ADULT: A CASE REPORT

Teja Možina, Manca Mlakar

C19 EARLY CORONARY ARTERY STENT THROMBOSIS: A CASE REPORT

Teja Možina, Manca Mlakar

C20 LATE SECOND TRIMESTER UTERINE RUPTURE: A CASE REPORT

Teja Možina, Manca Mlakar

C21 CASE REPORT: BERIBERI IN THE SETTING OF ACUTE PANCREATITIS

Tjaša Herič, Nadan Gregorič

C22 CARBAPENEM RESISTANT ACINETOBACTER BAUMANNII PNEUMONIA IN A PATIENT WITH DIABETIC FOOT INFECTION

Urban Kurent, Nadja Alikadic

C23 IDIOPATHIC PERICARDIAL EFFUSION

Ajda Anžić, Andreja Cerne Cercek

C24 ORAL CANCER: PRESENTATION AND TREATMENT IN BANGLADESH

Abu Talha Bin Fokhrul, Sirajum Munira

C25 A PATIENT WITH WILLIAMS – CAMPBELL SYNDROME PRESENTING WITH PNEUMOTHORAX

Iva Jurov, Sara Kavčič

C26 BALLOON VALVULOPLASTY OF CRITICAL AORTIC VALVE STENOSIS IN A NEONATE

Tea Fabijanić, MD, Asst. Prof. Daniel Dilber, MD, PhD

C27 MILLER FISHER SYNDROME AND OCULAR MYASTHENIA GRAVIS AS ASSOCIATED DISEASE

Mislav Mikuš, Luka Perčin, Davorka Vranješ, Damir Petravić, Katarina Ivana Tudor, Lucija Tomić

C28 POSTTRAUMATIC AVASCULAR NECROSIS OF KNEE IN A 40-YEAR-OLD MALE

Nik Žlak, Matej Drobnić

C29 ACUTE HYPONATREMIA DUE TO INTENTIONAL OVERCONSUMPTION OF WATER

Nevenka Batagelj, Stojan Kariž

C30 SUSPECTED PHEOCHROMOCYTOMA PRESENTING AS SEVERE RISE OF BLOOD PRESSURE AFTER BETA BLOCKER THERAPY FOR PAROXYSMAL ATRIAL FIBRILLATION

Cene Kopač, Barbara Salobir

C31 OVERUSE INJURIES IN RUNNERS: CASE SERIES AND OVERVIEW

Jure Colnarić

C32 USE OF PLATELET TRANSFUSION IN CHILDREN WITH ACUTE LEUKEMIA

Jure Colnarić

C33 END-STAGE HEART FAILURE – A CASE REPORT

Jure Colnarić

C34 MELENA CAUSED BY THE ECTOPIC PANCREATIC TISSUE IN DUODENUM

Sandro Gašpar, Iva Hižar, PhD, Robert Kliček, MD

C35 GASTROPARESIS FOLLOWING GIANT HIATAL HERNIA REPAIR

Iva Hižar, Sandro Gašpar, PhD, Robert Kliček, MD

C36 DISSECTION OF THE RIGHT CORONARY ARTERY AS A COMPLICATION OF ELECTIVE CORONARY ANGIOGRAPHY

Luka Perčin, Mislav Mikuš, Tomislav Letilović, Marta Živković

C37 VESICOINTESTINAL FISTULA AS A COMPLICATION OF DIVERTICULOSIS: CASE REPORT

Željka Drmić, Dora Dujmović

C38 IS NEUTROPHIL C64 INDEX BETTER BIOMARKER IN SEPSIS DIAGNOSTIC THAN STANDARD BIOMARKERS?

Anja Žgajaj, Mitja Košnik

C39 NEWLY DISCOVERED HYPERTENSION IN A 44-YEAR-OLD PATIENT - MALIGNANT HYPERTENSION WITH STAGE IV HYPERTENSIVE RETINOPATHY, A CASE REPORT

Lana Novič, Hamady Ibrahim Maiga, Primož Dolenc, Jana Brguljan Hitij

ePOSTER PRESENTATIONS

EP1 USAGE OF NEUROMUSCULAR ELECTRICAL STIMULATION IN THE TREATMENT OF CEREBRAL PALSY

Vignesh Chenna Kannappan

EP2 MENINGITIS IN NEUROSURGERY

Kristina Žgela, Martina Miklič Bubić, Daniela Bandić Pavlović

EP3 THE ROLE OF PAI-1 AND MTHFR GENE POLYMORPHISMS IN WOMEN WITH SPONTANEOUS MISCARRIAGES (SM)

Petra Bubalo, Iva Buterin, Silva Zupančić-Šalek

EP4 INFLAMMATORY PARAMETERS IN CLOSTRIDIUM DIFFICILE COLONIZED AND NON-COLONIZED PATIENTS WITH INFLAMMATORY BOWEL DISEASE

Špela Pintar

EP5 EXPRESSION OF KI67 IN CONGENITAL MELANOCYTIC NEVI

Anastasia Milić, Ljubica Bakić, Marko Barović, Martina Bosić

EP6 THE PRINGLE MANEUVER IN RATS. BPC 157 COUNTERACTS LIPID PEROXIDATION IN LIVER AFTER ISCHEMIC AND REPERFUSION INJURY

Dominik Malekinušić, Marko Antunović

EP7 THE EFFECT OF PENTADECAPETIDE BPC 157 ON EPISCLERAL VEIN CAUTERIZATION MODEL IN RATS

Dora Žaler, Marina Madunić, Matija Rusan

EP8 ADHESIONS AND OXIDATIVE STRESS IN PERFORATED STOMACH LESION IN RATS: PENTADECAPETIDE BPC 157, L-NAME, L-ARGININE, RANITIDINE, PANTOPRAZOLE

Ivan Krezić, Marina Madunic, Dora Zaler

EP9 PENTADECAPETIDE BPC 157 AND SPINAL CORD INJURY IN RATS

Ivan Krezić, Slaven Gojković, Mariam Samara

EP10 BLEEDING PERIOD AND PRESENTATION OF BLOOD VESSELS IN A PERFORATED STOMACH LESION IN RATS: PENTADECAPETIDE BPC 157, L-NAME, L-ARGININE, RANITIDINE, PANTOPRAZOLE

Ivan Krezić, Slaven Gojković, Mariam Samara

EP11 PANCREATIC DUCTAL ORGANOID CULTURES ARE SUITABLE MODEL TO STUDY PANCREATIC DUCTAL ION SECRETION

Laith Alsardih, Réka Molnár, József Maléth, Péter Hegy

EP12 N-ACETYL-A-NEURAMINIDASE 1 DEFICIENCY

Luka Švitek, Luka Perić, Silvija Pušeljić

EP13 EXPRESSION OF NESTIN IN CONGENITAL MELANOCYTIC NEVI

Ljubica Bakić, Anastasia Milić, Marko Barović, Martina Bosić

EP14 COUNTERACTION OF PERFORATED CAECUM LESION IN RATS: PENTADECAPETIDE BPC 157, L-NAME, L-ARGININE

Mariam Samara, Borna Vrdoljak, Dora Žaler

EP15 THE EFFECT OF COMBINED APPLICATION OF NO-SYSTEM AGENTS AND BPC157 ON BLOOD VESSELS OF PERFORATED CAECUM IN RATS

Mariam Samara, Marina Madunić, Marko Antunović

EP16 OXIDATIVE STRESS IN PERFORATED CAECUM TISSUE

Mariam Samara, Marko Antunović

EP17 LIGATED SUPERIOR MESENTERIC VEIN IN RAT AND BENEFICIAL EFFECT OF STABLE GASTRIC PENTADECAPETIDE BPC 157

Marina Madunić, Dominik Malekinušić

EP18 COUNTERACTION OF ISCHEMIC COLITIS LESION IN RATS: PENTADECAPETIDE BPC 157, L-NAME, L-ARGININE

Marko Antunović, Marina Madunić, Matija Rusan

EP19 BENEFICIAL EFFECT OF STABLE GASTRIC PENTADECAPETIDE BPC 157 ON A LIGATED SUPERIOR MESENTERIC ARTERY AND VEIN IN RATS

Matija Rusan, Marina Madunic

EP20 THE EFFECT OF THE PENTADECAPETIDE BPC 157 ADMINISTERED INTRAOPERATIVELY ON THE SCIATIC NERVE CRUSH INJURY IN A RAT MODEL

Slaven Gojković, Marko Antunović, Ivan Krezić

EP21 HOW TO COUNTERACT PERFORATED STOMACH LESION IN RATS: PENTADECAPETIDE BPC 157, L-NAME, L-ARGININE, RANITIDINE, PANTOPRAZOLE

Slaven Gojković, Mariam Samara, Ivan Krezić

EP22 CAPSULES FROM FISH

Abu Talha Bin Fokhrul, Sirajum Munira

EP23 THE SYSTEMIC SKELETAL EFFECTS OF IMMUNIZATION

Igor Radanović, Martina Fadljević

EP24 EFFECT OF SUCROSE ON ALCOHOL ABSORPTION IN RATS

Paulo Zekan, Marijana Blagaić

EP25 LUNG ULTRASOUND IN THE FOLLOW-UP OF ETIOLOGICALLY DIFFERENT COMMUNITY-ACQUIRED PNEUMONIA IN CHILDREN: A PROSPECTIVE STUDY

Anja Pintarić, Vojko Berce

EP26 POSTOPERATIVE COMPLICATIONS AFTER CONIZATION: DOES THE USE OF INTRAUTERINE DEVICES OR ORAL CONTRACEPTIVES MATTER?

Anja Pintarić, Monika Sobočan, Darja Arko, Iztok Takač

EP27 THE NEUTROPHILS/LYMPHOCYTES RATIO AS MARKER FOR EVALUATION OF DISEASE PROGRESSION OF CARDIAC PATIENTS

Yevgeniya Lukyanova

EP28 APPROACHING PATIENT DISEASE TREATMENT USING DATA OF CONSUMPTED AND DISPOSED DRUGS IN CROATIA

Ivan Bošnjak, Marija Bošnjak

EP29 ANXIETY AND INVASIVE PRENATAL TESTING

Vignesh Chenna Kannappan

EP30 THE DIFFERENCE BETWEEN TRIAL OF LABOUR AND ELECTIVE CESAREAN SECTION AMONG TWIN PREGNANCIES

Petra Bukovec, doc. dr. Miha Lučovnik, dr. med., doc. dr. Nataša Tul Mandić, dr. med.

EP31 CARDIAC MRI ASSESSMENT AFTER TOTAL SURGICAL CORRECTION OF TETRALOGY OF FALLOT OVER A 5-YEAR PERIOD

Vitomir Huljev

EP32 INTERVENTIONAL RADIOLOGY IN THE TREATMENT OF METASTATIC LIVER CANCER

Volodymyr Dunaiev, Yuriy Avdosyev

EP33 CLINICAL ASPECTS OF CHILDHOOD STROKE

Merey Kemelbekova

EP34 USE OF CAMELID ANTIBODIES FOR TREATMENT OF NEURODEGENERATIVE DISEASES - A REVIEW

Emina Horvat Velić, Božena Odošajić

EP35 AUTOMATIC PLANT WATERING SYSTEM VIA SOIL MOISTURE SENSING BY MEANS OF SUITABLE ELECTRONICS

Nermin Đuzić

EP36 ACOUSTIC LEVITATION OF THE ENGINEERING OF 3D CORTEX-LIKE CONSTRUCTIONS BY USING PRIMATE NEURAL STEM CELLS

Terezija Miškić

13th International Biomedical
/ CROATIAN STUDENT SUMMIT /



INNOVATIONS

HEALTH

ABSTRACTS

PLENARY LECTURES: OPENING CEREMONY



M.SC. SMILJKA VIKIĆ-TOPIĆ

UNIVERSITY OF ZAGREB SCHOOL OF MEDICINE
RESEARCH AND TECHNOLOGY TRANSFER OFFICE

INSTITUTIONAL SUPPORT FOR INNOVATIONS

Knowledge and technology transfer are today's buzz words and represent a third pillar and objective of modern university. Top universities perform activities that compete and collaborate: academic research and teaching, but also providing services, establishing start-up companies, licensing technologies and selling know-how.

Innovations in biomedicine depend on successful transferring of research results from laboratories to the clinical practice for helping patients. Various funding agencies require, or at least stimulate, participation of industrial partners in the research consortia in order to facilitate utilization of results and strengthen their impact on society. Pharmaceutical industry collaborates and builds strategic partnership with academic institutions in order to get access into valuable knowledge not present within companies. Universities have established technology transfer offices where professionals with multidisciplinary background support researchers in these activities.

Various institutions have different approaches towards intellectual property management strategies and utilization of research results. Presentation will focus on several approaches focusing on the US National Institutes of Health as top world institution for biomedical research and few European examples and will compare them with the situation at University of Zagreb School of Medicine. Despite the slow climate change and raising awareness of the need for involvement in the technology transfer process, there are few encouraging examples.



LUKA GRGAR AND DARIA SIMIĆ

UNIVERSITY OF ZAGREB SCHOOL OF MEDICINE

GUARDIANCATH - INTERMITTENT HYDROPHILIC URINARY CATHETER COMBINED WITH AN ANTI-SEPTIC AGENT

Clean intermittent catheterization (CIC) is widely advocated as an effective bladder management strategy for patients with incomplete bladder emptying due to idiopathic or neurogenic bladder dysfunction. Patients undergo CIC up to 10 times a day in order to treat urine retention. However, there are several complications linked to CIC, while most common ones are catheter-associated urinary tract infections (CAUTIs). Prevalence of CAUTIs ranges from 41-64% for hydrophilic catheter and 61-82% for PVC catheters per year, i.e. 6,7 – 2,1 UTIs per capita per year. In USA, CAUTIs cause more than 1 million infections per year. Expenses of treatment of CAUTIs are estimated to be over 1 billion USD per year. Safety and efficacy of hydrophilic urinary catheters has been proven scientifically, making the hydrophilic layer a “golden standard” in the manufacturing of the urinary catheters. However, this improvement didn't have the sufficient positive effect on the eradication of CAUTIs, but rather in the reduction of the mentioned complications. There are currently several antibacterial urinary catheters on the market, including nitrofurazone impregnated and gentamicine lubricated catheters. Problems with nitrofurazone catheters are bacterial resistance and growth of nonsusceptible organism at prolonged exposure to the substance. Gentamicine lubricated catheters also showed no clinical efficacy when compared to placebo. GuardianCath is an intermittent hydrophilic urinary catheter secured with an antiseptic solution in order to prevent catheter-associated urinary tract infections (CAUTIs). The main difference between GuardianCath and other antibacterial catheters is that GuardianCath is the only one that cannot induce bacterial resistance due to the unspecific activity of the antiseptic agent. The antiseptic agent is applied on the catheter surface ex tempore. It bonds chemically to the hydrophilic layer on the catheter surface and creates a mechanical barrier between bacteria and catheter surface, making catheter safe from bacteria adhesion. The invention can be combined with any other hydrophilic catheter on the market, which will enable faster spreading of the invention around the world. Ultimate goal is to eradicate catheter-associated urinary tract infections and make users safe while performing CIC.

PLENARY LECTURES: MULTIDISCIPLINARY



PROF. BOJAN JERBIĆ, PHD

UNIVERSITY OF ZAGREB
FACULTY OF MECHANICAL ENGINEERING AND NAVAL
ARCHITECTURE

MEDICAL ROBOTICS – RESHAPING FUTURE IN SYNERGY WITH TECHNOLOGY

Modern medicine relies profoundly on the application of high technology, where information technology emerges as a critical complementary area that significantly contributes to the development of medical science and medical practice. Digitalization is unavoidable direction in the evolution of modern medicine. However, we are at a turning point of the development of IT, a changing from virtual to cyber-physical. Therefore, it is necessary to adopt new approaches and new understanding of science and culture: from “data driven” to “AI things driven” concept. This means that we are entering the era of the new technological revolution, which is characterized by “smart things”, actually by the systems that convert information into action. Such systems are commonly referred to as robots. The use of robots in medicine seems like a huge potential for improving various technically and/or physically demanding medical procedures and specific skills that physicians must possess in addition to theoretical and experiential knowledge in the scope of his profession. However, the use of robots in medicine, despite numerous tangible benefits, is faced with a number of scientific and technical challenges. The presentation will highlight the main directions of the development of medical robotics, possible advantages of application, as well as problems. Special attention will be given to the Croatian project RONNA - robotic system for stereotactic neurosurgical operations, as well as its clinical application.



MARIA BRBIĆ, PHD CANDIDATE

RUDER BOŠKOVIĆ INSTITUTE
DIVISION OF ELECTRONICS. LABORATORY: LABORATORY FOR
MACHINE LEARNING AND KNOWLEDGE REPRESENTATION

THE LANDSCAPE OF MICROBIAL PHENOTYPIC TRAITS AND ASSOCIATED GENES

Bacteria and Archaea display a variety of phenotypic traits and can adapt to diverse ecological niches. However, systematic annotation of prokaryotic phenotypes is lacking. We have therefore developed ProTraits, a resource containing approx. 545 000 novel phenotype inferences, spanning 424 traits assigned to 3046 bacterial and archaeal species. These annotations were assigned by a computational pipeline that associates microbes with phenotypes by text-mining the scientific literature and the broader World Wide Web, while also being able to define novel concepts from unstructured text. Moreover, the ProTraits pipeline assigns phenotypes by drawing extensively on comparative genomics, capturing patterns in gene repertoires, codon usage biases, proteome composition and co-occurrence in metagenomes. Notably, we find that gene synteny is highly predictive of many phenotypes, and highlight examples of gene neighborhoods associated with spore-forming ability. A global analysis of trait interrelatedness outlined clusters in the microbial phenotype network, suggesting common genetic underpinnings. Our extended set of phenotype annotations allows detection of 57 088 high confidence gene-trait links, which recover many known associations involving sporulation, flagella, catalase activity, aerobicity, photosynthesis and other traits. Over 99% of the commonly occurring gene families are involved in genetic interactions conditional on at least one phenotype, suggesting that epistasis has a major role in shaping microbial gene content.

*Abstract from: Nucleic Acids Res. 2016 Dec 1; 44(21): 10074–10090.;
doi: 10.1093/nar/gkw964*

PLENARY LECTURES: CLINICAL MEDICINE



PROF. BOJAN BIOČINA, MD, PhD

UNIVERSITY OF ZAGREB SCHOOL OF MEDICINE,
UNIVERSITY HOSPITAL CENTRE ZAGREB

TECHNOLOGICAL ADVANCEMENT OF CARDIAC SURGERY

At his lecture, prof. Bojan Biočina will present the history and the technological advancement of cardiac surgery, a highly technological field which, after a period based on pioneers' ingenuity, knowledge and boldness, drains its current peaks out of highly sophisticated science and technology. Along with minimally invasive, transcatheter, nanosurgery and other high-tech breakthroughs, a special stress in this lecture will be put on presenting one of the technologically most demanding parts of cardiothoracic surgery: the mechanical circulatory support and a complexly artificial heart - an evolution from biological transplantation to this, now already almost equally successful, method of treating the most severe cases of heart disease.

Prof. Bojan Biočina (1957) specialized in cardiac surgery in Cambridge, UK. In April 2008 he was elected Head of the Department of Cardiac Surgery at the University Hospital Centre Zagreb, a duty he still holds. During his career, he participated in a number of pioneer accomplishments in cardiac surgery in Croatia, e.g. he was a part of the team which performed the first heart transplantation, the first complete arterial revascularization of the myocardium and minimally invasive surgery of the valves. In 2008 he implanted the first circulatory pump in Croatia, in 2009 he was the first to successfully transport a patient on an extracorporeal circulation support and, in 2014, was the first in the country to complete an artificial heart implant as a mechanical equivalent of heart transplantation.



ASS. PROF. IVICA LUKŠIĆ, MD, PhD

UNIVERSITY OF ZAGREB SCHOOL OF MEDICINE,
DUBRAVA UNIVERSITY HOSPITAL

TECHNOLOGICAL ADVANCEMENT OF MAXILLOFACIAL SURGERY



PROF. IGOR FILIPČIĆ, MD, PhD

UNIVERSITY OF ZAGREB SCHOOL OF MEDICINE,
SVETI IVAN PSYCHIATRIC HOSPITAL, ZAGREB

CLINICAL APPLICATION OF THE TMS IN PSYCHIATRY AND NEUROLOGY

PLENARY LECTURES: BASIC MEDICAL SCIENCES



PROF. DAVOR JEŽEK, MD, PhD

UNIVERSITY OF ZAGREB SCHOOL OF MEDICINE,
DEPT. HISTOLOGY AND EMBRYOLOGY; UNIVERSITY HOSPITAL ZAGREB, CLINICAL DEPT. OF TRANSFUSION MEDICINE AND TRANSPLANTATION BIOLOGY

IS THERE A HOPE FOR INFERTILE MEN WITH AZOOSPERMIA – MODERN DIAGNOSTICS & THERAPY

Azoospermia is the most difficult form of male infertility that affects 8-20% of infertile patients. It is divided into obstructive and non-obstructive form (OA, obstructive azoospermia, NOA, non-obstructive azoospermia). In the case of OA, the vast majority of testicular parenchyma is preserved. A significant number of seminiferous tubules have a full spermatogenesis. In contrast to OA, NOA is much more severe type of azoospermia, with extensive changes in the structure of the male sex gland and impaired spermatogenesis. However, in 60-70% of patients with NOA there are foci of spermatogenesis with a maintained production of mature spermatids and/or spermatozoa (“mixed atrophy of seminiferous tubules”). These cells can be used for ICSI (Intracytoplasmic injection of a spermatozoon into the oocyte) after the application of microsurgical procedure - open biopsy of the testis with cryopreservation. This procedure is both a diagnostic and a therapeutic procedure during which several bioptic pieces of the tissue (usually from both testicles) are taken for histological analysis and cryopreservation. Due to the cryopreservation, a mini-bank of testicular biopsies for a given patient is formed. Testicular sperm extraction (TESE) and ICSI procedure may be repeated several times, using frozen biopsy material. Thus, the patient with azoospermia, as a rule, is subjected to a single surgical procedure. A detailed histological analysis involves determining the degree of preservation of spermatogenesis and routine detection of possible carcinoma in situ using immunohistochemical methods. Using our technique of tissue handling and freezing-thawing, we were able to isolate spermatozoa in more than 60% of cases with azoospermia. It can be concluded that the biopsy of the testis with cryopreservation proved to be an effective method of treatment of patients with both OA and NOA.

TAMARA KRALJ, MD, PHD CANDIDATE

UNIVERSITY OF ZAGREB SCHOOL OF MEDICINE

BPC 157 - NEW VISTAS



PROF. LOVORKA GRGUREVIĆ, MD, PhD

UNIVERSITY OF ZAGREB SCHOOL OF MEDICINE,
DEPARTMENT OF ANATOMY

OSTEOGROW - NEW THERAPY FOR BONE REGENERATION

C1 CALCIPHYLAXIS IN A PATIENT WITHOUT RENAL DISEASE

Ajda Anzic, Ajda Skarlovnik

Institution: Clinical department of vascular diseases, University Medical Centre Ljubljana, Slovenia
Contact: ajda.anzic@gmail.com
ORCID: Ajda Anzic 0000-0002-3833-5485, Ajda Skarlovnik 0000-0002-3833-5485

Key words: calciphylaxis, no renal disease, ischemic skin lesions

Calciphylaxis is a syndrome of blood vessels calcification in fat and skin tissue which causes painful skin ulcers. It is mostly seen in patients with end stage renal disease, undergoing dialysis. Its exact pathogenesis remains unknown. Risk factors include female gender, obesity, hypercalcaemia, hyperphosphatemia, diabetes, vitamin D and calcium supplements. However, calciphylaxis can also appear in patients without kidney failure, especially patients with autoimmune diseases, taking corticosteroids and vitamin K antagonists. An 82-year old female with hypertension and rheumatoid polymyalgia, on treatment with methylprednisolone, presented with ischemic skin lesions and necrotic tissue on abdomen, buttocks, right hip and right lower extremity. Lesions were painful, tender and firm. We have performed wide spectre of laboratory tests (including creatinine, iPTH, Ca, P, Hep 2, ENA, ANCA and crioglobulins), all with normal results. Biopsy of skin lesion showed multiple arterial calcifications and thrombotic occlusions, intimal hyperplasia, fibrosis and central necrosis, confirming the diagnosis of calciphylaxis. Treatment included intensive wound care, adequate pain control, administration of sodium thiosulfate, elimination of calcium and vitamin D supplementation. Methylprednisolone, due to polymyalgia, had to be continued. The patient was not suitable for treatment in hyperbaric chamber, instead, we opted for 100% oxygen through Ohio mask 2h daily. We have presented a rare case of a patient with calciphylaxis without concurrent renal disease. The range of differential diagnoses is diverse, including atherosclerotic peripheral vascular disease, cholesterol and other emboli, antiphospholipid syndrome, cryoglobulinemia, vasculitis, protein C or S deficiency, endarteritis obliterans, coumarin necrosis or oxalate vasculopathy. Correct recognition and treatment of calciphylaxis results in marked improvement and healing of ulcers in up to 60% of patients.

C2 COMBINED DIABETES TYPE 2 AND DEPRESSION

Ajda Anzic, Vilma Urbancic Rovan

Institution: Clinical department of endocrinology and diabetes, UKC Ljubljana, Slovenia
Contact: ajda.anzic@gmail.com
ORCID: Ajda Anzic 0000-0002-3833-5485, Vilma Urbancic Rovan 0000-0002-3833-5485

Key words: diabetes type 2, depression, bi-directional relationship

Depression and diabetes are two of the most frequent health conditions in the modern world. Their relationship is thought to be bi-directional. Diabetes with psychological burden of diagnosis and substantial lifestyle changes may increase the risk of developing depression. Depression is associated with poorer health behaviour, physical inactivity, sleep disturbance, poorer metabolic control and poor diet that increase the risk of diabetes type 2. Both conditions may be also driven by shared underlying biological mechanisms as depression may activate hypothalamic-pituitary-adrenal axis, sympatho-adrenal system and pro-inflammatory cytokines which can induce insulin resistance and contribute to diabetes risk. A 76-years old female with diabetes type 2, psoriasis vulgaris, hypercholesterolemia and arterial hypertension has developed a severe depression which worsened her blood sugar control and might lead to further health complications. To control her glucose level, she was taking various per oral medication combined with insulin injections; however, her HbA1c values were always highly elevated (HbA1c 9,5 %). Because she was obese (BMI 38) and was unsuccessfully trying to lose weight, we additionally administrated GLP-1 receptor agonist as it increases insulin release, suppresses post-prandial glucagon release, delays stomach emptying and decreases appetite. Depression was treated with multiple medication and regular seasons of psychotherapy. After the combined treatment of all her health conditions she has finally reached normoglycemia and also lost 10 kg. We have presented a patient with combined diabetes type 2 and depression. These two conditions act bidirectional as the outcome of one is worsened by the other. Diabetes can cause or sustain depression, on the contrary, depression may oppose efforts to achieve or sustain normoglycemia. Therefore, only successful treatment of both conditions improves glycaemic control, general health and patient's life-quality.

C3 MANAGEMENT OF A PATIENT WITH SUD- DEN ONSET OF SEVERE HYPERTENSION

Andrej Hostnik, Barbara Salobir

Institution: University Medical Center Ljubljana, Division of Internal Medicine, Slovenia

Contact: an.hostnik@gmail.com

ORCID: Andrej Hostnik 0000-0003-0491-761X, Barbara Salobir 0000-0001-8770-5182

Key words: renovascular hypertension, secondary hypertension, multidrug antihypertensive treatment

Hypertension is one of the most common reasons for office visits. In primary hypertension (95% of cases), the cause of high blood pressure (BP) is unknown. In remaining 5%, secondary hypertension, which is due to identifiable cause, is present and when suspected, referral to hypertensive specialist is recommended. 64-year-old, previously healthy male, smoker, presented with reduced physical capacity and tiredness over the past two months. At physical examination high BP, i.e. 235/110 mmHg, and systolic murmur over the umbilical area were noteworthy. Routine laboratory tests showed slightly elevated serum creatinine (103 mmol/L) and hyperlipidaemia with increased LDL (3.9 mmol/L). Because clinical clues suggested renovascular hypertension, further investigations were performed. Doppler sonography revealed 80% ostial stenosis of the right renal artery. Renal scintigraphy showed smaller and hypofunctional right kidney with 22% relative function. Treatment was started with combination of perindopril (4 mg to 8 mg) and amlodipine (5 mg to 10 mg) once daily. Subsequently diuretic indapamide (2.5 mg), beta-blocker carvedilol (2 x 12.5 mg) and alpha-blocker doxazosin (4 mg) were added. After one week of treatment serum creatinine increased to 149 mmol/L. BP monitoring after 6 weeks with average 24-hour value of 131/62 mmHg showed good BP control. A year later, patient ceased smoking, limited salt intake, was physically active and was taking medication regularly. His physical capacity improved, BP and lipids were in target range, serum creatinine level decreased to 131 mmol/L. In presented case, significant atherosclerotic right renal artery stenosis induced renovascular hypertension and ischemic changes in affected kidney. Recent trials have not shown the superiority of renal artery angioplasty over optimal medical treatment in blood pressure control and cardiovascular events reduction. Multiple drug regimen and intense follow-up was mandatory to achieve goal BP.

C4 CARDIAC CONTRACTILITY MODULATION IN A PATIENT WITH NYHA III NON-ISCHEMIC DI- LATED CARDIOMYOPATHY

Andrej Hostnik, Igor Zupan

Institution: University Medical Center Ljubljana, Division of Internal Medicine, Slovenia

Contact: an.hostnik@gmail.com

ORCID: Andrej Hostnik 0000-0003-0491-761X, Igor Zupan 0000-0003-0491-761X

Key words: cardiac contractility modulation, heart failure, stem cell therapy

Cardiac contractility modulation (CCM) is a treatment for patients with NYHA class II-IV heart failure, based on pacemaker-like device applying non-excitatory electrical signals during the absolute refractory period, synchronized with the electrical action in the cardiac cycle. Studies have shown that it lowers the mortality rate, improves quality of life, exercise capacity, ejection fraction, NYHA class and NT-proBNP levels during long-term follow up. Our patient is a 61-year old male with NYHA class III chronic heart failure, due to non-ischemic dilated cardiomyopathy. He presented with severe dyspnea during low-intensity physical activity (walking 100 meters on flat surface or 10 stairs), without chest pain. He has accompanied hypertension, paroxysmal atrial fibrillation and COPD. The patient received stem cell therapy twice in 2014, earlier he had an ICD implanted. These measures failed to improve his clinical status significantly. The 6-minute walk test result was 445 m and echocardiography did not show improvement. Serum concentration of NT-pro BNP was 900 ng/ml. Cardiac stress test showed decreased aerobic capacity; oxygen consumption, calculated to the ideal body weight was 19 ml/min/kg. In October 2015 the patient underwent a CCM implantation. There were no complications during the procedure and the device functioned appropriately. On follow up in January 2016 patient's clinical status had improved to NYHA class II. His physical capacity increased, dyspnea appeared after walking 300 meters on flat surface or 20 stairs, NT-pro BNP level was 600 ng/L. In EKG, QRS duration had decreased to 126 ms. 6-MWT result was 545 m. In presented case CCM was implanted after conservative treatment and stem cell therapy had been exhausted. The outcome was very good, patient is now classified as NYHA II. The treatment diminished the need for potential heart transplantation in our patient and has proved to be a reasonable option in patients with severe heart failure.

C5 DIAGNOSING CHRONIC COCAINE ABUSE BY CHEST X-RAY

Anže Jerman¹, Domen Plut²

Institution: ¹Faculty of Medicine, University of Ljubljana; ²Radiology Department, University Medical Centre Ljubljana
Contact: anze.jerman@gmail.com
ORCID: Anže Jerman 0000-0003-0816-3800, Domen Plut 0000-0001-6850-1715

Key words: chest pain, pneumomediastinum, pneumothorax, cocaine, chest x-ray

INTRODUCTION: This presentation aims to illustrate the importance of good interdisciplinary work practice to reach the correct diagnosis and to correctly manage the patient. We describe a case of a young patient with recurrent sudden severe chest pain who repeatedly visited emergency department over the last two years.

CASE PRESENTATION: A 26-year-old man with an acute onset of chest pain was presented to our ED. The pain started while the patient was watching TV. Vital signs were stable, ECG showed no signs of acute cardiac ischemia, physical examination was normal. AP chest x-ray showed pneumomediastinum. Due to the lack of available clinical information from emergency physician, radiologist called ED to gain additional data. The doctor who treated the patient reported that the patient had two occurrences of spontaneous pneumothorax in the past, but no other significant information was available. The radiologist checked previous chest x-rays which confirmed pneumothorax and pneumomediastinum. When directly asked about specific risk factors, the patient denied extensive coughing or vomiting, but confirmed regular cocaine insufflation in the past five years. Pneumomediastinum caused by cocaine abuse was thus diagnosed by chest x-ray and history. This condition is self-limiting, no treatment is required. The patient was advised to attend a drug addiction rehabilitation program.

DISCUSSION: Etiopathology of pneumomediastinum is broad, however recurrent episodes of pneumomediastinum hint of a specific cause. It is important to determine the cause of pneumomediastinum, because some causes require extensive diagnostics and surgical treatment. Priority for emergency physician is to take good history, especially when patient is young and previously healthy with no clinical abnormalities, and present it well to the radiologist. Whenever treating a young patient with recurrent pneumomediastinum and no known causative factors, chronic cocaine abuse should be considered.

C6 HEMIARTHROPLASTY OF POSTTRAUMATIC SHOULDER OSTEOARTHRITIS 20 YEARS AFTER GUNSHOT INJURY – A CASE REPORT

Cene Kopač, Benjamin Marjanovič

Institution: Department of arthroscopy and sport medicine, Valdoltra Orthopaedic Hospital, Slovenia
Contact: cene.kopac@gmail.com
ORCID: Cene Kopač 0000-0001-5349-5869, Benjamin Marjanovič 0000-0002-5673-0534

Key words: hemiarthroplasty, gunshot injury, osteoarthritis

Posttraumatic shoulder osteoarthritis after gunshot injury treated with arthroplasty is extremely rare in Europe. Those type of pathology is usually presented in the battlefield-injured population and can be directly related to combat injury. Gunshot injury of bones and joints is high energy trauma and usually accompanied by multiple fractures and severe disability of affected patients. Our patient was a 44 year old male with history of left shoulder gunshot injury 20 years ago. He presented with severely limited and painful movements of affected shoulder. On clinical examination there was atrophy of deltoid muscle and deformity of clavicle. Any effort to passively or actively move the glenohumeral joint was painful. Active movements were limited to 60 degree anteflexion, 50 degree abduction and he was completely unable to perform rotational moves. Patient preoperative ASES score was 58.3 points. His preoperative shoulder radiography revealed severe shoulder joint arthrosis. Preoperative 3D CT of shoulder showed severe deformity of glenohumeral joint with joint space narrowing, deformity of clavicle, missing one third of scapula, and osteophytes surrounding n. axillaris. After preoperative diagnostics was completed, surgery was performed. We proceeded to the left shoulder through deltopectoral approach. We performed nervous axillaris release and implanted partial shoulder prosthesis. On follow up one month after surgery patient was painless with no additionally nervous axilaris damage. Range of motion improved minimally (only anteflexion improved for 20 degrees) but the ASES score improved significantly from 58.3 to 78 points. Radiography also showed good prosthesis position. With the procedure we significantly improved patients quality of life since he has now no pain, At the same time we also minimally improved the motion which additionally improved functionality of upper limb and life quality of patient.

C7 IDIOPATHIC RESTRICTIVE CARDIOMYOPATHY DISCOVERED AFTER RADIOFREQUENCY ABLATION OF ATRIAL FLUTTER – A CASE REPORT

Cene Kopač¹, Jerneja Tasič²

Institution: ¹ Department of arthroscopy and sport medicine, Val-doltra Orthopaedic Hospital, Slovenia; ² Department of Cardiology, University Medical Centre Ljubljana
Contact: cene.kopac@gmail.com
ORCID: Cene Kopač 0000-0001-5349-5869, Jerneja Tasič 0000-0002-2819-886X

Key words: idiopathic restrictive cardiomyopathy, radiofrequency ablation, atrial flutter

Introduction: Restrictive cardiomyopathy (RCM) is a disease of the myocardium, characterized by impaired ventricular filling and reduced diastolic volume in the presence of normal systolic function and normal or near normal myocardial thickness. It presents with dyspnea, orthopnea and peripheral edema. AV blocks, atrial and ventricular arrhythmias are common.

Case: A 66-year old female patient with Hashimoto thyroiditis was admitted to our hospital from the emergency department because of heart failure symptoms caused by atrial flutter (AFL) of unknown duration. During hospitalisation we excluded thyroiditis as the cause of arrhythmia. Radiofrequency ablation of AFL was performed. The procedure was uneventful, but immediately after the procedure the patient suffered pulmonary oedema. She was admitted to the intensive care unit where she was treated with iv. diuretics and noninvasive ventilation. The next day she was compensated, and haemodynamically stable. Because of the unusual course after AFL ablation further diagnostics of the heart was performed. Echocardiography revealed severely enlarged atria, which were larger than the ventricles. Diastolic function of the left ventricle was reduced. The findings were suggestive for RCM, so the biopsy of the right ventricle was performed, but did not reveal any signs for sarcoidosis, amyloidosis, or fibrosis of the endocardium. Coronary angiography showed non-obstructive coronary artery disease, the haemodynamic measurements presented restrictive pattern.

Conclusion: We concluded that patient's heart has a restrictive haemodynamic profile without a specific pathologic basis. We concluded, per exclusionem, that our patient has idiopathic restrictive cardiomyopathy (IRC). IRC has poor prognosis and there is currently no effective treatment except heart transplantation. The patient is currently stable and being treated symptomatically for heart failure, waiting for heart transplantation.

C8 MYOPERICARDITIS WITH COMPLICATIONS IN DIABETIC PATIENT, A CASE REPORT

Hamady Ibrahim Maiga, MD; Lana Novič, MD; Primož Dolenc, MD, BS; Jana Brguljan Hitij, MD, PhD

Institution: Department of Hypertension; dr. Peter Držaj Hospital; University Medical Centre Ljubljana, Slovenia
Contact: hamadymaiga@gmail.com
ORCID: Hamady Ibrahim Maiga 0000-0002-2853-6910,

Key words: pericardial effusion, myopericarditis, diabetes, ischemic heart disease

A 66-year-old woman with diabetes presenting with dyspnea, cough, fatigue, decreased exercise capacity and fever was admitted to our ward. She denied chest pain. A bilateral pleural effusion was seen on chest X-ray, and a pericardial effusion at echocardiography. Left ventricular ejection fraction was estimated at 40% with regional wall contraction abnormalities. Significant laboratory findings were elevated markers for myocardial damage (troponin I 0.6 µg/L, creatine kinase 3.1 µkat/L), elevated inflammatory markers (C-reactive protein 226 mg/L) and a severe sideropenic anemia (hemoglobin 68 g/L). Microbiological testing was positive for Rhinovirus infection. As chest pain is often masked in patients with diabetes due to neuropathy, we focused on a possible cardiac pathology. Several findings were consistent with myopericarditis, and treatment was initiated. The patient was treated for heart failure and administered i.v. iron, but displayed little improvement. Due to the lack of the symptoms for ischemic cardiac disease, CT scan of coronary arteries was performed showing triple coronary disease. We performed coronary angiography, which confirmed a diffuse coronary vessel disease requiring further intervention. Comparing results of coronary angiography with CT scan, pulmonary embolisms were detected and treatment of embolisms was required, so surgical treatment had to be postponed. The patient was presented to the intervention experts, who decided to solve the problem with renewed percutaneous intervention and stenting of the affected vessels. On follow-up, we expect to see a gradual resolution of the pericardial effusion, but not a complete restoration of the heart function, because of the combined cause of heart failure – inflammatory and ischemic. Our case report presents challenges in diagnosing myopericarditis and complications especially present in a diabetic patient with previously unknown anemia.

C9 HEMATOGENIC HIP PROSTHESIS INFECTION

Jošt Janša, Rok Šparovec

Institution: General Hospital Jesenice, Slovenia

Contact: jansajost@gmail.com

ORCID: Jošt Janša 0000-0002-1772-5177, Rok Šparovec 0000-0002-7638-4368

Key words: hematogenic arthritis, hip replacement, revision surgery

Introduction: Septic arthritis is defined as the invasion of a joint by an infectious agent. Incidence of prosthetic joint infection of hip varies from 1.99% to 2.18%. 60 to 70% of infections occur in first 2 years after surgery. Since it is a serious burden for patients and doctors, early recognition is crucial.

Case: 55-year old patient was hospitalized in the internal medicine department for treatment of urosepsis. After the improvement of symptoms she started to feel pain in her left hip, which had been replaced over ten years before. Team of orthopedic surgeons performed a revision surgery of the left hip. Due to signs of infection we decided to explantate the prosthesis and send tissue sample for microbial analysis. She was being administered cefuroxime. One week after the surgery there was a persistent redness surrounding the wound and CRP is rising. Therefore we decided to repeat revision surgery with necrectomy. After the revision we changed antibiotics to a combination of vancomycine and clindamycine. In the next four weeks she had two revision surgeries more, due to green exudates draining from the wound. Wound was healing per secundam. Four days after last revision microbiology results came back positive for *Pseudomonas aeruginosa*. She was given metronidazole with a combination of ceftolozane and tazobactam. In the next days we performed CT scan of the abdomen and femur, finding an abscess in the adductor region. There was no indication for surgical treatment of the abscess. Her condition was already getting better and parameters of inflammation were falling. After 4 months she was discharged from the hospital. After discharge she was still having VAC therapy and an open wound healing by second intention.

Discussion: This case of a prolonged hospitalization due to infection of hip prosthesis is an example of the severity of prosthesis infections. With increasing number of joint replacements in the future, we can expect more similar cases.

C10 CARDIOVERTER-DEFIBRILLATOR (ICD) IMPLANTATION IN A PREGNANT WOMAN WITH HYPERTROPHIC NON-OBSTRUCTIVE CARDIOMYOPATHY (HOCM) AND ANTIPHOSPHOLIPID SYNDROME

Matej Župan¹, Igor Župan²

Institution: ¹ University Medical centre Celje, Slovenia; ² University Medical centre Ljubljana, Department for Cardiology, Slovenia

Contact: matejzupan@hotmail.com

ORCID: Matej Župan 0000-0002-5371-7406, Igor Župan 0000-0002-6783-6852

Key words: ICD, pregnancy, HOCM

Introduction. The treatment of life-threatening arrhythmias with ICDs concerns an increasing number of women in their reproductive years, but there is a lack of information regarding ICD use in this population. When abnormal heart rhythm is detected the device will deliver an electric shock to restore a normal heartbeat. **Case.** Our patient is a 26 - year old woman, who presented herself in 2011 with chest pain, especially in connection with stress or exercise. She was 14 weeks pregnant and had known non-obstructive HCM, antiphospholipid syndrome and WPW syndrome. She had also suffered from a cerebrovascular insult and unexplained events of syncope in the past. Echocardiography revealed hypertrophy and impaired diastolic function of left and right ventricles. Due to episodes of non-sustained ventricular tachycardias on 24h ECG we considered an implantation of an ICD, which was successfully performed and later on her pregnancy passed without problems. Her child was healthy as well. On her regular annual controll in 2013 we discovered dislocation of ICD electrode. The patient explained that she felt multiple shocks couple of months before, without loss of consciousness. She noticed that her defibrillator activity could be connected with her hand position. We had to replace the ICD lead.

Conclusion. In presented case we report about the ICD implantation in a pregnant woman because of known risk factors for sudden cardiac death. The mere presence of an ICD should not defer a women from becoming pregnant unless she has an underlying structural cardiac disease that is considered as contraindication. Pregnancy does not increase the risk of major ICD-related complications or result in a high number of ICD discharges.

C11 SUCCESSFUL DELIVERY IN PATIENT WITH PAROXYSMAL NOCTURNAL HAEMOGLOBINURIA ON ECULIZUMAB THERAPY AFTER TWO MISCARRIAGES

Matej Župan¹, Irena Preložnik²

Institution: ¹University Medical centre Celje, Slovenia; ²University Medical centre Ljubljana, Department of Hematology, Slovenia
Contact: matejzupan@hotmail.com
ORCID: Matej Župan 0000-0002-5371-7406, Irena Preložnik 0000-0001-9933-549X

Key words: PNH, pregnancy, eculizumab

Introduction. Paroxysmal nocturnal haemoglobinuria (PNH) is rare, acquired clonal disorder of hematopoietic stem cells leading to intravascular haemolysis, thrombosis and cytopenias. Pregnancy in PNH is associated with significant risk of fetomaternal complications which seems to be reduced with eculizumab therapy. **Case report.** In 2000, a 17-year-old female patient was diagnosed with severe aplastic anaemia, which went into remission with immunosuppressive therapy. After 4 years, she was found to have a small PNH clone (10 %) which slowly increased to 90% till 2010. She became transfusion dependent and started with eculizumab therapy, standard protocol, in 2011. Transfusion requirements reduced but never ceased. Regularly she needed 2 packages of red blood cells (RBC) per two months. In 2014 and 2015 she started pregnancy twice with miscarriages after 9 and secondly after 20 weeks. In both pregnancies, eculizumab dose was increased to 1200mg/12-14 days, added prophylactic LMWH and RBC transfusions at haemoglobin concentration below 100g/L. At 2016, due to the high desire for a child, she became pregnant again. Together with PNH experts from Leeds, UK, we decided to increase the dose of eculizumab to 900mg/week, she refused LMWH in first trimester but started with it in second. She needed an average of 2 packages of RBS per month. In 33-weeks of pregnancy eclampsia started. Caesarean section was performed and healthy boy was delivered in August 2016. We continued the same protocol till 8 weeks after delivery and then went back to standard dose. **Conclusion.** It appears that eculizumab in combination with prophylactic anticoagulation therapy can reduce the risks of complications and fetomaternal death. However, risks of breakthrough haemolysis and preeclampsia remains. In order to reduce haemolysis and transfusion requirements during pregnancy, adjustment of the dosage and/or interval of eculizumab infusion is necessary.

C12 PERIPHERAL MYELIN PROTEIN 22 DISORDER AND ASPARTOACYLASE DEFFICIENCY - WHAT WHEN THEY ARE RELATED

Nora Pušeljić¹, Ema Poznić², Silvija Pušeljić³

Institution: ^{1,2} Faculty of Medicine in Osijek, Josip Juraj Strossmayer University of Osijek ³Division for Neuropediatrics, Genetics, Metabolic diseases and Endocrinology, Department of Pediatrics, KBC Osijek
Contact: nora.puseljic@gmail.com
ORCID: Nora Pušeljić 0000-0002-6687-7804, Ema Poznić 0000-0002-9705-4384, Silvija Pušeljić 0000-0002-9500-2185

Key words: peripheral myelin protein 22, aspartoacylase, Canavan, Charcot-Marie-Tooth

Aspartoacylase (ASPA) is an enzyme coded by ASPA gene located on chromosome 17p13.2. It's presented predominantly in oligodendrocytes where it catalyses breakdown of N-Acetyl-L-Aspartate (NAA) to L-Aspartate and Acetate. Myelin protein-22(PMP-22) is an integral membrane glycoprotein coded by gene PMP-22 located on chromosome 17p11.2. PMP-22 forms 2-5% of compact myelin of the peripheral nervous system and is primarily expressed in the Schwann cells. NAA is synthesized in neurons from aspartate and acetyl-CoA from where is transported to oligodendrocytes in which is being catabolized to aspartate and acetate by ASPA. Aspartate is utilized in protein synthesis or metabolized in the tricarboxylic acid cycle, whereas the acetate must be converted to acetyl-coenzyme A for use in fatty acid synthesis. It is proposed that one ASPA function is to provide significant portion of acetyl groups for the increased lipid synthesis that occurs during postnatal CNS myelination. NAA also acts as an organic osmolyte that removes excess water from neurons by acting as a molecular water pump. Decrease in activity of ASPA in Canavan disease leads to buildup of NAA which interferes with the formation of the myelin sheath. The newly synthesized PMP22 is retained in the endoplasmic reticulum and golgi for post-translational modification. The most of PMP22 is degraded and only a small portion is transported to the Schwann cell surface for myelination. It also has impact on Schwann cell life cycle. The duplication of chromosome 17p11.2 in Charcot-Marie-Tooth(CMT1) is increasing copies of PMP22 to over-express the protein and cause the segmental demyelination that is presented with slowed conduction velocities. Our patient has two ASPA mutations c.914C>A (p.Ala305Glu) and c.302G>T (p.Gly101Val) and also a duplication in PMP22 gene. Juvenil type of Canavan disease is very rare and is mostly manifested as a disorder of language development and motor skills.

C13 A CASE OF REPEATED VAGINAL PROLAPSE IN CAUCASIAN WOMAN

Petra Bukovec¹, Kristina Drusany Starič², Andrej Zore³

Institution: ¹Medical Faculty of Ljubljana, Slovenia; ^{2,3} Division of gynecology and Obstetrics, University medical center Ljubljana, Slovenia

Contact: 5rabukovec@gmail.com

ORCID: Petra Bukovec 0000-0003-1820-1858,

Key words: colpocleisis, pelvic organ prolapse, recurrences, sacro-colpopexy, vaginoplasty

Background: Pelvic organ prolapse is a common female health problem with negative impact on quality of life of affected women. It appears due to dysfunction of suspensory ligaments and fascial support. Even though incidence of prolapse is expected to increase over next 30 years, little is known about risk factors that promote or protect from the recurrence of prolapse. There are several treatment options for pelvic organ prolapse. First methods are nonsurgical, such as Kegel's exercises and use of pessaries. For patients with severe degree of prolapse we use different surgical techniques.

Case report: We are presenting a case of a 77-year old red-haired, Caucasian woman, who had six gynecologic surgeries due to recurrent pelvic organ prolapse. She had four vaginal childbirths without any complications. She is being treated for arterial hypertension and diabetes type 1. At the age of 50 she was first surgically treated for primary uterine prolapse. Abdominal hysterectomy with bilateral adnexectomy and Burch colposuspension was performed. Due to recurrent prolapse, she underwent vaginoplasty of enterocele and Richter's sacrospinous ligament fixation of vaginal vault in 2006, colpocleisis in 2010, vaginoplasty of enterocele and colpocleisis in 2012, laparoscopic sacrocolpopexy in 2013 and another colpocleisis in 2016. All stated surgeries took place without any complications. Two months after every surgery she had follow-up visits, where she had no specific problems. **Conclusion:** Even though there are several treatment options for pelvic organ prolapse, not all are suitable for each patient. In our case despite the fact, we tried several surgical techniques to improve our patient's condition, the proper surgical technique suitable for her could not be found. For future researches on this subject we recommend implementation of uniform definition of pelvic organ prolapse, which would help us to compare results and find appropriate treatment options for each individual.

C14 THROMBOPOIETIN RECEPTOR AGONIST ROMIPILOSTIM FOR PATIENT WITH CHRONIC ITP AND IMPROVEMENT OF QUALITY OF LIFE – A CASE REPORT

Romana Kendžel, Ana Dominiković, Dražen Pulanić

Institution: Division of Hematology, Department of Internal Medicine, University Hospital Center Zagreb, and University of Zagreb Medical School, Zagreb, Croatia

Contact:

ORCID: Romana Kendžel 0000-0001-8961-3070,

Introduction: Immune thrombocytopenia (ITP) is an autoimmune disorder characterized by accelerated platelet destruction as well as suboptimal platelet production. The resulting thrombocytopenia may be asymptomatic and incidentally detected or manifested by bleeding ranging in severity from minor petechiae and ecchymoses to life-threatening bleeding. There are various treatment options (corticosteroids, intravenous immunoglobulin (IVIg), splenectomy, other immunosuppressive agents, rituximab, and, in recent years, thrombopoietin (TPO) receptor agonists).

Objectives: The objective of this work is to present a patient with chronic ITP treated with romiplostim, a TPO-mimetic peptibody that increases platelet production by a mechanism similar to that of endogenous TPO.

Aims: The aim of this work is to describe long-term treatment of patient with chronic ITP with the new TPO-receptor agonist romiplostim, achieving stable platelet counts, without bleeding, and with improvement of patient's quality of life (QoL).

Methods: We present 25-year old male patient with long history of chronic ITP who was treated at the Division of Hematology, Department of Internal Medicine, University Hospital Center Zagreb, Zagreb, Croatia.

Results: This patient was diagnosed with ITP when he was 6 years old. Over the years, he was treated with corticosteroids, IVIg (had allergic reaction) and other immunosuppressive agents, and when he was 9 years old he had splenectomy. He was 14 years in remission, but had relaps of ITP when he was 23 years old, presenting with thrombocytopenia and bleeding diathesis. He was treated with methyl-prednisolone, initially with good response. With decrease and cesation of steroids he relapsed again with bleeding diathesis. We re-evaluated the patient and excluded other possible reasons for secondary ITP (HIV, HCV, HBV, CMV, EBV, H. pylori, bone marrow assessment, anti-platelet antibodies, immunology testing). After his third relapse in 2015 he started treatment with TPO-receptor agonist romiplostim with good response. Currently, the patient is taking romiplostim for more than 16 months, with platelet counts stable at romiplostim dose of 6 µg/kg/subcutaneously weekly, with good tolerability, without bleeding, not requiring other immunosuppressive treatment for ITP and reporting active life style and excellent QoL.

Conclusion: TPO-receptor agonists are important new therapeutic option for group of patients with chronic ITP.

C15 SPONTANEOUS ECTOPIC PREGNANCY AFTER LEFT ADNEXECTOMY AND RIGHT TUBAL STERILISATION

Rebeka Hiršel

Institution:
General hospital Izola, Slovenia; Department of Gynaecology and Obstetrics
Contact: hirselerbeka@gmail.com
ORCID: Rebeka Hiršel 0000-0003-0662-6904

Key words: tubal sterilisation, ectopic pregnancy, adnexectomy, β subunit of the human gonadotropin hormone

Introduction: Tubal sterilisation is one of the most effective methods of contraception with a low rate of failure which is estimated to 1%. Pregnancy after sterilisation is uncommon. If it fails, there is a risk of an ectopic gestation and when misdiagnosed, can lead to a life-threatening condition and also death.

Case report: This is a case of a 43 years old woman with a history of left adnexectomy and right tubal sterilisation 2 years ago, who presented to our gynaecological emergency unit with pain in the lower abdominal quadrants. The pain was intermittent, persisting for one week and it worsened at defecation or at deep breathing. She also lost consciousness several times. She had her last period about 6-7 weeks ago. We took some blood tests, including serum β subunit of the human gonadotropin hormone which was elevated 3723 IU/l, the value of Hb was low 83 g/l. The transvaginal ultrasound showed no signs of uterine pregnancy and mixed reflections in the pouch of Douglas, suspicious for blood clots. We performed an urgent diagnostic and therapeutic laparoscopic surgery where we found an ectopic right tubal pregnancy in a tube which was not connected to uterus. We removed the right fallopian tube with the ectopic pregnancy.

Conclusion: Pregnancy after sterilisation is rare but if an ectopic pregnancy develops it could lead to a life-threatening condition. It is very important to recognize an ectopic gestation and think of it even the patient undergoes tubal sterilisation. The elevated value of serum β subunit of the human gonadotropin hormone, no signs of uterine pregnancy on the ultrasound and the presence of abdominal pain poses a threat that must be taken seriously.

C16 FOURNIER'S GANGRENE AFTER THE EXTRACTION OF ACNE

Rebeka Hiršel

Institution: General hospital Izola, Slovenia; Department of Gynaecology and Obstetrics
Contact: hirselerbeka@gmail.com
ORCID: Rebeka Hiršel 0000-0003-0662-6904

Key words: necrotizing fasciitis, acne, septic shock

Introduction: Fournier's gangrene is a rare, life-threatening and very aggressive form of necrotizing fasciitis of the genitals and perineum which is caused by aerobic and anaerobic bacteria. In most cases it occurs in elderly men following trauma, insect bites, burns and infections in genital and perineal area. Women and children are less commonly affected. The predisposing factors in all age rates are immunodeficiency, diabetes mellitus and the use of corticosteroids.

Case report: We present a 48 years old woman who was admitted to our hospital because of a developing septic shock. She was febrile for 3 days, the body temperature rose up to 39 degrees, she felt weak and she also lost consciousness once. She mentioned the feeling of pain in the genital region 2 days after the extraction of acne/blister in the pubic area. We made a gynaecological examination and found an oedema of the vulva, on the left labia major we found a small area of necrotic tissue, about 1.5 cm in diameter that was sensitive on palpation. The development of a serious case of Fournier's gangrene was a consequence of the extraction of acne. We took some blood tests and realised that she was already in a septic shock. We treated her with antibiotics and we surgically removed the necrotic tissue. We had to remove the necrotic tissue three times and then after three weeks, with the help of a plastic surgeon, we closed the lesion.

Conclusion: Early diagnosis and treatment of the Fournier's gangrene that involves surgical removal of the necrotic tissue and treatment with antibiotics, is crucial. Nevertheless the mortality rate amounts over 50% and it's even higher if sepsis is already present at the time of hospital admission like it was present in our case.

C17 CASE REPORT: SPLENIC RUPTURE DUE TO BLUNT ABDOMINAL TRAUMA

Rok Šparovec, Jošt Janša

Institution: General Hospital Jesenice, Slovenia
Contact: rok.sparovec@gmail.com
ORCID: Rok Šparovec 0000-0002-7638-4368, Jošt Janša 0000-0002-1772-5177

Key words: splenic rupture, blunt abdominal trauma, abdominal ultrasound

Background: Splenic rupture is a medical emergency which can be defined as the laceration of splenic capsula. The most common cause of splenic rupture is blunt abdominal trauma, although the spleen is well protected under the ribcage. A study shows the spleen was the organ injured most frequently, almost 2/3 of the injuries occurring as an isolated intra-abdominal organ injury. The splenic injuries can be evaluated by AAST spleen injury scale which is the most widely used grading system for splenic trauma. Case: 22-year old patient admitted to the hospital due to blunt abdominal trauma after falling of his bike. 2 hours after the event he collapsed and vomited, he was conscious the whole time. Urgent chest x-ray has shown no thoracic pathology. Abdominal ultrasound followed which concluded there was a splenic rupture in the middle third of the spleen and a hematoma in size of 26 x 18 mm. Besides the spleen in the pelvis there was also about 800 – 1000 ml of free fluid, probably haemoperitoneum. He was admitted to the intensive care section where he received 320 ml of blood transfusion due to a drop in haemoglobin level, after that he was vitally stable and monitored. The next day the ultrasound was repeated and there was an intraparenchymal haematoma in size of 30 x 90 mm and a 1,5 cm thick subscapular haematoma on the superior margin of the spleen. There was no change in the amount of free abdominal fluid so it was concluded that it is clinically stable. He was discharged from the hospital after 6 days with diagnosis – ruptura lienis (middle 1/3) gradus II. Conclusion: The spleen filters estimated 10-15% of total blood volume every minute which makes splenic injuries a serious life-threatening event. The diagnostics must be precise involving abdominal ultrasound and preferably a CT scan. There may be different approaches to treatment – our case showed a nonoperative management of splenic injury.

C18 ACUTE ENCEPHALITIS OF UNKNOWN CAUSE IN ADULT: A CASE REPORT

Teja Možina¹, Manca Mlakar²

Institution: ¹ Faculty of Medicine, University of Ljubljana, Slovenia
² Community Health Center Jesenice, Slovenia
Contact: teja.mozina@gmail.com
ORCID: Teja Možina 0000-0002-3021-2106

Key words: autoimmune encephalitis, neurological deficit, acyclovir

Introduction. Encephalitis is inflammation of the brain parenchyma that results in high morbidity and mortality. The most common known etiologies are infectious and immune-mediated. Encephalitis usually presents as focal neurological deficits, behavioral changes, seizures and fever. Diagnostic measures include analysis of cerebrospinal fluid, computed tomography and magnetic resonance imaging, electroencephalography and brain biopsy. Our aim is to present the case of acute encephalitis in adult and to emphasize the importance of early recognition and treatment. Case report A 36-year-old otherwise healthy male presented with focal neurological signs, meningism, memory disorders and expressive dysphasia. Partial epileptic status was suspected and he was started on levetiracetam. Cerebrospinal fluid analysis was unremarkable and blood serum analysis revealed anemia. Magnetic resonance imaging revealed changes in temporal region consistent with encephalitis and he immediately received first dose of acyclovir because of suspected Herpes simplex virus etiology. The causative agent could not be identified despite three lumbar punctures performed. The patient was treated with acyclovir and his neurological status improved over the course of his stay in hospital. He will undergo a gastroenterological checkup because of low hemoglobin levels in order to rule out potential paraneoplastic etiology. Discussion In our case the encephalitis etiology could not be identified; however paraneoplastic etiology is still a probable cause especially in combination with anemia. Although the most common autoimmune etiologies have likely been identified additional antibodies will continue to be discovered and the pathogenic mechanisms will be better understood in the future. Despite encephalitis being associated with significant morbidity and poor outcomes, early recognition, disease-specific treatment and aggressive supportive management are of critical importance.

C19 EARLY CORONARY ARTERY STENT THROMBOSIS: A CASE REPORT

Teja Možina¹, Manca Mlakar²

Institution: ¹ Faculty of Medicine, University of Ljubljana, Slovenia

² Community Health Center Jesenice, Slovenia

Contact: teja.mozina@gmail.com

ORCID: Teja Možina 0000-0002-3021-2106

Key words: drug eluting stents, antiplatelet therapy

Introduction Drug eluting stents (DES) are used in majority of patients who undergo percutaneous coronary intervention (PCI) due to acute coronary syndrome. Stent thrombosis is an uncommon complication which results in high mortality rates due to myocardial infarction. The majority presents within the first month after PCI. Patient A 51-year-old male with a history of coronary artery disease, antihypertensive and dyslipidemia treatment, underwent a PCI and after balloon angioplasty two DES were placed in left anterior descending (LAD) coronary artery and in the diagonal branch due to acute coronary syndrome. He was started on aspirin and clopidogrel as antiplatelet therapy. Echocardiography revealed anterior cardiac wall hypokinesis, reduced left ventricular ejection fraction and left ventricular thrombus. Warfarin and temporary dalteparin were prescribed. The patient was discharged the 5th day after PCI but presented again in two days with chest pain and ST segment elevation in electrocardiogram. PCI revealed in-stent thrombosis in LAD and a stent edge dissection. Another DES was inserted in the place of dissection and he was continued on aspirin; however, clopidogrel and warfarin were replaced by ticagrelor and dalteparin. The patient's postprocedural stay in hospital was uneventful and he has been symptom-free at follow-ups. **Discussion** Stent thrombosis remains an important complication in otherwise advantageous DES usage. Careful patient selection and individually adjusted therapy are just as important as patient education about antiplatelet therapy discontinuation risk and coronary artery disease in general for improving long-term outcomes.

C20 LATE SECOND TRIMESTER UTERINE RUPTURE: A CASE REPORT

Teja Možina¹, Manca Mlakar²

Institution: ¹ Faculty of Medicine, University of Ljubljana, Slovenia

² Community Health Center Jesenice, Slovenia

Contact: teja.mozina@gmail.com

ORCID: Teja Možina 0000-0002-3021-2106, Manca Mlakar /

Key words: cesarean section, hysterectomy, uterine rupture

Introduction: Uterine rupture during pregnancy is a serious obstetric complication with significant fetal and maternal morbidity. The majority of uterine ruptures occur after a prior cesarean delivery. Uterine rupture usually presents as severe abdominal pain, altered fetal heart rate pattern, vaginal bleeding, maternal tachycardia and protrusion of the fetus or the placenta into the abdominal cavity. Prompt treatment with emergency cesarean delivery and uterine repair or hysterectomy is required. **Case report:** A 34-year-old female, gravida 2, with a history of prior cesarean delivery presented at 26 weeks gestation with sudden severe lower abdominal pain. At speculum examination there was no vaginal bleeding and the cervix was closed. Ultrasound examination revealed a present fetal heartbeat, placenta previa, suspected anterior uterine rupture with no obvious fetal or placental protrusion into the abdominal cavity and significant amount of free intraperitoneal fluid. An emergency cesarean section was performed in less than 10 minutes revealing complete uterine rupture in the place of prior cesarean scar and the neonate was delivered with Apgar scores of 2 and 4. Because of abundant intra-abdominal bleeding a hysterectomy was performed and adequate blood products were transfused. The patient's postoperative stay in hospital was uneventful. The neonate was transferred to emergency care unit in neonatal respiratory distress syndrome; however improved over the following months. **Discussion:** With an increasing number of prior cesarean deliveries uterine ruptures are becoming increasingly common worldwide. Even when the hysterectomy is not mandatory future pregnancies are discouraged because of a high uterine rupture recurrence rate. Early clinical diagnosis, appropriately equipped and trained delivery units and advanced neonatal support are essential for neonatal and maternal survival.

C21 CASE REPORT: BERIBERI IN THE SETTING OF ACUTE PANCREATITIS

Tjaša Herič¹, Nadan Gregorič²

Institution: ¹Ljubljana University Medical Centre, Slovenia; ²Department Of Endocrinology, Diabetes and Metabolic Diseases, Ljubljana University Medical Centre, Slovenia
Contact: ikrezic@mef.hr
ORCID: Tjaša Herič 0000-0002-1050-5358, Nadan Gregorič 0000-0001-5511-0934

Key words: beriberi, thiamine deficiency, lactic acidosis, gastrointestinal, malnutrition

Introduction: Beriberi is a disease caused by thiamine (vitamin B1) deficiency. Although common in poor regions of Asia where polished rice forms a major part of diet, it is usually limited to malnourished and alcohol-dependent subpopulations in developed world. Due to non-specific symptoms it can be often overlooked and difficult to recognize. The diagnosis is usually based on exclusion. There are three distinct clinical features of beriberi: neurological, cardiovascular and gastrointestinal.

Case presentation: We present 33-year old female, with a history of alcohol and heroin abuse on a methadone substitution therapy and chronic pancreatitis. The patient appeared malnourished and lethargic with difficulty of walking. She complained of diarrhoea and abdominal pain. The physical examination revealed tachycardia and tender abdomen, particularly in the epigastrium. The blood workup showed elevated levels of bilirubin and slightly elevated levels of pancreatic as well as liver enzymes. Admitted for acute exacerbation of chronic pancreatitis, the patient was initially treated with analgesia and hydration with dextrose solution. The condition further deteriorated with abdomen becoming more tender and distended. Diagnostic tests excluded ileus, perforation of gut or pancreatic necrosis. Additionally, neurologic symptoms appeared with ataxia, nistagmus as well as parasthesia and palsy of extremities, followed by confusion and cardiocirculatory collapse with hypotension, anuria and lactic acidosis. In spite of intensive fluid resuscitation efforts the condition only began to improve after treatment with high doses of thiamine was commenced with rapid resolution of all but neurological symptoms which improvement was delayed.

Discussion: The patient displayed the whole array of clinical signs and symptoms of beriberi. The neurological features were most prominent and thus helpful to determine the diagnosis. However, the non-specific gastrointestinal and cardiovascular features of beriberi posed diagnostic difficulty, particularly in the setting of acute pancreatitis where many clinical features overlap. Intensive parenteral hydration tends to worsen the condition as thiamine is water-soluble vitamin and is therefore excreted in high-volume diuresis. In our case, the patient was most likely thiamine deficient in the beginning of treatment. The rapid improvement of condition only confirmed the diagnosis.

C22 CARBAPENEM RESISTANT ACINETOBACTER BAUMANNII PNEUMONIA IN A PATIENT WITH DIABETIC FOOT INFECTION

Urban Kurent¹, Nadja Alikadic²

Institution: ¹University Medical Centre Ljubljana ²Department of Surgical Infection, University Medical Centre Ljubljana
Contact: kurent.urban@gmail.com

Key words: acinetobacter, pneumonia, diabetic foot

Introduction: Acinetobacter baumannii is increasingly recognized as one of the major pathogens implicated in hospital-acquired infections. Since its discovery Acinetobacter baumannii has developed resistance to antibiotic agents. Treatment of infections caused by Carbapenem resistant strains of Acinetobacter baumannii (CRAb) is not well established. Colistin is suggested as the main antibiotic agent against CRAb, but some studies recommend combined antibiotic therapy. Treatment of patient with infections due to CRAb is a clinical challenge often associated with higher mortality rate, especially in elderly but also in young patients.

Case presentation: 55 year old male patient with PAOD, IDC, CRF stage 5 on hemodialysis and DM type 2, was admitted because of wet gangrene on the third finger of the right foot. Amoxicillin with clavulanic acid was administered empirically and transmetatarsal amputation of affected fingers was performed. Three days later the general condition of the patient deteriorated, he started to suffer from dyspnea and low blood pressure. His SO₂ without added oxygen was 85%, RR was 80/42 mmHg and body temperature was 36.3. CXR showed right-sided pneumonia. Inflammatory markers were highly elevated. Antibiotic therapy was replaced with piperacilin/tazobactam. Because of hemodynamic instability and respiratory insufficiency the patient was transferred to Centre of Intensive Therapy, where endotracheal intubation and treatment with vasoactive support were started. The same day patient went into cardiac arrest with ventricular fibrillation. The patient was successfully reanimated and bronchoscopy was performed. It revealed massive purulent content so sample of aspirate and blood cultures were taken again. Microbiological results of respiratory and blood samples were positive for CRAb, therefore replacement of antibiotic agent was needed. Colistin and amikacin were administered carefully because of their nephrotoxicity. Despite intensive care and targeted antibiotic treatment the patient continued decompensating. At late night hours of the next day he unfortunately died of septic shock caused by CRAb pneumonia.

Discussion: This case represents unexpected, deadly complication of bacterial infection caused by CRAb in surgical patient. Infection caused by CRAb could not be predicted, as patient was not carrier of CRAb isolates. We stress the issue of early detection of bacterial infections caused by highly resistant bacterial strains.

C23 IDIOPATIC PERICARDIAL EFFUSION

Ajda Anžič, Andreja Cerne Cercek

Institution: Clinical department of cardiology, University Medical Centre Ljubljana, Slovenia
Contact: ajda.anzic@gmail.com
ORCID: Ajda Anžič 0000-0002-3833-5485, Andreja Cerne Cercek 0000-0002-3833-5485

Key words: idiopathic pericardial effusion, young female, extensive medical evaluation

Pericardial effusion is an excessive accumulation of fluid in the pericardial cavity. Its common causes are pericarditis or myocarditis (due to viral or bacterial infection), heart attack, autoimmune disease, cancer, hypothyroidism or recent medical procedure. It usually presents with chest pain, discomfort, syncope, palpitations and dyspnoea. When pericardial effusion is suspected, echocardiography should be performed. CT or MRI can help to precisely localize and quantify effusion and to point out possible pathology. A 25-years old female had an episode of severe chest pain, weakness, sickness and was suffering from shortness of breath while being physically active. Before that she was completely healthy and could easily run few kilometres. Echocardiography showed a pericardial effusion (up to 11 mm in diastole). To define its cause, various laboratory studies were performed: electrolytes, complete blood count with differential, inflammation markers, cardiac biomarkers, thyroid-stimulating hormones, rheumatoid factors (Coombs test, lupus anticoagulants, RF levels, HEP-2 test, ANA, ENA, anti-DNA, anti-beta2GPI, immunoglobulin complexes, complement levels, proteinogram) and tests of specific infectious diseases (*M. pneumoniae*, *Chlamydia pneumoniae*, HBV, HCV, HIV, tuberculosis). All tests were normal. Ultrasound of abdomen and breasts did not show any pathology. MRI showed a pericardial effusion up to 19 mm at inferior and inferolateral wall of left and right ventricle and a normal heart function, without any signs of myocarditis. A follow-up visit after six months showed a localized pericardial effusion up to 17mm. We have presented a case of a young female with moderate pericardial effusion which, despite an extensive medical evaluation, was left with a diagnosis of idiopathic pericardial effusion. Such patients need to have a regular follow up visits to evaluate size of pericardial effusion and to considered additional diagnostic and therapeutic options.

C24 ORAL CANCER: PRESENTATION AND TREATMENT IN BANGLADESH

Abu Talha Bin Fokhrul, Sirajum Munira

Institution: Sylhet MAG Osmani Medical College
Contact: dr.hasibrahman@gmail.com
ORCID: Abu Talha Bin Fokhrul 0000-0002-4886-5332, Sirajum Munira 0000-0001-8820-4080

Key words: presentation, treatment, longitudinal, successful outcome

Background and Objectives: Presentation and treatment of oral cancer is of utmost important because a good oral health enables a person to eat, speak as well as to socialize without active discomfort or embarrassment. Oral cancer, the eleventh most dominant cancer in the world, mostly affects the area of lips, tongue, mouth, salivary glands and oropharynx. So in this paper, we will discuss about the effective changes in presentation and treatment of oral cancer in Bangladesh. Materials and Methods: The research design was longitudinal and we took convenient type samples. We apparently viewed 150 patients diagnosed for oral cancer for various causes in Sylhet MAG Osmani Medical College in the period between July 2015 and June 2016. It was random sampling, the data collection was questionnaire where data collection procedure was face to face. Results: The results reported that 35% were males and 65% were females. The age groups were 11-20, 21-30, 31-40, 41-50, 51-60, 61-70, 71-80. Furthermore, oral cancer was greatly notified in 40-50 ages' people. The affected sites were floor of the mouth, hard palate, soft palate, lips, oral cavity, parotid gland, vestibule of mouth, uvula, submandibular gland, tonsil, tonsillar fossa, anterior surface of epiglottis, bronchial cleft, oropharynx. Among all sites, tongue, oral cavity and parotid gland were the greatest affected sites. Successful outcome was gained. Conclusion: For maintaining oral cancer, the greatest challenge is the lower socio-economic people of Bangladesh. It is the burning question that how we can treat the patients of oral cancer. The aim of this presentation is to convey the importance of presentation and treatment of oral cancer in Bangladesh.

C25 A PATIENT WITH WILLIAMS – CAMPBELL SYNDROME PRESENTING WITH PNEUMOTHORAX

Iva Jurov, Sara Kavčič

Institution: ¹General hospital Trbovlje, Slovenia; ²University Clinic Golnik, Slovenia

Contact: iva.jurov@gmail.com

ORCID: Iva Jurov 0000-0002-2259-6664, Sara Kavčič 0000-0001-5220-3158

Key words: Williams – Campbell syndrome, pneumothorax

In this case report a Williams-Campbell patient is presented who experienced great pain in the right side of her chest following physical exertion. A month before the incident she had an upper respiratory tract virus infection and had recently started smoking again. Pneumothorax was diagnosed and treated. Regarding her previous diagnosis special attention was given to the patient to exclude any chance of an exacerbation.

C26 BALLOON VALVULOPLASTY OF CRITICAL AORTIC VALVE STENOSIS IN A NEONATE

Tea Fabijanić, MD, Asst. Prof. Daniel Dilber, MD, PhD

Institution:

Department of Pediatric Cardiology, University Hospital Center Zagreb, Croatia

Contact: tea.fabijan@gmail.com

Key words: balloon valvuloplasty, aortic stenosis, neonate

Introduction: Bicuspid aortic valve belongs in the family of congenital heart disease and is often followed by dysplastic and/or stenotic valvar apparatus, grading the disease of the valve from mild to critical. There are two main treatment strategies, one of them cardiac catheterization and second is cardiac surgery such as surgical aortic valvuloplasty or the Ross procedure.

Report: We report a case of a male neonate with critical aortic stenosis diagnosed in a few hours after birth. Ultrasound showed congenital dysplastic bicuspid aortic valve with postenotic dilated aortic arch with consequent dilation of the right side of the heart and the pulmonary artery trunk, mild insufficiency of the tricuspid valve, and pulmonary hypertension. Patent ductus arteriosus was kept open with prostaglandin therapy. At the age of 4 days the patient underwent cardiac catheterization, a minimally invasive procedure of balloon valvuloplasty - dilation of the stenotic aortic valve. The procedure was successful without any complications. The strain on the heart was significantly lessened, which was confirmed by measuring blood pressure during catheterization and afterwards with ultrasound. Because of the dysplastic bicuspid valve there will be a lifetime need for consistent follow up and a cardiologist supervision.

Discussion: Although there are undisputable benefits of balloon valvuloplasty such as immediate positive effect on the heart, it can present with some restrictions and complications such as not being able to open the valve sufficiently or resulting in valve insufficiency. In some cases, during the child's growth the valve can become stenotic again and one of the strongest positive points is that the procedure can be done several times, thus postponing the need for an open heart surgery.

Conclusion: This case demonstrates the success of minimally invasive approach in congenital heart disease through cardiac catheterization in a neonate with critical aortic valve stenosis as a relatively new procedure bypassing open heart surgery and resulting in less trauma, reduced risk of infection and overall well-being of the patient.

C27 MILLER FISHER SYNDROME AND OCULAR MYASTHENIA GRAVIS AS ASSOCIATED DISEASE

Mislav Mikuš¹, Luka Perčin², Davorka Vranješ³, Damir Petravić⁴, Katarina Ivana Tudor⁵, Lucija Tomić⁶

Institution: ^{1,2} University Hospital Center Zagreb, Zagreb, Croatia
^{3,4,5} Department of Neurology, University Hospital Center Zagreb, Zagreb, Croatia; ⁶ School of Medicine, University of Zagreb, Zagreb, Croatia
Contact: m.mikus19@gmail.com

Key words: autoimmune disease, atypical clinical course, Miller Fisher syndrome

BACKGROUND: Miller Fisher syndrome is an autoimmune disease characterised by the clinical triad of ophthalmoplegia, ataxia, and areflexia. It affects the peripheral nervous system, and it is considered to be a variant of Guillain-Barre Syndrome.

OBJECTIVE: To present a patient with a sudden onset of diplopia and ophthalmoplegia, attenuated stretch reflexes and discrete ataxia.

CASE REPORT: A 22 year old man with unremarkable past history, presented with sudden onset of diplopia, ophthalmoplegia with inability to look left (present on both eyes), attenuated stretch reflexes and discrete ataxia following an upper respiratory illness. The patient denied having disturbances of visual acuity, eye pain, or recent trauma. Detailed clinical evaluation was performed. The result of head magnetic resonance imaging (MRI) was normal, moreover intracranial MR angiography showed no signs of aneurisms, stenosis or arteriovenous malformation (AVM). Electromyography (EMG) assessed mild axonal peripheral polyneuropathy predominately sensory that, in correlation with clinical picture, indicated Miller Fisher syndrome. Thyroid ultrasound alongside antibodies and hormones established chronic thyroiditis and hypothyreosis. Substitution therapy was initiated. After initial treatment with plasmapheresis (administered six times) didn't show significant improvement, patient was treated with intravenous immunoglobulins (IVIG). There was a gradual minimal improvement in the patient's neurological status following treatment. Results of further serological tests showed marginal values for nAChR antibodies which indicated on ocular myasthenia gravis as associated disease.

CONCLUSION: We present this case to show atypical clinical course of Miller Fisher syndrome and to emphasize connection between multiple autoimmune disease which requires detailed clinical evaluation.

C28 POSTTRAUMATIC AVASCULAR NECROSIS OF KNEE IN A 40-YEAR-OLD MALE

Nik Žlak¹, Matej Drobnič²

Institution: ¹ General hospital Trbovlje, Department of surgery, Slovenia; ² Department of Orthopaedic Surgery of the Ljubljana University Medical Centre, Slovenia
Contact: nik.zlak@gmail.com
ORCID: Nik Žlak 0000-0001-5199-9377,

Key words: avascular necrosis, posttraumatic necrosis, knee, spongioplastic, rehabilitation

This case deals with the avascular necrosis of lateral condyle and trochlea of the knee in a 40-year-old male occurring two months after initial injury. Through the case report we present the spectrum of transient bone marrow oedema syndrome, its causes and different treatment options. Treatment protocols varying widely in reversible and irreversible conditions, experience, MRI scans and good patient history lead us to the right choice. Early mobilization is key in restoring functional mobility after such injury. In this case the patient underwent a comprehensive postsurgical rehabilitation program to improve his functional ability. The result were most satisfactory and were the result of a multi-modal approach and good patient compliance.

C29 ACUTE HYPONATREMIA DUE TO INTENTIONAL OVERCONSUMPTION OF WATER

Nevenka Batagelj, Stojan Kariž

Institution: Department of internal medicine, General hospital Izola, Slovenia

Contact: nevenkabagatelj@gmail.com

Key words: acute, hyponatremia, overconsumption, water

Acute intoxication with water is a rare emergency condition. Overconsumption of water causes acute dilutional hyponatremia with consequent cerebral edema. A 42-year old woman was brought to emergency department following a seizure, presumably due to opioid withdrawal syndrome. The patient had a history of tramadol addiction for several years. The day before the seizure she decided to stop taking tramadol. Her husband noticed that she was very upset and restless, supposedly as an early manifestation of withdrawal syndrome. On admission, she was agitated, disoriented, crying, and adequate communication was not possible. Physical examination revealed large and poorly reactive pupils, a bump on the right temporal region of the head, and traces of dried blood on her lower lip. She was afebrile, normotensive, pulse 130 beats per minute. The remainder of the examination was normal. The serum level of sodium was 119 mmol/L, potassium 4.0 mmol/L, and chloride 77 mmol/L. White blood cells were $20.6 \times 10^9/L$, otherwise haemogram was normal. Liver and renal function tests were normal, as were procalcitonin and C-reactive protein. In urine, the level of sodium was 39 mmol/L, potassium 43 mmol/L, and osmolarity 234 mmol/L. Cerebrospinal fluid was normal. Computed tomography (CT) of the head showed diffuse brain edema with narrow ventricles. Chest CT scan revealed a left lower lobe consolidation. The patient was sedated, intubated, and admitted to the intensive care unit, where she underwent mechanical ventilation. She received infusion of hypertonic saline, mannitol, and amoxicillin-clavulanic acid intravenously. The serum sodium levels gradually returned to normal. After two days, we withdrew the sedation and extubated her. In a day, she began to talk and communicate adequately. She confessed that she deliberately drank six liters of water over just a few hours. Her intention was to detoxify herself, because she was ashamed to continue the opioid abuse.

C30 SUSPECTED PHEOCHROMOCYTOMA PRESENTING AS SEVERE RISE OF BLOOD PRESSURE AFTER BETA BLOCKER THERAPY FOR PAROXYSMAL ATRIAL FIBRILLATION

Cene Kopač, Barbara Salobir

Institution: Division of Hypertension, Department of Internal Medicine, University Medical Centre Ljubljana, Slovenia

Contact: cene.kopac@gmail.com

ORCID: Cene Kopač 0000-0001-5349-5869, Barbara Salobir 0000-0001-8770-5182

Key words: pheochromocytoma, paroxysmal atrial fibrillation, beta blockade

Introduction: Pheochromocytoma (PCC) is a catecholamine secreting tumor arising from chromaffin cells of the adrenal medulla. PCC may present with a wide spectrum of clinical features, including those that are not generally attributed to excess catecholamines. Case: 68-year old female, treated with β -blocker bisoprolol 2,5 mg daily due to paroxysmal atrial fibrillation, presented with a history of recurrent episodes of nausea, restlessness, tremor, headache and a severe rise of blood pressure (BP), up to 240/120 mmHg. The spells occurred daily, approximately three hours after the bisoprolol was taken, and spontaneously resolved within a few minutes. Physical examination, including BP, i.e. 131/70 mmHg, and routine laboratory tests were normal. Because presented symptoms suggested a catecholamine excess further screening was performed. Two samples of 24-hour urine test of fractionated methanephrines and catecholamines were positive; i.e. dU-Creatinine (CR) 8,0; 8,9 (normal value 7,5-18,0 mmol), dU-Adrenalin/CR 98,2; 96,2 (normal max. 3,9 nmol/mmol); dU-Noradrenalin/CR 91,7; 70,3 (normal max. 66,1 nmol/mmol); dU-Metanephrin/CR 4525; 2443 (normal max. 200 nmol/mmol), dU-Normetanephrin/CR 2170; 1035 (normal max. 400 nmol/mmol). CT scan revealed 5x4x4,6 cm large tumor of the left adrenal gland. After pre-operative stabilisation with phenoxybenzamine and bisoprolol, left adrenalectomy was performed. 24-hour urinary fractionated methanephrines and catecholamines after the surgical procedure were within normal range, the patient had no symptoms. Discussion: In presented patient with PCC, hypertensive crises were triggered by β -blockade and consequently unopposed α -receptor stimulation. To prevent hazardous BP elevation the treatment should be started with α -blocker and β -blockers should only be added after a few days of adequate α -blockade. Because recurrence may occur, long term follow-up measuring urinary or plasma metanephrines should be performed after adrenalectomy.

C31 OVERUSE INJURIES IN RUNNERS: CASE SERIES AND OVERVIEW

Jure Colnaric

Institution: Department of Traumatology, University Medical Center Ljubljana, Slovenia

Contact: jure.colnaric@gmail.com

ORCID: Jure Colnaric 0000-0003-4318-8827

Key words: stress, fracture, compartment, sports, injuries

Background: Overuse injuries have been an important part of sports medicine practice for many years. Although running is an effective way to achieve many health benefits, it is associated with a high risk of injury. Although some injuries are traumatic, most are due to overuse. The aim of this article is to review the major classes of overuse injuries of the lower extremity and their diagnosis and present clinical cases to show complications which may follow if they are not treated correctly.

case report 1: A 32-year old male personal trainer who competed regularly in marathon competitions presented to our hospital with groin pain after having completed a half marathon race. He experienced exertional groin pain in the past two weeks during training and had a medical history of ischial stress fracture. He was diagnosed with a displaced femoral neck fracture which was treated by dynamic hip screw (DHS) osteosynthesis.

Case report 2: A 30-year old male professional basketball player presented to our hospital with acute pain in the lower leg which did not regress spontaneously. The pain developed during a training and was of insidious onset. He was later diagnosed with chronic exertional compartment syndrome and underwent fasciotomy of the anterior compartment. Conclusion Most injuries due to overuse can be treated conservatively with rest and analgetics. However, some require urgent surgical treatment and if not treated correctly, can lead to grave complications. Both cases highlight the importance of early diagnosis for the success of the treatment.

C32 USE OF PLATELET TRANSFUSION IN CHILDREN WITH ACUTE LEUKEMIA

Jure Colnaric

Institution: Department of Pediatric Hematology and Oncology, University Medical Center Ljubljana, Slovenia

Contact: jure.colnaric@gmail.com

ORCID: Jure Colnaric 0000-0003-4318-8827

Key words: platelet, transfusion, threshold

Introduction Transfusion guidelines for pediatric patients with malignancy are scarce and transfusion guidelines policy commonly varies among different centers. We wanted to review the use of RBC and platelet transfusion at our pediatric department and compare our strategy to guidelines and to relevant published articles. METHODS Observation charts and electronic records for all patients with acute lymphoblastic leukemia (ALL) at our Pediatric Department of Hematology and Oncology over a 24-month period were analyzed retrospectively.

Results Mean platelet count at which platelet products were given was 15×10^9 (n=101). Patients with accompanying conditions, such as bleeding, had a lower threshold for transfusion ($13 \times 10^9/L$) and received approximately two times more platelets compared to asymptomatic patients ($21 \times 10^9/L$). However, transfusion volume in both groups was approximately equal (12 mL/kg of body weight).

Conclusions Considering the results of our study, our opinion stands for critical use of transfusion, which should be prescribed on individual basis. We believe a manner of accurate clinical observation concomitantly with laboratory values interpretation would be a useful clinical approach of transfusion supportive care for pediatric cancer patients.

C33 END-STAGE HEART FAILURE – A CASE REPORT

Jure Colnaric

Institution: Memorial Hermann Heart and Vascular Institute, University of Texas Medical School at Houston, USA

Contact: jure.colnaric@gmail.com

ORCID: Jure Colnaric 0000-0003-4318-8827

Key words: transplant, heart failure, aneurysm

Introduction: Sarcoidosis is a disease which is characterized by non-caseating granulomas affecting multiple organs, but 90% of the time it is found in the lungs and nearby lymph nodes. Cardiac sarcoidosis may be identified by asymptomatic left ventricular dysfunction, congestive heart failure, atrioventricular block, bundle branch block and complete heart block, atrial or ventricular arrhythmia and sudden death.

Case report: This patient displayed symptoms of sarcoidosis, but was diagnosed with ARVD, among other disorders, and his cardiac sarcoidosis was not discovered until after his orthotopic heart transplantation was done. His other symptoms were treated with hypertension medications, blood thinners, and heart failure medications, none of which are commonly used or intended to treat sarcoidosis, and none of which appeared to be particularly effective in treating his sarcoidosis symptoms. Eventually, the patient received an orthotopic heart transplant due to progressive heart failure, in part due to his ARVD. After the successful transplant, cardiac sarcoidosis was discovered in his explanted heart, and in follow-up appointments, no evidence of cardiac sarcoidosis was perceived.

Conclusion: The current abolition of the sarcoidosis may be in part due to the immunosuppressants he was put on after the transplant. Thus orthotopic heart transplantation may be an effective treatment of cardiac sarcoidosis.

C34 MELENA CAUSED BY THE ECTOPIC PANCREATIC TISSUE IN DUODENUM

Sandro Gašpar, Iva Hižar, PhD, Robert Kliček, MD

Institution: Department of Abdominal Surgery, Clinical Hospital Dubrava, School of Medicine University of Zagreb

Contact: sandro.gaspar.mef@gmail.com

ORCID: Sandro Gašpar 0000-0001-8941-1831, Iva Hižar 0000-0002-8300-4095, PhD, Rober Kliček, MD 0000-0001-5532-6989

Key words: ectopic pancreas, melena, chronic duodenal bleeding

Introduction: Heterotopic pancreas is defined as pancreatic tissue found outside the usual anatomical location of the pancreas. We report a rare case of duodenal chronic bleeding originating inf. heterotopic pancreatic tissue.

Case presentation: 53-year-old male with a 5 years history of gastritis presented with dyspnea and chest pain without spreading to the shoulders, neck or arms. He reported 1 black stool that morning and denied nausea, vomiting or abdominal pain. Patient underwent appendectomy in the childhood. Physical examination and laboratory tests showed no abnormalities. Esophago-gastroduodenoscopy shown egzulcerated polypoid lesion in the descending part of duodenum with no signs of active bleeding. MSCT verified hypervascular intraluminal mass with a 17 mm diameter in the descending part of the duodenum, and also showed hepatic steatosis and sigmoid diverticulosis, without inflammatory signs. The patient underwent laparotomy through an upper-mid abdominal incision. Longitudinal incision was made on the descending part of the duodenum and the tumor on the posterior wall of duodenum, 2 cm proximal to the major duodenal papilla, was removed. Removed mass was sent for histopathological analysis, which revealed that it was mature ectopic pancreatic tissue in the duodenum.

Discussion: To conclude, we have described a case of melena originating from duodenal heterotopic pancreas. The diagnosis of this condition is extremely difficult preoperatively. The data according to malignant ateration are still controversial. It is necessary to gather more information and number of cases of this entity to have more reliable data.

C35 GASTROPARESIS FOLLOWING GIANT HIAL HERNIA REPAIR

Iva Hižar, Sandro Gašpar, PhD, Robert Kliček, MD

Institution: Department of Abdominal Surgery, Clinical Hospital Dubrava, School of Medicine University of Zagreb

Contact: ihizar@mef.hr

ORCID: Iva Hižar 0000-0002-8300-4095, Sandro Gašpar 0000-0001-8941-1831, PhD, Rober Kliček, MD 0000-0001-5532-6989

Key words: hernia, gastroparesis, complications, surgery

Introduction: A giant hiatus hernia is defined as the herniation of more than 30% of the stomach through the diaphragmatic hiatus into the thorax. It is most common among the elderly and is associated with high morbidity and mortality due to life-threatening complications such as obstruction, strangulation, perforation and bleeding. **CASE presentation:** 65-year-old female was admitted to the hospital for elective surgical treatment since preoperative MSCT verified liver cysts but also revealed a giant hiatus hernia with the whole stomach until the antrum protruded into left thoracic cavity. Physical examination revealed right upper quadrant subcostal pain. Patient underwent surgical treatment in which cholecystectomy, pericystectomy and tension-free Lortat Jacob fundoplication were performed. The operation went well and patient was discharged on the postoperative day 7. A month after surgery, patient presented to the emergency department with painful distended abdomen and nausea. MSCT revealed a distended stomach, so the nasogastric tube was inserted. Chest radiography revealed left-sided pleural effusion and thoracic drainage was performed. The patient recovered and the peroral intake was established and she was discharged. However the patient returned with the same clinical asset. After one more unsuccessful conservative treatment attempt the surgical treatment was done. Through the upper midline jejunal loop below the ligament of Treitz was isolated and Braun gastroenteroanastomosis was performed. The further postoperative course went well. In patient peroral intake and the proper passage is established. Gastroscopy performed 2 months after surgery showed a healed GE anastomosis without stenosis.

Discussion: Our patient with giant hiatus hernia underwent elective surgical fundoplication, developed postoperative gastroparesis. Since the conservative treatment was unsuccessful the gastroenteroanastomosis according to Braun was done with proper result.

C36 DISSECTION OF THE RIGHT CORONARY ARTERY AS A COMPLICATION OF ELECTIVE CORONARY ANGIOGRAPHY

Luka Perčin, Mislav Mikuš, Tomislav Letilović, Marta Živković

Institution: Clinical Hospital of Merkur, Zagreb

Contact: luka.percin@yahoo.com

ORCID: Luka Perčin 0000-0003-0497-6871,

Key words: coronary angiography, dissection, teamwork, treatment

INTRODUCTION: Coronary angiography (CA) is a minimally invasive procedure and the gold standard for identifying the presence and the extent of atherosclerotic coronary artery disease (CAD). It is a common procedure that rarely causes serious problems. The estimated risk of major complications from coronary angiography is less than 1%, with mortality rate less than 0.08%. Possible complications may include bleeding, allergic reactions to contrast dye, infection, blood vessel damage, arrhythmias, blood clots and kidney damage. **CASE REPORT:** A 58-year-old female with a history of arterial hypertension, atypical chest pain and borderline results of an exercise stress test was admitted to the Department of cardiology for elective coronary angiography. CA established no significant stenosis or blockages of coronary arteries. Unfortunately, procedure was complicated with dissection of the right coronary artery (RCA) which requested implantation of 5 drug-eluting stents (DES). During the procedure, patient developed multiple ventricular fibrillations which were adequately treated. Furthermore, due to atrioventricular block and severe refractory hypotension, temporary pacemaker and intra-aortic balloon pump were inserted. Thanks to the prompt reaction and the organized cooperation from the whole medical team, patient was stabilized and further treatment was continued in the Coronary Care Unit (CCU). A transthoracic echocardiography (TTE) was used twice to assess the impairment of the cardiac function. On the control TTE, there was a significant improvement of the myocardial contractility. During the stay in CCU, patient was hemodynamically and rhythmically stable and was dismissed home with adequate therapy and recommendations. **CONCLUSION:** We present this case to emphasize that coordinated teamwork, adequate medical equipment and preparedness for the worst outcomes are of essential importance for successful treatment of major complications such as dissection of RCA.

C37 VESICOINTESTINAL FISTULA AS A COMPLICATION OF DIVERTICULOSIS: CASE REPORT

Željka Drmić, Dora Dujmović

Institution: School of Medicine University of Zagreb
Contact: zeljka.drmic@gmail.com

Key words: diverticulosis, colon, vesicointestinal fistula

INTRODUCTION: Diverticulosis of colon is a condition in which mucosa and submucosa of the intestinal wall protrude through weak spots of muscle layer of the wall, making a large number of small pouches. They can appear throughout the gastrointestinal tract, but most of them occur in sigmoid colon. Diverticula are mainly asymptomatic, but some may become inflamed or be a cause of bleeding. Although the cause of diverticulitis isn't yet fully clarified, the assumption is that inflammation occurs when something obstructs normal flow through this pouches, making an environment which promotes bacterial growth and immune response. If not treated, this can lead to rupture of the diverticula and release of intestinal bacteria into the abdominal cavity. The resultant inflammation remains localized in about 75% of patients. The remaining 25% may develop abscess, free intraperitoneal perforation, bowel obstruction, or fistulas which are defined as complicated diverticulitis. The most common fistulas involve the bladder but may also involve the small bowel, uterus, vagina, abdominal wall, or even the thigh.

CASE PRESENTATION: A 76-year-old female was admitted to Department of Gastroenterology due to constipation workup. For the last 9 months she has been complaining about irregular bowel movements accompanied by thin pencil-like stool without the presence of red blood or mucus. The patient has been complaining about dysuria, brown colored urine and recurrent urinary infections which did not improve after taking courses of antibiotics. On physical examination, mild tenderness in the left lower quadrant was detected. During digital rectal examination a firm palpable ventral mass was observed. Colonoscopy could not be performed due to obstruction caused by circular stenosis located 15 centimeters above the anal verge. Abdominal MSCT showed sigmoid stenosis, multiple diverticula in the colon and gas within the bladder. Cystoscopic examination revealed a visible fistula on the left lateral wall of the bladder.

CONCLUSION: Based on the above examinations, a diagnose of rectostenosis, vesicointestinal fistula and sigmoid diverticulosis was formed. The patient underwent an open abdominal surgery. Primary repair was performed on the fistular area of the bladder and a Hartmann procedure was performed on the colon. The patient was observed after the surgery in the ICU and released after seven days fully recovered.

C38 IS NEUTROPHIL CD64 INDEX BETTER BIOMARKER IN SEPSIS DIAGNOSTIC THAN STANDARD BIOMARKERS?

Anja Žargaj, Mitja Košnik

Institution: Medical Faculty, University of Ljubljana, Ljubljana, Slovenia; University Clinic of Respiratory and Allergic Diseases, Golnik, Slovenia
Contact: anja.zargaj@gmail.com
ORCID: Anja Žargaj 0000-0002-2856-9990

Key words: sepsis, index CD 64, intensive care

BACKGROUND: Sepsis is a life-threatening organ dysfunction that arises when a host responds insufficiently to an infection, as bacteria enter the bloodstream and reproduce therein. In recent years, SOFA scoring system has been used to identify poor organ functioning. Microbiological blood tests represent the golden standard in sepsis diagnostics. Reliable biomarkers for early detection of sepsis would greatly facilitate rapid and efficient treatment of sepsis.

AIM: The purpose of our study was to test the usability of neutrophil CD64 index comparing to standard biomarkers as C-reactive protein (CRP), procalcitonin (PCT), neutrophil granulocyte count and immature neutrophil count in sepsis diagnostics of patients with sepsis and patients with severe infection without sepsis.

METHODS: Our prospective non-interventional study included 46 patients in two groups - septic patients and patients with severe infection without sepsis and 11 healthy controls. The Leuko64™ assay was used to determine the CD64 index in blood samples from selected patients. To compare two independent samples we used an unpaired t-test or the Mann-Whitney U-test. Receiver operating characteristic (ROC) curves and the areas under the respective curve were calculated.

RESULTS: CD64 index discriminated sepsis from severe infection at value over the 7.5 (sensitivity 14.3%). None of the septic patients had the CD64 index lower than 1.2. Diagnostic accuracy of measured biomarkers for patients with sepsis compared to patients with infection without sepsis was expressed as AUC-ROC curve: CRP 0.56, PCT 0.84, CD64 index 0.78, neutrophilic granulocyte count 0.69 and immature neutrophilic count 0.91.

CONCLUSIONS: Neutrophil CD64 index expression has been proposed as an improved diagnostic test for the evaluation of sepsis, but in our study immature neutrophil count (AUC 0.91 [0.7818–1]) and PCT (AUC 0.84 [0.7024–0.9643]) had higher diagnostic values than neutrophil CD64 index (AUC 0.78 [0.6381–0.899]).

C39 NEWLY DISCOVERED HYPERTENSION IN A 44-YEAR- OLD PATIENT – MALIGNANT HYPERTENSION WITH STAGE IV HYPERTENSIVE RETINOPATHY, A CASE REPORT

Lana Novič, MD; Hamady Ibrahim Maiga, MD; Primož Dolenc, MD, BS; Jana Brguljan Hitij, MD, PhD

Institution: Department of Hypertension, University Medical Centre Ljubljana

Contact: lana.novic2@gmail.com

ORCID: Lana Novič 0000-0002-8833-8289

Key words: malignant hypertension, retinopathy, macular edema

A 44-year-old female without any previously known chronic conditions sought ophthalmological help in Celje, Slovenia, because of blurred and distorted vision in her left eye at the beginning of January 2017. They have discovered maculopathy of the left retina and a soft exudate near the macula of the left eye. They have started to treat her with non-steroidal anti-inflammatory drug solution topically, but her condition had not improved. Her chest x-ray and US Doppler of the arteries in her neck had been normal. They have started to treat her with doxycycline and rifampicin because of a borderline positive IgG antibodies titer for *Bartonella henselae*. Her vision had not improved significantly, so they referred her to The Department of Ophthalmology of the University Medical Centre in Ljubljana. The doctors in Ljubljana have discovered the patient had very high blood pressure (185-240 mmHg systolic, 105-145 mmHg diastolic) and stage IV hypertensive retinopathy. They have started a combined antihypertensive treatment but could not control her blood pressure appropriately. After consultation she has been admitted to the Department of Hypertension of the University Medical Centre Ljubljana due to the uncontrolled blood pressure. Here we have performed a series of tests to exclude secondary causes of arterial hypertension (blood and urine hormone concentrations, all within normal range – serum aldosterone level 0,52 nmol/l, plasma renin activity 0,91 µg/l/h), the ultrasound of the heart revealed hypertensive heart disease, the ultrasound of the abdomen was normal, 24-hour blood pressure monitoring revealed severe hypertension during the whole day without night-time dipping (average value during the day: 184/114 mmHg and 177/110 mmHg during the night). Combined treatment has been necessary to treat the elevated blood pressure and the patient has been discharged home with blood pressure values between 135-145/90-100 mmHg with scheduled follow-up.

EP1 USAGE OF NEUROMUSCULAR ELECTRICAL STIMULATION IN THE TREATMENT OF CEREBRAL PALSY

Vignesh Chenna Kannappan

Institution: Division of Pediatric Neurology, Department of Pediatrics, Vinnitsa National Piragov, Memorial Medical University, Ukraine

ORCID: Vignesh Chenna Kannappan 0000-0002-6082-8155

Key words: cerebral palsy, nmes, neurostimulator, stem cell therapy

Background of research: Cerebral Palsy (CP) is a broad concept which includes a group of non-progressive neurological disorders. Its genesis is the disorder of the formation of the brain in the earliest periods of its development. There are three main CP classifications by motor impairment: spastic, ataxic, and athetoid/dyskinetic. One of the basic symptom is disorders of movements i.e. inability to support a normal pose and to carry out necessary movements. (hypertonus of muscles)

Objectives of Research:

- 1) To find the effective method for improving the motor functions of the child with cerebral palsy.
- 2) To find the appropriate method of treatment for different kinds of cerebral palsy.

Method of research : A search was conducted for articles on the use of Neuromuscular electrical stimulation(NMES), Deep brain stimulation(DBS)-Neurostimulator and Transcranial stimulation to improve motor functions of children diagnosed with cerebral palsy. This yielded a total of 12 articles of which 7 articles were based on clinical trials.

Results of research:

According to the authors of the above mentioned 7 articles based on clinical trials it is clear that as a result of Neuromuscular electrical stimulation (NMES), there is improvement in the motor functions(mainly of the upper and lower extremities) of the children diagnosed with cerebral palsy. And it also demonstrates that better the improvement of motor function if the child is of less age(less than 6 years of age). It gives preliminary evidence about the usefulness of Neuromuscular electrical stimulation(NMES) as an adjunct to physical therapy program to improve the motor functions of children diagnosed with cerebral palsy(CP).

The method of treatment depends upon the type of cerebral palsy. For Spastic cerebral palsy the treatment of choice is Neuromuscular electrical stimulation(NMES) and for dyskinetic cerebral palsy the option is Deep brain stimulation(DBS) using a neurostimulator.

Conclusion: Treatment of symptoms are of immense value for the children and their family. The surgical implant of neurostimulator has brought great degree of changes in patients. There are other methods such as selective dorsal rhizotomy (SDR) – surgical method which can be effective. In the future there can be stem cell therapy (recent clinical trials shown improvement) with the application of neurostimulator.

EP2 MENINGITIS IN NEUROSURGERY

Kristina Žgela¹, Martina Miklič Public², Daniela Bandić Pavlović³

Institution: ¹ School of Medicine, University of Zagreb;

^{2,3}Department of Anesthesiology, Reanimatology and Intensive Care, University Hospital Zagreb

Contact: zgela.kristina@gmail.com

ORCID: Kristina Žgela 0000-0002-3830-0565,

Key words: meningitis, ASA, GCS, CSL, EVD

Background and aims: Bacterial and aseptic meningitis are possible postoperative complications in neurosurgical patients. The main problem is diagnosis of meningitis and differentiation between bacterial and aseptic meningitis. According to the literature, there are no clear biochemical, clinical or laboratory criteria for meningitis. The aim of the study was to assess cerebrospinal fluid (CSF) in neurosurgical patients with meningitis.

Methods: This retrospective study was performed in 25 neurosurgical patients from October 2016 until December 2016 in University Hospital Centre Zagreb. Data collected included age, sex, ASA status, antibiotic treatment, signs of systemic infection (leukocytes, CRP and glucose) and biochemical (CRP, total cell count (TCC), glucose) and microbiological analysis of CSF. Results were compared with reference range. Descriptive statistics was used for data analysis.

Results: Patients were classified as ASA II (13), ASA III (11), ASA IV (1). The median age was 55 (range, 17-75), and 68 % of patients were male. The median value of duration of surgery was 3,5 hours (range, 1- 6,5 h). CSF was collected from external ventricular drain in 13 patients and from lumbar puncture in 12 patients. CSF analysis showed positive results as follow: 13 for CRP, 20 for TCC and 15 for glucose. On the other hand, CSF microbiology analysis were positive in only three patients. Antibiotic treatment was indicated in 22/25 patients. The mean intensive care unit length of stay was 13 days, while total hospital stay was 31 days. 2/25 patients died in ICU.

Conclusion: Microbiological CSF findings can be negative despite possibility of meningitis due to initiated antibiotic treatment before sampling. The final diagnosis should be made on the clinical status, CSF and blood analysis.

EP3 THE ROLE OF PAI-1 AND MTHFR GENE POLYMORPHISMS IN WOMEN WITH SPONTANEOUS MISCARRIAGES (SM)

Petra Bubalo¹, Iva Buterin², Silva Zupančić-Šalek³

Institution: ¹University Psychiatric Hospital Vrapče, Zagreb, Croatia; ² Health Care Centre Zagreb East, Zagreb, Croatia; ³ Department of Haematology, University Hospital Centre Zagreb
Contact: petrabubalo@gmail.com
ORCID: Petra Bubalo 0000-0001-5233-0982, Iva Buterin 0000-0001-6112-9025, Silva Zupančić-Šalek 0000-0002-6244-2336

Key words: spontaneous miscarriages, PAI-1, MTHFR

Introduction Plasminogen activator inhibitor 1 (PAI-1) has a key role in a regulation of the fibrinolytic system and its 4G/5G gene polymorphism may modulate the inhibitor's synthesis. Methylenetetrahydrofolate reductase (MTHFR) is involved in the enzymatic process of creating homocysteine. In carriers of its most common mutation C677T may appear hyperhomocysteinemia, which has a role in development of venous thrombosis. These gene polymorphisms may be related to spontaneous miscarriage which is the most common pregnancy complication. **Objectives** The objective of the study was to investigate the correlation between PAI-1 and MTHFR polymorphisms and unexplained spontaneous miscarriages (SM). **Aims** The aim of this study was to determine the frequency of the PAI-1 and MTHFR polymorphisms in women with SM and in healthy controls. **Patients and methods** 150 women were investigated for PAI-1 mutation at the Department of Haematology, University Hospital Centre Zagreb. In particular, 50 women with no miscarriages and no thromboembolism related to pregnancy were taken as a control group and 100 women with the history of miscarriages as a study group. Also, combination of PAI-1 and MTHFR polymorphisms was evaluated in 142 women. Another study group included 92 women with SM in their history in comparison with 46 women in a control group, with determinate PAI-1 and MTHFR polymorphisms. For statistical analysis was used the chi-square test. **Results** The results have shown: a) correlation between SM and PAI-1 mutations ($p=0.026$); b) statistically more PAI-1 heterozygous and less PAI-1 wild type in a part of a study group, which included women with only one SM, in comparison with a control group ($p=0.047$); c) combination of both mutations, PAI-1 and MTHFR, is a risk factor for SM ($p=0.022$). **Conclusion** PAI-1 and MTHFR polymorphisms might have an important role in pregnancy because PAI-1 mutation by itself or PAI-1 mutation in a combination with MTHFR mutations may lead to SM.

EP4 INFLAMMATORY PARAMETERS IN CLOSTRIDIUM DIFFICILE COLONIZED AND NON-COLONIZED PATIENTS WITH INFLAMMATORY BOWEL DISEASE

Špela Pintar

Institution: Medical faculty, University of Maribor, Slovenia
Contact: pintar.spela@gmail.com
ORCID: Špela Pintar 0000-0003-2130-2094

Key words: clostridium difficile, inflammatory bowel disease, hospitalization, inflammatory parameters

IBD patients are often colonized with *C. difficile* but its role in these patients is inconclusive. *Clostridium difficile* is the most common cause of nosocomial infectious diarrhoea, but its prevalence in community is also increasing. Ulcerative colitis and Crohn's disease, the major types of inflammatory bowel diseases (IBD), are chronic diseases causing prolonged inflammation of digestive tract. Our aim was compare inflammatory parameters in IBD patients colonized with *C. difficile* with non-colonized IBD patients. We obtained fecal samples from IBD patients hospitalized at Department for gastroenterology. Total DNA was isolated from feces and *C. difficile* was detected by real time PCR amplification of specific 16S RNA gene segment, toxigenic strains were confirmed by amplification of *tcdB* gene. After collecting patient's basic information, inflammatory parameters (neutrophils, leukocytes, CRP, erythrocyte sedimentation, albumins, ferritin, and iron) and therapy (pre- and hospital antibiotics, corticosteroids, biological therapy) we divided isolates in IBD group, positive for *C. difficile* and IBD patients, negative for *C. difficile*. Of 48 patients, 23 (48%) were *C. difficile* positive and in 7 (30%) we also detected toxin B gene. Colonized and noncolonized patients were exposed to (pre) hospital therapy with antibiotics, corticosteroids and biological therapy in similar percentages (p -value 0,72 -1,00). There was no significant difference in inflammatory parameters between colonized and noncolonized IBD patients in any of observed inflammatory parameters (p -value for all observed parameters >0.05). Our results suggest that during the studied time period in a single hospital ward IBD patients who were colonized with *C. difficile* had similar disbalance of observed inflammatory parameters compared to noncolonized IBD patients. The presence of low number of *C. difficile* was likely not associated with the infection, but could be regarded as a marker for disturbed microbiota.

EP5 EXPRESSION OF KI67 IN CONGENITAL MELANOCYTIC NEVI

Anastasia Milić, Ljubica Bakić, Marko Barović, Martina Bosić

Institution: Institute of Pathology, Faculty of Medicine, University of Belgrade

Contact: anastasiadragica@gmail.com

ORCID: Anastasia Milić 0000-0003-2549-7175, Ljubica Bakić 0000-0002-7872-5402, Marko Barović 0000-0002-0839-6009, Martina Bosić 0000-0001-7113-2834

Key words: CMN, proliferation, gender, age, localization

Introduction: Congenital melanocytic nevi (CMN) are present in about 1% of newborns. Ki67 is a proliferation marker that is mostly used to show proliferating cell populations. **Aim:** Examination of Ki67 expression, its distribution within nevus and relation of expression to clinical parameters (gender, age, size and localization). **Materials and Methods:** Tissue microarray was made from superficial, middle and deep parts of 119 CMN. Ki67 expression was seen in less than 5% of cells, thus every case with expression was considered positive.

Results: 48.7% of CMN had positive expression. The most frequent Ki67 expression was found in the superficial parts of nevi (26.2%). In general, there was no difference in Ki67 expression between parts of the nevi ($p=0.187$). In males positive expression in the middle parts of nevi was more common (34.3%) compared to females (11.8%) ($p=0.05$). Frequency of overall Ki67 expression decreased with age of patients ($p=0.008$). Similar observation was made in the deep parts of nevi ($p=0.017$). 53.7% of nevi located on the trunk had positive expression, compared to 7.7% of nevi located on upper extremities ($p=0.023$). Trunk was also most common localization for the nevi with positive expression in the superficial parts ($p=0.047$). Ki67 expression was not associated with size of the nevus.

Conclusion: Ki67 expression is common in CMN. It is associated with gender and age of patients and localization of nevi.

EP6 THE PRINGLE MANEUVER IN RATS. BPC 157 COUNTERACTS LIPID PEROXIDATION IN LIVER AFTER ISCHEMIC AND REPERFUSION INJURY

Dominik Malekinusic, Marko Antunovic

Institution: Department of Pharmacology; School of Medicine University of Zagreb

Contact: dmalekinusic@student.mef.hr

ORCID: Dominik Malekinušić 0000-0001-6258-5647, Marko Antunović 0000-0002-3801-5481

Key words: Pringle maneuver, rats, TBARS, BPC 157

The Pringle maneuver, despite the risk of inducing hepatic failure, remains the most commonly used technique to control blood loss during hepatectomy. Previously, stable gastric pentadecapeptide BPC 157 was found to counteract the chronic alcohol drinking-induced liver lesions and prevents and reverses portal hypertension in those rats. Recently, to further investigate the effect of BPC 157, we successfully counteracted acute blood pressure increase in portal vein after Pringle maneuver. Providing ischemia/reperfusion injury ongoing with Pringle maneuver, in rats underwent clamping duodenal ligament or clamping removal, lipid peroxidation assessment (indirectly measured by TBARS) in liver was done at the end of the 30 min ischemia, or after clamping removal at the end of 15 min reperfusion period. BPC 157 (10 μ g/kg) medication was a bath given at the clamped area, at 30 min after clamping or immediately after portal triad clamping was removed. TBARS increased values were noted at the end of ischemic period. At the end of the 15 min reperfusion period, an even larger increase was noted. BPC 157 given at the clamped area, counteracted ischemic-induced increase. Likewise, BPC 157 given at the time of reperfusion, counteracted reperfusion-induced increase. Several agents were shown to protect against ischemia/reperfusion injury. All of those agents required more or less prolonged preconditioning, none of them investigated portal hypertension during Pringle maneuver, and none of them was applied after ischemia period to affect specifically the ongoing reperfusion injury. By contrast, BPC 157 was effective immediately following application, in either ischemic or reperfusion condition. Therefore, we evidenced no TBARS oxidative stress increased values in BPC 157 rats, unlike increase in control rats. This suggests BPC 157 as a likely agent to specifically counteract ischemic as well reperfusion injuries.

EP7 THE EFFECT OF PENTADECAPEPTIDE BPC 157 ON EPISCLERAL VEIN CAUTERIZATION MODEL IN RATS

Dora Žaler, Marina Madunić, Matija Rusan

Institution: Department of Pharmacology; School of Medicine University of Zagreb

Contact: dzaler@mef.hr

ORCID: Dora Žaler 0000-0001-6360-0079, Marina Madunić 0000-0002-0601-6930, Matija Rusan 0000-0002-5661-4920

Key words: BPC 157, intraocular pressure, episcleral vein cauterization

Aim. Previously, in a short term study, stable gastric pentadecapeptide BPC 157 initially counteracted increased intraocular pressure (IOP) in rats underwent episcleral cauterization. Now, in a six month study, rats underwent episcleral cauterization instead continuously exhibiting increased IOP, showed normal intraocular pressure with BPC 157 therapy given daily during six month period. **Materials and methods.** Male Albino Wistar rats, randomly divided were used for surgery (two dorsal episcleral veins and one temporal episcleral vein isolated from the surrounding tissues; a cautery specifically applied to the selected vein). Medication (pentadecapeptide BPC 157 (10µg/kg) i.p.) or an equivolume of 0.9% NaCl (5ml/kg) i.p. was applied immediately after surgery, and afterwards once daily. Non-invasive IOP measurements and papilla nervi optici were assessed throughout 3 or 6 months after procedure. Vascularization of the eye fundus and presentation of papilla n. optici were analyzed with microcamera. We focused on the vessels extending into and out of the optic disc, retinal changes alterations in vessel caliber and tortuosity, optic disc pallor and leakage of the retinal arterioles and venules. **Results.** At 3 months after surgery controls exhibited increased values while BPC 157 values remained close to normal IOP. At 6 months controls maintained the increased values and BPC 157 exhibited normal IOP. All BPC 157-rats exhibited only slight generalized vessel caliber irregularity (difference in diameter between arteries and veins) with a vaguely atrophic optic disc and an area not bigger than 1 optic disc diameter containing leaking of retinal vessels. Microscopy analysis correlates well with ophthalmoscopy findings (i.e., BPC 157 groups diameter of the optic nerve remained close to normal unlike control's atrophy/thinning of the optic nerve). **Conclusion.** BPC 157 continuously counteracts the effects of episcleral vein cauterization.

EP8 ADHESIONS AND OXIDATIVE STRESS IN PERFORATED STOMACH LESION IN RATS: PENTADECAPEPTIDE BPC 157, L-NAME, L-ARGININE, RANITIDINE, PANTOPRAZOLE

Ivan Krezić, Marina Madunic, Dora Zaler

Institution: Department of Pharmacology, School of Medicine University of Zagreb

Contact: ikrezic@mef.hr

ORCID: Ivan Krezić 0000-0001-7994-5645, Marina Madunic 0000-0002-0601-6930, Dora Zaler 0000-0001-6360-0079

Key words: adhesions, stomach, lesions, BPC

Aim: We wanted to explore how to pentadecapeptide BPC 157, L-NAME, L-arginine, ranitidine, pantoprazole affect on a oxidative stress and development of adhesions. **Materials and methods:** Male Albino Wistar rats, 200 g b.w., 6 rats per each group. In anaesthetized rats stomach perforation was done at the ventral side, at prepyloric area. At 1 min post-injury, medication: BPC 157 (10µg/ kg), L-NAME (5mg/kg), L-arginine (100mg/kg) alone or combined; pantoprazole (10mg/kg), ranitidine (10mg/kg), saline bath equal volume (controls). At the day 1 and the day 7, defect size and adhesions severity (scored 1-9) (adhesions of the mesentery, intestine were assessed as no present (score 0), or present (score 1); adhesions of the liver/spleen were scored 0-3 (score 0: no adhesions; score 1: adhesions occupying less than one third of the organs surface; score 2: more than one third but less than two third ; score 3: more than two third), with visible perforation was scored as 1). Tissues sections were processed for histological analysis. At the 15 minutes post-injury, oxidative stress in tissue samples was assessed by quantifying thiobarbituric acid (TBA) reactivity as malonaldehyde equivalents (MDA). At the 15 minutes post-injury, we determined nitric oxide (NO) in stomach tissue samples using the Griess reaction. **Results:** Controls, L-NAME, L-arginine and L-NAME, pantoprazole showed, after one day as well as after one week, that defect remained open and adhesions increased. BPC 157, L-arginine and/or L-NAME with BPC 157 treated rats showed less defect at the day 1, and no defect detectable at the day 7 and less adhesions presented. L-arginine, ranitidine showed defect less than controls and at the day 7 not open any more, but still adhesions presented. Less NO-levels in rats underwent stomach perforation, but reversal with BPC 157 administration. Lipid peroxidation assessment measured by MDA demonstrated a increase in rats underwent stomach perforation, but no MDA-oxidative

EP9 PENTADECAPEPTIDE BPC 157 AND SPINAL CORD INJURY IN RATS

Ivan Krezić, Slaven Gojković, Mariam Samara

Institution: Department of Pharmacology, School of Medicine University of Zagreb

Contact: ikrezic@mef.hr

ORCID: Ivan Krezić 0000-0001-7994-5645, Slaven Gojković 0000-0003-4020-326X, Mariam Samara 0000-0003-2384-273X

Key words: BPC, spinal, cord, injury

Aim: We demonstrated that the stable gastric pentadecapeptide BPC 157 improved the spinal cord injury. **Materials and methods:** Male Albino Wistar rats (12 weeks aged, 350-400 g b.w.), 20 rats per each group, were used for the experiment. Anesthetized rats were subjected to laminectomy at lumbar level L2-L3 which correspond to sacrocaudal spinal cord S2-Co1. A neurosurgical piston was placed over exposed dura and left 60 second for compressive injury. After piston removal muscle and skin incision were closed. Thereafter animals returned to cages in pairs with provided food and water ad libitum. In cages, half of rats was given BPC (10 µg/kg) ad libitum on the fourth day of the surgical procedure and the other half of rats (control group) got just a water. Next twenty days we recorded and assessed tail motor function as follows: 1-complete loss of tail function; 2-elevation maximum of 1/4 of tail length; 3-elevation maximum of 1/2 of tail; 4-elevation maximum of 3/4 of tail length; 5 –normal function). **Results:** Tail motor function score in rats underwent spinal cord injury that received saline post-injury showed that they managed to recover just a small part of their previously tail motor function. Contrarily, all rats that had received BPC 157 exhibited consistent improvement, constantly better motor function than the corresponding controls. **Conclusion:** In conclusion, this therapy of the spinal cord injury extends the BPC 157 neuroprotective effect in the rescue of the peripheral nerve injury to a sustained and prolonged improvement achieved in the rescue of the spinal cord injury.

EP10 BLEEDING PERIOD AND PRESENTATION OF BLOOD VESSELS IN A PERFORATED STOMACH LESION IN RATS: PENTADECAPEPTIDE BPC 157, L-NAME, L-ARGININE, RANITIDINE, PANTOPRAZOLE

Ivan Krezić, Slaven Gojković, Mariam Samara

Institution: Department of Pharmacology, School of Medicine University of Zagreb

Contact: ikrezic@mef.hr

ORCID: Ivan Krezić 0000-0001-7994-5645, Slaven Gojković 0000-0003-4020-326X, Mariam Samara 0000-0003-2384-273X

Aim: We wanted to explore how to pentadecapeptide BPC 157, L-NAME, L-arginine, ranitidine, pantoprazole affect on a bleeding and presentation of blood vessels in a perforated stomach lesion in rats.

Materials and methods: Male Albino Wistar rats, 200 g b.w., 6 rats per each group, were used for the experiment. In anaesthetized rats perforation was done at the ventral side, at prepyloric area, and rats monitored for next 15 minutes period, at particular time points, indicated as A, B, C, D, E, as follows: A- after perforation (1 min); B – during application (2 minutes); C period after application (2 minutes); D – next 5 minutes period; E – period till the end of the observation (15 minutes). At 1 min post-injury, medication at the perforate lesion, includes BPC 157 (10µg/kg), L-NAME (5mg/kg), L-arginine (100mg/kg) alone or combined; pantoprazole (10mg/kg) and ranitidine (10mg/kg), saline bath equal volume (controls). Assessment was with a USB microscope camera. We recorded and assessed blood vessels, appearance or disappearance. Bleeding time from perforate lesion (sec) was assessed throughout 15 min.

Results: Controls showed progressive vessel disappearance and significant bleeding period. BPC 157 treated rats showed progressive vessel presentation and bleeding period significantly shortened. L-arginine showed vessel presentation while bleeding is continuous till the end of the observation period. L-NAME showed vessel increased disappearance and bleeding period shortened. L-arginine and L-NAME showed a combined effect of the vessel presentation, bleeding period close to the control. BPC 157 with L-arginine and/or L-NAME showed presentation (progressive vessel presentation, shortened bleeding time) like the rats that receive BPC 157 alone. Pantoprazole with vessel disappearance while bleeding period is prolonged. Ranitidine showed the vessel presentation while bleeding period is shortened.

Conclusion: Research shows that control decreases vessel presentation and prolongs bleeding period. BPC 157 increases vessel presentation, reduces bleeding time, immobilizes (L-NAME+L-arginine), stimulates (L-arginine) or blockes (L-NAME). L – Arginine shows vessel presentation and prolongs bleeding period. L-NAME and L-arginine antagonize each other's response. Pantoprazole shows vessel disappearance and prolongs period of bleeding. Ranitidine shows the vessel presentation and decreases bleeding period.

EP11 PANCREATIC DUCTAL ORGANOID CULTURES ARE SUITABLE MODEL TO STUDY PANCREATIC DUCTAL ION SECRETION

Laith Alsardih, Réka Molnár, József Maléth, Péter Hegy

Institution: University Of Szeged - Hungary

Contact: laith.alsardi@gmail.com

Introduction: Pancreatic ductal fluid and HCO₃⁻ secretion are crucially important in the physiology and pathophysiology of the exocrine pancreas. However the study of human pancreatic secretory processes is great challenge due to the limited access to human pancreatic ductal cells. The recently developed three-dimensional pancreatic organoid cultures (OC) may help to overcome this limitation. However the ion secretory processes in pancreatic OC is not known.

Aim: Our aim was to characterize the ion transport processes in mouse pancreatic OCs.

Methods: Mouse pancreatic ductal fragments were isolated by enzymatic digestion. The isolated ducts were grown in Matrigel on 37°C for a week in OC media. Changes of the intracellular pH was measured to characterize the ion transporter activities of the epithelial cells in OC.

Results: Basolateral administration of 20mM NH₄Cl in standard HEPES or CO₂/ HCO₃⁻ buffered solution resulted in rapid intracellular alkalization, which was followed by a recovery phase. Removal of NH₄Cl induced rapid acidification followed by regeneration to the resting pH levels. The regeneration phase was inhibited by the removal of extracellular Na⁺. The administration of 10μM CFTRinh172, a selective inhibitor of cystic fibrosis transmembrane conductance regulator decreased the regeneration from alkali load. Basolateral administration of 20mM amiloride and 20mM H₂DIDS decreased the intracellular pH suggesting the activity of Na⁺/H⁺ exchanger and Na⁺/HCO₃⁻ cotransporter on the basolateral membrane.

Summary: The ion transport activities in mouse OC are similar to those observed in freshly isolated primary tissue. This suggest that OC will be suitable to study human ductal epithelial ion transport.

EP12 N-ACETYL-A-NEURAMINIDASE 1 DEFICIENCY

Luka Švitek¹, Luka Perić², Silvija Pušeljić³

Institution: ^{1,2}Faculty of Medicine J.J. Strossmayer University of Osijek, Croatia; ³Division for Neuropediatrics, Genetics, Metabolic diseases and Endocrinology, Department of Pediatrics, KBC Osijek, Croatia

Contact: svitek.luka@gmail.com

ORCID: Luka Švitek 0000-0003-0208-5821, Luka Perić 0000-0001-5124-1443, Silvija Pušeljić 0000-0002-9500-2185

Key words: NEU1, sialidosis, lysosomes

N-acetyl-α-neuraminidase 1 (NEU1) is a lysosomal enzyme. Main function of NEU1 is catalyzing hydrolysis of terminal residues of sialic acid. Gene for NEU1 is located in short arm of chromosome 6 at position 21.33 (6p21.33). Gene expression is mostly present in kidney, pancreas, skeletal muscles, liver, lungs, placenta and brain tissue.

NEU1 and its deficiency: Mammalian NEU1 is forming a complex with cathepsin A and β-galactosidase. Cathepsin A activates and protects NEU1 and β-galactosidase from proteolytic lysosomal enzymes. Substrates for NEU1 are glycolipids and glycoproteins that are containing oligosaccharide groups. It contains Tyr-X-X carboxyl terminal hydrophobic end. Posttranslational modifications of NEU1 include N-glycosylation in three parts of a molecule. NEU1 is transported to lysosome with adapter proteins – they create a bond with C-terminal end. NEU1 is subjected to final processing inside a lysosome. Active site of NEU1 is formed by six quadruple stranded antiparallel β sheets distributed in a propeller like structure around central axis. Arginine is in the center of an active spot. NEU1 has affinity for α2 à 3 and α2 à 6 sialic bonds. Optimal pH for NEU1 is 4,6. Besides a lysosome NEU1 can be translocated in cell membrane or in ECM by exocytosis. If there is a deficiency of NEU1 lysosomes are unable to disintegrate oligosaccharide groups from mucopolysaccharides and mucopolypids so they are accumulated. This disease is called sialidosis type I. It is inherited by autosomal recessive inheritance pattern with incidence of 1:4 220 000. New researches have shown that NEU1 also has big role in carcinoma malignancy, immunologic system, exocytosis, modulation of cellular proliferation, elastic fibers synthesis and insulin signalization. Our patient with this disease has a walking disorder. MRI shows periventricular hyperintensity by occipital horns and multiple Schmorl hernias of thoracic and lumbar segment of spinal column. Patient has a cherry-red spot at a macula. In urine sample are visible oligosaccharides characteristic for sialidosis type I. Disease is progressive.

Conclusion:

NEU1 has many important roles. Further understanding and research of this enzyme will have a major role in treatment of rare diseases, cancer and many more medical problems of our time.

EP13 EXPRESSION OF NESTIN IN CONGENITAL MELANOCYTIC NEVI

Ljubica Bakić, Anastasia Milić, Marko Barović, Martina Bosić

Institution: Institute of Pathology, Faculty of Medicine, University of Belgrade

Contact: ljubica_993@hotmail.com

ORCID: Ljubica Bakić 0000-0002-7872-5402, Anastasia Milić 0000-0003-2549-7175, Marko Barović 0000-0002-0839-6009, Martina Bosić 0000-0001-7113-2834

Key words: CMN, stem cells, age, localization

Introduction: Congenital melanocytic nevi (CMN) are benign tumors of neural crest origin that are present at birth. Nestin is a neuroectodermal stem cell and pluripotency marker. Its expression was previously associated with medium and large CMN. **Aim:** To determine expression of Nestin in CMN and to analyze the results in relation to gender and age of patients, size and localization of nevi.

Materials and methods: Superficial, middle and deep parts of 105 CMN were included in the tissue microarray. The samples were immunohistochemically stained using anti-Nestin antibodies. Level of expression was calculated as ratio of positive and total number of nevi cells and analyzed in relation to clinical characteristics. **Results:** Nestin expression in CMN varied from 0% to 100% with median of 8.4%. The highest expression was observed in the middle parts (med 9.4%), whereas the lowest expression was observed in the deep parts of nevi (med 6.6%) but without significant difference ($p=0.180$). There was no difference in Nestin expression between genders. Nestin expression in the deep parts of nevi increased with age of patients ($p=0.029$). Greatest expression in deep parts of the nevi was noticed on the head and neck region (med 25.25%) and lowest expression was noticed on the lower extremities (med 2.4%) ($p=0.023$). Expression was not associated with nevi size.

Conclusion: In general, Nestin expression is low but homogeneous in CMN. Expression is associated with age of patients and localization of nevi.

EP14 COUNTERACTION OF PERFORATED CAECUM LESION IN RATS: PENTADECAPEPTIDE BPC 157, L-NAME, L-ARGININE

Mariam Samara, Borna Vrdoljak, Dora Žaler

Institution: Department of Pharmacology, School of Medicine University of Zagreb

Contact: mariam.samara@gmail.com

ORCID: Mariam Samara 0000-0003-2384-273X,

Key words: caecum perforation, BPC157, L-name, L-arginine

Introduction: Cecal perforation is serious condition associated with high mortality and morbidity. It prolongs already complicated recovery and is favorable medium for bacteria growth. Having in mind BPC 157 cytoprotective effect, we hypothesized that cecal lesion could be reduced and eventually healed with BPC157. **Objectives:** Cecal perforation in rats was made, and large immediate defect was present, it was unable to constrict and was with leaking fluid. We administrated different medications (depending on a group) and later visualized the beneficial effect of BPC157. Tissue regained integrity alongside with the agent's application at the perforate injury: then, the defect contraction and attenuation of the bleeding.

Aims: We argue stomach/caecum lesion analogy. Prototype cytoprotective agent, BPC157, rescues perforated caecum lesions in rats since it resolves damaged stomach epithelium integrity.

Methods: Medication (/kg, 1ml bath/rat) at the perforated caecum, includes BPC 157 (10 μ g), NOS-blocker L-NAME (5mg), NOS-substrate L-arginine (100mg) alone or combined; saline bath equal volume. Using USB microscope camera Veho discovery VMS-004 deluxe, respecting point immediately before therapy, we assessed defect closing or widening (as % of presentation immediately before therapy). At day 7, defect size (serosal/mucosal) were assessed.

Results: After perforation, during and after saline bath, defect slightly narrowed (only 15% within first 40 sec). With BPC 157 bath, defect narrowed by 40%. L-NAME did not change defect and neither did L-arginine. In combination, we have mutual counteraction or presentation like BPC 157 rats, except to the defect not changed. At 7 day, saline L-NAME, L-arginine, L-NAME+L-arginine failed. Therapy effect was with BPC 157 alone or combined, closed caecum defect.

Conclusion: Considering early mentioned result, we can conclude that BPC157 is the agent that promptly improves healing of cecal lesions and could be solution for this serious condition

EP15 THE EFFECT OF COMBINED APPLICATION OF NO-SYSTEM AGENTS AND BPC157 ON BLOOD VESSELS OF PERFORATED CAECUM IN RATS

Mariam Samara, Marina Madunić, Marko Antunović

Institution: Department of Pharmacology, School of Medicine University of Zagreb

Contact: mariam.samara@gmail.com

ORCID: Miriam Samara 0000-0003-2384-273X

Key words: caecal perforation, BPC 157, NO-system, blood vessels

Introduction: After proving BPC157 beneficial effect on narrowing cecal lesion, we decided to determine mechanism. Since we've already proven it does so by maintaining blood perfusion, increasing number of anastomosis and shortening time of bleeding, we were interested in seeing the impact of NO system agents

Objectives: We perforated caecum and blood vessels disappeared at serosa (ischemia/re-oxygenation injury). We administered different medication (L-name, L-arg, BPC157 and combinations) and assessed presentation of blood vessels and number of anastomosis right after perforation was made, after application and after 5min

Aims: Similar to experiment with lesion narrowing, we argue stomach/caecum lesion analogy. Since BPC157 resolves damaged stomach epithelium integrity by rapidly rescuing damaged endothelium, we hypothesized it rescues perforated caecum lesions by doing the same

Methods: Medication (/kg, 1ml bath/rat) at the perforated caecum, includes BPC 157 (10µg), NOS-blocker L-NAME (5mg), NOS-substrate L-arg(100mg) alone or combined; saline bath equal volume. With micro camera respecting point immediately before th, we recorded and assessed blood vessels (total % of caecum vessels augmentation/reducing from proximal to distal end = [number of blood vessels (10 vessels assessed) /100] x % of augmentation/reducing of each vasa recta (0 as point immediately before th); bleeding time(sec), throughout next 10 min

Results: After perforation, during and after saline bath, blood vessels were reduced by 60%, bleeding for 365 sec. With BPC 157 bath, vessels presentation was increased by 30%, bleeding shortened (100 sec). L-NAME -60%, shortened bleeding (98 sec); vs. L-arg -37%, prolonged bleeding (687 sec); In combination, we have mutual counteraction (L-NAME+L-arg) or presentation like BPC 157 rats

Conclusion: BPC157 therapy success in both very early and late terms is undeniable. Although L-name and L-arg used alone had bad results, when used with BPC157 the success was obvious

EP16 OXIDATIVE STRESS IN PERFORATED CAECUM TISSUE

Mariam Samara, Marko Antunović

Institution: Department of Pharmacology, School of Medicine University of Zagreb

Contact: mariam.samara@gmail.com

ORCID: Mariam Samara 0000-0003-2384-273X,

Key words: free radicals, oxidative stress, perforated caecum

Introduction: Free radical is a substance that has an unpaired valence electron. They usually make free radicals highly chemically reactive and can lead to oxidative stress. Oxidative stress can be valuable indicator of ischemia.

Objectives: We assessed oxidative stress in tissue samples by quantifying thiobarbituric acid as malonaldehyde equivalents

Aims: To investigate and assess oxidative stress in tissue

Methods: At the 15 minutes post-injury, oxidative stress in tissue samples was assessed by quantifying TBA reactivity as MDA equivalents. To homogenized tissue sample trichloroacetic acid was added and centrifuged (3,000 rpm, 5 min) and supernatant was collected. Thereafter, 1% TBA was added and samples boiled (95°C, 60 min). The tubes were kept in on ice or 10 minutes and the absorbance was determined at the wavelength of (532 and 570 nm). The concentration of MDA was read from standard calibration curve plotted using 1, 1, 3, 3' tetra-ethoxy propane. The extent of lipid peroxidation was expressed as MDA using a molar extinction coefficient for MDA of 1.56×10^5 mol/L/cm. The results were expressed in nmol/mg of protein

Results: In the early term, lipid peroxidation assessment (indirectly measured by TBARS) demonstrated a huge increase in rats underwent caecum perforation, but no TBA-oxidative stress in rats with perforate caecum underwent BPC 157 medication. In the early term, NO level assessment demonstrated a drop in rats underwent caecum perforation, but NO values like in the healthy in rats with perforated caecum underwent BPC157 medication

Conclusion: Lipid peroxidation and NO-levels assessment demonstrated no MDA-oxidative stress and normalized NO-tissue values in rats with perforate caecum underwent BPC 157 medication. Otherwise, with ischemia/reperfusion in caecum, increased MDA values and decreased NO-level are suggestive for ischemia/reperfusion injury and the oxidative stress that would regularly appear as results of the lysis of endothelial cells

EP17 LIGATED SUPERIOR MESENTERIC VEIN IN RAT AND BENEFICIAL EFFECT OF STABLE GASTRIC PENTADECAPEPTIDE BPC 157

Marina Madunić, Dominik Malekinušić

Institution: Department of Pharmacology, School of Medicine University of Zagreb, Croatia

Contact: marina.madunic@hotmail.com

ORCID: Marina Madunić 0000-0002-0601-6930, Dominik Malekinušić 0000-0001-6258-5647

Key words: Ligation, SMV, BPC 157, oxidative stress

Introduction: Superior mesenteric vein injuries are rare, but incur high mortality. BPC 157 rescues obstruction by rapidly rescuing epithelium.

Objectives: Administration of BPC 157 after ligation and observation of vessel presentation **Aim:** To verify beneficial effect of BPC 157 in rats with ligated superior mesenteric vein **methods:** In this study, in rats, SMV was ligated close to portal vein for 15 min. Medication (/kg, 1ml/bath) at the ligated SMV, includes at 1min post-ligation, BPC 157 (10ug), or saline bath equal volume (controls). Through whole period, with a USB microscope camera (MC) Veho discovery VMS-004 deluxe, we recorded vessels presentation. After 15 min oxidative stress was assessed by quantifying thiobarbituric acid (TBA) reactivity as malonaldehyde equivalents (MDA).

Results: Controls has poor CV, repletion and ramification, and increased lipid peroxidation. Reversal by BPC 157 application.

Conclusion: We evidenced no MDA oxidative stress increased value with BPC 157

EP18 COUNTERACTION OF ISCHEMIC COLITIS LESION IN RATS: PENTADECAPEPTIDE BPC 157, L-NAME, L-ARGININE

Marko Antunović, Marina Madunić, Matija Rusan

Institution: School of Medicine University of Zagreb

Contact: mantunovic@student.mef.hr

ORCID: Marko Antunović 0000 0002 3801 5481, Marina Madunić 0000 0002 0601 6930, Matija Rusan 0000 0002 5661 4920

Key words: ischemic colitis , bpc157 , rats , L-NAME , L-arginine

Aim. Stomach cytoprotection/ischemic colitis lesion may have analogous therapy. Prototype cytoprotective agent (CA), gastric pentadecapeptide BPC 157 rescues ischemic colitis (IC) lesion in rats by rapidly rescuing damaged endothelium. **Methods.** Post-injury (in rats, a segment of left colic artery and vein excluded by 2 ligations, 3 arcade vessels within ligated segment) application of medication (/kg, 1ml bath/rat) includes BPC 157 (10µg), NOS-blocker L-NAME (5mg), NOS-substrate L-arginine (100mg) alone or combined; saline bath equal volume (controls). We recorded vessels presentation between arcade vessels 15min after application and the extent of pale areas; oxidative stress was assessed by quantifying thiobarbituric acid (TBA) reactivity as malonaldehyde equivalents (MDA). Same BPC 157 protocol was used in the IC rats underwent additional colon obstruction (OB) (plastic ring, 4mm diameter) for 2 or 3 days (IC+OB rats). Extent of pale areas and ulcerated areas was assessed upon colon opening at day 7 after ring removal and bath-therapy application.

Results/Conclusion. After saline bath, blood vessels were reduced by 60% (at 15 min); pale areas largely presented (46% of the whole segment). With BPC 157 bath, vessels presentation increased by 50%; small pale areas reduced (7%). L-NAME initially disappears all vessels, reduction by 70% between 3-4 at dorsal side at 15min, larger pale areas, 80%; vs. L-arginine increased vessels by 20%, pale areas as 65%. In combination, we have mutual counteraction (L-NAME+L-arginine) or presentation like BPC 157 rats (BPC 157+L-NAME; BPC 157+L-arginine; BPC 157+L-NAME+L-arginine). Unlike increase in IC controls, to counteract I/R lesion, with BPC 157, we evidenced no MDA oxidative stress increased values. At 9/10 day, IC+OB rats had 100% pale areas (OB for 2 days) and many ulcerations (OB for 3 days), BPC 157 have markedly lessened pale areas (10%) and no ulcerations.

EP19 BENEFICIAL EFFECT OF STABLE GASTRIC PENTADECAPEPTIDE BPC 157 ON A LIGATED SUPERIOR MESENTERIC ARTERY AND VEIN IN RATS

Matija Rusan, Marina Madunic

Institution: School of Medicine University of Zagreb

Contact: mrusan@mef.hr

ORCID: Matija Rusan 0000-0002-5661-4920, Marina Madunic 0000-0002-0601-6930

Key words: BPC 157, ischemic/reperfusion, lesion, ligated

Aim. Stomach cytoprotection superior mesenteric artery (SMA) and vein (SMV) ligation (SMAV) lesion may have analogous therapy, prototype cytoprotective agent (CA), gastric pentadecapeptide BPC 157 rescues SMAV obstruction lesion in rats, since CA resolves damaged stomach epithelium integrity by rapidly rescuing damaged endothelium. **Methods.** To counteract ischemic/reperfusion (I/R) lesion, rapid CA rescue means that post-injury (ligation of (SMA) and (SMV) the collateral vessels (CV) are quickly bypassing the hindering defects, and replete original SMA/SMV flow, the vasa recta vessels (VRV) reappear at the intestine surface, venous congestion (VC) avoided. This goes to regain tissue integrity alongside with the agent's application at the ligated SMA/SMV. Medication (/kg, 1ml/bath) at the ligated SMA/SMV, BPC 157 (10ug), or saline bath equal volume (controls). Through whole period, with a microscope camera (MC), we recorded vessels (SMA, SMV, empty (scored 0), sub-empty (1), sub-normal (2), normal (3)), CV (scored 0-3, and above-normal (4)), VRV repletion and ramification (0-4), VC (0-5: no; poor; mild/moderate/intense/massive) (caecum, 5-10-15min); with angiography, at 5 min ligation-time, BPC 157 bath or saline bath, and contrast 5ml/10sec), SMA and CV presentation was scored 0-2, not-detectable, hardly detectable, detectable. After 15 min lipid peroxidation assessment (measured by TBARS) was done.

Results/Conclusions. In control SMAV-ligated, MC-recording (Min/Med/Max) through whole period revealed SMA almost empty, poor CV, VRV deteriorating repletion (5-10-15min) and ramification; VC (4/4/4-5/5/5-5/5/5); in angiography, SMA and CV presentation was not-detectable. In SMA-ligated rats underwent BPC 157 bath, camera revealed quickly SMA close to normal, CV above-normal, VRV increased repletion (5-10-15min) and ramification decreased VC. Unlike increase in SMAV-ligated control rats (I/R lesions), with BPC 157, there wasn't no increased oxidative stress.

EP20 THE EFFECT OF THE PENTADECAPEPTIDE BPC 157 ADMINISTERED INTRAOPERATIVELY ON THE SCIATIC NERVE CRUSH INJURY IN A RAT MODEL

Slaven Gojković, Marko Antunović, Ivan Krezić

Institution: Institute of Pharmacology, School of Medicine University of Zagreb

Contact: sgojkovic@mef.hr

ORCID: Slaven Gojković 0000-0003-4020-326X, Marko Antunović 0000-0002-3801-5481, Ivan Krezić 0000-0001-7994-5645

Key words: nerve, injury, sciatic, BPC

Objectives: To determine the effect of the pentadecapeptide BPC 157 on the outcomes of the sciatic nerve crush injury in rat model. **Materials and methods:** 40 Wistar male rats, 280-300g b. w., were randomly divided into two groups: 20 rats to control group and 20 rats to BPC 157 treated group. After randomization rats were anaesthetized with diazepam (1 mg/kg) and thiopental (0,75mg/kg) and then underwent surgery procedure. The sciatic nerve injury was made by 1 minute compression of the sciatic nerve using special instrument. Immediately after compression was administered distilled water (1 mL, in control group) or BPC 157 (10µg/kg dissolved in 1mL, in BPC 157 treated group) were directly applied on the injured nerve and its surrounding structures. Rats were monitored for next 5 minutes, by USB microscope camera, at period particular time points: before injury and five minutes after. We compared blood vessels appearance before and 5 minutes after injury. Animals were neurologically analyzed and sacrificed at 1, 4, 5, 7 postoperative day, respectively. Examination included measures of the contraction, physical appearance and walking patterns of the affected leg, rat posture and general movement and intraoperative blood vessel presentation on sciatic nerve's surface. After sacrifice tissue samples were taken for histological analysis.

Results: Results showed that BPC 157 increased blood vessels appearance on the surface of injured sciatic nerve and blood vessel bridged defect while control decreased blood presentation. BPC 157 treated group showed better outcome (macroscopic and microscopic) since first postoperative day, along with further improvement till sacrifice, what was in contrast to control group which showed almost no recovery during the whole examination period.

Conclusion: BPC 157 shows particular beneficial effect in otherwise slow healing of sciatic nerve after crush injury in control group.

EP21 HOW TO COUNTERACT PERFORATED STOMACH LESION IN RATS: PENTADECAPEPTIDE BPC 157, L-NAME, L-ARGININE, RANITIDINE, PANTOPRAZOLE

Slaven Gojković, Mariam Samara, Ivan Krezić

Institution: Institute of Pharmacology, School of Medicine University of Zagreb

Contact: sgojkovic@mef.hr

ORCID: Slaven Gojković 0000-0003-4020-326X, Mariam Samara 0000-0003-2384-273X, Ivan Krezić 0000-0001-7994-5645

Aim: We demonstrated how to pentadecapeptide BPC 157 (1-6), L-NAME, L-arginine, ranitidine, pantoprazole affect on counteracting of perforated stomach lesion in rats.

Materials and methods: Male Albino Wistar rats, 200 g b.w., 6 rats per each group. In anaesthetized rats stomach a perforation (made by with metal needle 5mm diameter) was done at the ventral side, at prepyloric area, and rats monitored for next 15 minutes period, at particular time points, indicated as A, B, C, D, E, as follows: A- after perforation (1 min); B – during application (2 minutes); C period after application (2 minutes); D – next 5 minutes period; E – period till the end of the observation (15 minutes). At 1 min post-injury, medication at the perforate (5mm diameter) lesion, includes BPC 157 (10µg / kg), L-NAME (5mg/kg), L-arginine (100mg/kg) alone or combined; pantoprazole (10mg/kg), ranitidine (10mg /kg), saline bath equal volume (controls). We recorded by USB microscope camera defect closing or widening (both as % of presentation immediately before therapy). After sacrifice tissue samples were taken for histological analysis.

Results: Controls showed defect with initial more widening. BPC 157 treated group showed defect with contraction. L-arginine treated rats showed widening of defect but less than controls. L-NAME treated rats showed widening of defect but less than controls. After application of L-arginine and L-NAME, rats with perforate stomach lesion showed widening of defect but less than controls. BPC 157 with L-arginine and/or L-NAME rats showed that the defect is regularly contracted, except no changed in L-arginine+BPC 157 rats. After application of pantoprazole, rats with perforate stomach showed widening of defect but less than controls. After application of ranitidine, rats showed that defect did not changed.

Conclusion: This research shows that BPC 157, alone or in combination with L-NAME, improves healing of defect, except in combination with L-arginine where is no changes. Ranitidine does not change defect and the others medication causes widening of defect.

EP22 CAPSULES FROM FISH

Abu Talha Bin Fokhrul, Sirajum Munira

Institution: Sylhet MAG Osmani Medical College

Contact: dr.hasibrahman@gmail.com

ORCID: Abu Talha Bin Fokhrul 0000-0002-4886-5332, Sirajum Munira 0000-0001-8820-4080

Key words: fish gelatin, cheaper, acidity, eco-friendly

Introduction: Can capsules (Pharmacy) from fish gelatin be a safe alternative to capsules from animal gelatin? So in this paper, we will discuss the effectiveness of an alternative capsule from fish gelatin for all the people around the world which will be cheaper and greatly useful for our body. **Methods:** Independent variables: • Boiled water Dependent variables: • Gum Tragacanth • Titanium Oxide • Fish scales, bones and fins • Mortar and pestle • Beaker • Sorbitol At first, we have to take necessary quantities of fish scales and bones, boil them at a temperature of 130-140 degrees and triturate the disinfected fish bones and scales with a mortar and pestle. Then we will mix the resulting powder with Gum Tragacanth and sorbitol to make it gummy or sticky and mix Titanium Oxide(.0425gm/1kg) with the mixture. Now, if we dip a metal inside this mixture, we will get fish capsules. **Results:** Fish scales, bones and fins are regarded as kitchen waste but we can reuse them through recycling to keep the environment clean and healthy. Capsules made of animal gelatin can not exist in more than 15 degrees but capsules from fish gelatin can exist upto 30 degrees. An interesting thing is that it can prevent acidity for upto 12 hours and it is proved theoretically. **Conclusion:** The aim of this presentation is to create an eco-friendly environmental system that will help turn kitchen waste into something that can save millions of lives.

EP23 THE SYSTEMIC SKELETAL EFFECTS OF IMMUNIZATION

Igor Radanović, Martina Fadljević

Institution: University of Zagreb School of Medicine, Department of Anatomy, and Laboratory for Molecular Immunology, Croatian Institute for Brain Research, Croatia
Contact: igor.radanovic94@gmail.com

Key words: arthritis, immunization, antigen, osteopenia

Introduction: Rheumatoid arthritis (RA) is a systemic autoimmune disease, characterized by synovial thickening, infiltration by inflammatory cells and underlying bone destruction. Various murine models serve as an important tool to study the disease mechanisms and potential therapeutic targets. One of them is antigen-induced arthritis (AIA), induced by intraarticular injection of methylated(m)BSA in previously immunized animals.

Objectives: AIA results in systemic osteopenia, as well as local bone loss, the later being of higher interest, as a cause of disability in patients. In many previous studies, local bone loss has been assessed in the subchondral metaphyseal area using non-immunized mice as control group, and therefore measuring bone loss resulting from systemic effect of immunization, rather than arthritis itself. The objective of this study is to assess the extent of systemic effect of immunization protocol on the bone volume.

Methods: Twelve-weeks old C57B6 female mice were immunized with mBSA in Complete Freund's adjuvant (CFA) injected subcutaneously (s.c.), followed by intraarticular (i.a.) injection of mBSA in PBS in both knees (AIA groups). Control groups (ctrl) were immunized with mBSA in CFA and i.a. injected with phosphate buffered saline (PBS). AIA and ctrl groups were further subdivided into groups immunized with emulsion containing 2 mg/mL, and 0.5 mg/mL M. tuberculosis. Non-immunized (NI) group was injected with PBS both s.c. and i.a. Number of mice/group was 5-7. Systemic bone loss was evaluated by micro-computed tomography analysis of the second lumbar vertebrae.

Results: Trabecular bone volume (BV/TV, %) of the second lumbar vertebrae was significantly lower in immunized groups (ctrl and AIA) in comparison to non-immunized group ($p < 0.05$, Kruskal-Wallis test). There was no difference in BV/TV between AIA and ctrl mice, as well as between groups immunized with different concentrations of M. Tuberculosis.

Conclusion: These findings suggest that even low-adjuvant immunization protocol induces systemic osteopenia which should be taken into account when assessing local bone loss in arthritis. Our preliminary data point that epiphyseal areas are less affected by immunization and might be most suitable to assess effects of local inflammation on bone.

EP24 EFFECT OF SUCROSE ON ALCOHOL ABSORPTION IN RATS

Paulo Zekan¹, Marijana Blagaić²

Institution: ¹Institute of Pharmacology, School of Medicine, University of Zagreb; ² Faculty of Food Technology and Biotechnology, University of Zagreb
Contact: paulo.zekan@student.mef.hr
ORCID: Paulo Zekan 0000-0002-0932-8518, Marijana Blagaić 0000-0001-5043-1018

Key words: alcohol, sucrose, gastric emptying

Introduction: Gastric emptying is rate-determining step in alcohol absorption since small intestine is the main site of alcohol absorption. In addition to liver, first-pass metabolism of alcohol occurs in stomach due to isoenzyme alcohol dehydrogenase (ADH). Sucrose is disaccharide consisting of one glucose and one fructose unit and is commonly used sweetener. Caloric meal consumption delays gastric emptying by post-pyloric signal in order to ensure steady caloric delivery rate to duodenum.

Objectives: The objective of the study was to assess whether sucrose has impact on alcohol absorption in rats. AIMS The objective was achieved by measuring blood alcohol concentration at different time after intragastric application of alcoholic solution. Maximal blood alcohol concentration (C_{max}) and area under concentration-time curve (AUC) was determined as summary data representing alcohol absorption.

Methods: The study was randomized and 66 Wistar rat were included. The rats were sampled in the samples of size 6 and 11 samples were further separated into two groups: control (C, n=6) and sucrose (S, n=5). Control group was administered 11,9 ml/kg of non-sweetened alcoholic solution (v/v=16%) and S group was administered 11,9 ml/kg of sucrose-sweetened alcoholic solution (v/v=16%). Each rat from the sample was collected 1ml of blood once at different time (t=0, 10,20,40,60,90,120 min). The blood was collected via intravenous cannula from the tail vein. Blood alcohol concentration was measured by standard laboratory methods. C_{max} and AUC were determined for each sample.

Results: C_{max} (g/L) was significantly lower in S group in comparison to C group. AUC was significantly lower in S group in comparison to C group.

Conclusion: The study showed that maximal blood alcohol concentration as well as amount of alcohol absorbed are lower after administration of sweetened comparing to non-sweetened solution. Hence, the results are in accordance with similar studies conducted in humans.

EP25 LUNG ULTRASOUND IN THE FOLLOW-UP OF ETIOLOGICALLY DIFFERENT COMMUNITY-ACQUIRED PNEUMONIA IN CHILDREN: A PROSPECTIVE STUDY

Anja Pintarič, Vojko Berce

Institution: Faculty of Medicine University of Maribor

Contact: anjapintaric89@gmail.com

ORCID: Anja Pintarič 0000-0001-9823-5411

Key words: pneumonia, children, etiology, lung ultrasound

Introduction. Community acquired pneumonia (CAP) is a common cause of pediatric hospitalization and mortality. It can be caused by different pathogens. There is no pathognomonic sign and radiological diagnostics is usually needed. Lung ultrasound (LUS) has become important imaging method in diagnostic and monitoring. **AIM.** We assumed that clinical, laboratory and imaging characteristics differ significantly between bacterial, viral and atypical pneumonia.

Patients and methods. 117 children were included in this prospective study. They were hospitalized due to CAP. We noticed presence of fever, signs of upper respiratory tract inflammation, pains in chest/stomach, respiratory distress, wheezes, crackles, diminished breath sounds, signs of lung consolidation. C-reactive protein and white blood cells were determined. We verified viral pathogens and Mycoplasma pneumoniae with PCR from nasal swab. For detecting bacterial pathogens, we used sputum or deep pharyngeal aspirate and blood culture. We performed chest X-ray and LUS and recorded the presence, location and nature of infiltrates. We repeated the LUS within the next 2-4 days.

Results. We detected Mycoplasma in 23,9%, viral in 32,5%, bacterial in 43,6%. Fever was most frequently present in children with bacterial pneumonia. We noticed signs of decreased breathing and consolidation more often in this group. Children with viral pneumonia had more signs of upper respiratory tract inflammation, auscultatory phenomena, respiratory distress. Infiltrates on chest X-ray were visible in 81,2% and on LUS in 98,3%. Control LUS has shown that infiltrates reduce or disappear in bacterial (95,1%) and likely reduce in atypical (83,3%), but two-thirds of children with viral pneumonia had the same infiltrates.

Discussion and conclusion. If we take the full range of characteristics, we can quite reliably identify the etiology of the CAP. LUS was proved to be at least as sensitive method for detecting CAP as chest X-ray.

EP26 POSTOPERATIVE COMPLICATIONS AFTER CONIZATION: DOES THE USE OF INTRAUTERINE DEVICES OR ORAL CONTRACEPTIVES MATTER?

Anja Pintarič¹, Monika Sobočan², Darja Arko³, Iztok Takač⁴

Institution: ^{1,2} Faculty of Medicine University of Maribor ^{3,4} University Medical Centre Maribor

Contact: anjapintaric89@gmail.com

ORCID: Anja Pintarič 0000-0001-9823-5411, Monika Sobočan 0000-0003-1384-9487

Key words: conization, postoperative complications, intrauterine devices, contraceptives

Introduction. The World Health Organisation's guidelines for the treatment of cervical intraepithelial neoplasia (CIN) stage 2+ lesions recommend the use of cryotherapy, loop electrosurgical excision procedure (LLETZ) or cold knife conisation over no treatment. Surgery, however, bears the risk of complications and can cause a great deal of discomfort in patients. We decided to investigate the differences in clinical outcomes (complications) after conisation among patients using different forms of contraception. **AIM.** We studied the impact of oral (OC) or intrauterine (IUD) contraceptives on postoperative complications. **Patients and methods.** This retrospective, cross-sectional study included 1,898 patients, 1,470 IUD/OC users. Patients undergoing conisation were prospectively asked to monitor their wellbeing following the surgery using a standardised questionnaire. They returned the report form to their physician during the postoperative follow-up visit, four to six weeks after the conisation took place. Data on reports of patients' post-operative complications, including bleeding, discharge and pain, were tested. Patients classify their complications as: 0-none, 1-mild, 2-moderate or 3-severe.

Results. The comparison of OC/IUD users to no users showed significant differences between the experiences of postoperative pain in the cold knife ($p=0,027$) and LLETZ ($p=0,035$) groups. When comparing IUD to OC users, a statistically significant differences for postoperative pain in IUD users were noted in the electrocoagulation ($p=0,043$) and LLETZ ($p=0,003$) groups. Furthermore, discharge and bleeding were also significantly decreased in patients undergoing conization with cold knife or LLETZ

EP27 THE NEUTROPHILS/LYMPHOCYTES RATIO AS MARKER FOR EVALUATION OF DISEASE PROGRESSION OF CARDIAC PATIENTS

Yevgeniya Lukyanova

Institution: Kharkiv Medical Academy of Postgraduate Education, Ukraine

Contact: zeekmail@ukr.net

ORCID: Yevgeniya Lukyanova 0000-0001-9354-9438

Key words: neutrophils/lymphocytes ratio, cardiac diseases progression

Relevance. The increase of morbidity and mortality from cardiovascular diseases in the world stimulates researching of new methods of early diagnosis and assessment of treatment efficacy. In 1998 Garkavi L.H. indicated that course of disease depends on the level of lymphocytes in the blood. Sawant A.C., 2014; Ertuk M. et al., 2014; Feliciano C.P., 2016 studied the possibility of using the neutrophils/lymphocytes absolute ratio as simple and relevant marker of pathologic and critical states progression in the clinic practice. **Objective:** To study the correlation between the change of cardiac patients general state and lymphocytes level in the blood. **Methods.** We analysed a dynamics of clinical blood tests and general state of 19 patients with such diagnoses as: acute coronary syndrome, pulmonary embolism, cardiac angina, arrhythmia, hypertension, diabetes. **Results.** Six patients with lymphocyte levels below 15% at the moment of admission had critical condition. The treatment of transmural myocardial infarction with pulmonary edema and pneumonia lasted more than 12 days (the maximum - 48 days). The lymphocyte levels of three patients did not rise above 15% over time. The neutrophils/lymphocytes ratio was over than 9.5. It indicated the unfavorable prognosis for disease. All patients had the fall of lymphocytes level during the aggravation period. For example, the lymphocytes level of patient K. dropped from 22% to 3%, the neutrophils/lymphocytes ratio was increased by 10 times. The general state of patients with lymphocyte rate over than 20% and the neutrophils/lymphocytes ratio below than 5 was evaluated as moderate with positive dynamics. Our results are consistent with the data of foreign researchers and show the necessity for further research. **Conclusions.** Reducing of the lymphocytes level in the blood and the increase of neutrophils/lymphocytes ratio are predictors of the patient deterioration and disease progression.

EP28 APPROACHING PATIENT DISEASE TREATMENT USING DATA OF CONSUMPTED AND DISPOSED DRUGS IN CROATIA

Ivan Bošnjak¹, Marija Bošnjak²

Institution: ¹ School of Medicine University of Zagreb, Croatia

² Faculty of Pharmacy University of Mostar, Bosnia and Herzegovina

Contact: Ivanbosnjak888@gmail.com

ORCID: Ivan Bošnjak 0000-0002-6251-4539, Marija Bošnjak 0000-0002-5050-0092

Aim: The aim of this research was to study a correlation between groups of consumed drugs using data from Agency for Medicinal Products and Medical Devices - HALMED with prescribed drugs found in pharmaceutical waste by using data from 51 pharmacy in the main city of Croatia, Zagreb.

Methods: Research involved collecting pharmaceutical waste data from 51 pharmacy in Zagreb during one month period from April 14 to May 14, 2014 and data of consumed drugs collected from HALMED for Croatia overall in year 2014. The population of Croatia is Drugs were sorted using Anatomical Therapeutic Chemical Classification (ATC) into different therapeutical groups. After collecting all data we compared which drugs were mostly included in pharmaceutical waste according to drugs that were dominantly consumed in the whole population of Croatia. **Results:** Drugs most often consumed were drugs which affect cardiovascular system, then Nervous system and Alimentary tract and metabolism (Table 1.). Ramipril and amlodipine are most often consumed in first group, diazepam and alprazolam in second and pantoprazole followed by metformin in third group. Considering pharmaceutical waste, out of all collected pharmaceutical waste, 4549 prescribed drugs (72.3%) was found in pharmaceutical waste. Cardiovascular system was predominant (17.8%) with antihypertensive drugs like atenolol and amlodipine. In Alimentary tract and metabolism (14.5%) group ranitidine was found most often followed by insulin and metmorfin. The third group, Nervous system (12.4%), diazepam and alprazolam were most consistently found. By groups in ATC classification some prescribed drugs found in pharmaceutical waste match consumed drugs (Table 2.).

Conclusion: Prescribed drugs found in pharmaceutical waste are in correlation with consumed drugs in 7 out of thirteen groups. This leads to conclusion that patients are not taking therapy as proscribed. Disease treatment can be improved and economic costs reduced.

EP29 ANXIETY AND INVASIVE PRENATAL TESTING

Vignesh Chenna Kannappan

Institution: Division of Pediatric Neurology, Department of Pediatrics, Vinnitsa National Piragov Memorial Medical University, Ukraine

Contact: ivana.paljk@gmail.com

ORCID: Vignesh Chenna Kannappan 0000-0002-6082-8155

Key words: anxiety, amniocentesis, chorionic villus sampling

Introduction. Pregnancy is a unique life experience, but it can also represent a stressful situation. Invasive prenatal testing can raise several expectations and cause anxiety.

Aim. The aim was to examine how pregnant women experienced invasive prenatal testing and the time after it, while waiting for the results.

Materials and methods. The prospective research included women with singleton pregnancy undertaking amniocentesis and chorionic villus sampling. 200 pregnant women were invited to cooperate, of which 166 agreed to participate. To assess anxiety, the self-evaluating scale State trait anxiety inventory-Y was used. A three-part questionnaire was designed, to which pregnant women responded in writing - to the first part before the procedure, to the second part immediately after and to the third part approximately two weeks after the procedure. Afterwards the anxious state was compared to the personal and demographic data of the pregnant women and their indications for invasive prenatal testing.

Results. Pregnant women were more anxious before the procedure than while waiting for the result. Pregnant women who were sent to amniocentesis and chorionic villus sampling because of the age of ≥ 37 years were less anxious. Furthermore, pregnant women who were sent there due to the positive prenatal screening were more anxious than other women. The ones who already had amniocentesis in the past were less anxious than those who undertook the test for the first time. However, there was no measured distinction in anxiety comparing the pregnant women who undertook chorionic villus sampling in the past with those who had not.

Conclusion. Older pregnant women were less anxious about the tests. Pregnant women who were sent there due to the positive prenatal screening were more anxious. Contrary to our expectations, women tend to feel deeper anxiety before the procedures than while waiting for the results.

EP30 THE DIFFERENCE BETWEEN TRIAL OF LABOUR AND ELECTIVE CESAREAN SECTION AMONG TWIN PREGNANCIES

Petra Bukovec¹, doc. dr. Miha Lučovnik, dr. med.², doc. dr. Nataša Tul Mandić, dr. med.³

Institution: ¹Medical Faculty of Ljubljana, Slovenia; ^{2,3} Department of Perinatology, University Medical Center Ljubljana

Contact: 5rabukovec@gmail.com

ORCID: Petra Bukovec 0000-0003-1820-1858

Key words: cesarean section, pH, twin pregnancy, vaginal birth

INTRODUCTION: Twin pregnancy is considered as pregnancy with increased risks and as such remain one of the major challenges of obstetricians. Both vaginal delivery and caesarean section have their own advantages and disadvantages, but due to the lack of randomized studies, the question of the optimal mode of delivery of twins remains unanswered.

AIM OF THE STUDY: The aim of our study was to determine the possible link between the method of delivery and the pH of arterial umbilical blood.

MATERIALS AND METHODS: This is a retrospective study, which includes 318 childbirths, delivered between 1.9.2013 and 1.9.2015 in University medical center Ljubljana, Clinical department of Perinatology. Stillborn twins, those with congenital anomalies and those delivered at < 24 weeks of gestation were excluded. In our study, we compared pH levels of arterial blood of newborns, who were divided into two bigger groups regarding the attempt of delivery: group of newborns delivered by elective cesarean section (102) and trial of labor (216). The latest was further subdivided into three subgroups (152 vaginal delivery of both twins, 60 emergency cesarean section of both twins and 4 combined deliveries). For data analysis, we used univariate analysis and multivariate logistic regression. P-value of < 0.05 was considered significant.

RESULTS: Multivariate logistic regression showed that trial of labor for first born baby does not have higher risks for lower levels of pH (< 7.2) of arterial umbilical blood in comparison to elective cesarean section (odds ratio 1.89; 95 % confidence interval 0.42–8.48). On the other hand, trial of labor for second twin was associated with higher risk for umbilical artery pH < 7.20 (6.93; 1.55–30.94). However, in both cases (twins A and twins B) we did not find increased risks of admission to neonatal intensive care unit (twins A: 1.66; 0.81–3.41; twins B: 1.84; 0.92–3.69).

CONCLUSION: Results of our study show that trial of labor is an independent risk factor for acidosis only in second born twins. However, there is no important correlation between trial of labor and admission to neonatal intensive care unit.

EP31 CARDIAC MRI ASSESSMENT AFTER TOTAL SURGICAL CORRECTION OF TETRALOGY OF FALLOT OVER A 5-YEAR PERIOD

Vitomir Huljev

Institution: School of Medicine University of Zagreb
Contact: vhuljev@mef.hr
ORCID: Vitomir Huljev 0000-0002-0161-0711

Key words: congenital heart disease, magnetic resonance imaging, tetralogy of Fallot

Purpose: To analyze the use of cardiac magnetic resonance imaging (MRI) in evaluation of patients with surgically corrected tetralogy of Fallot (ToF) at the University Hospital Centre Zagreb. **Methods and Materials:** 36 patients (19 males, age range 7-44 years) with surgically corrected ToF underwent cardiac MRI at the University Hospital Centre Zagreb over a 5-year period (2012-2017), and their medical history and cardiac MRI examinations were retrospectively evaluated. We analyzed clinical questions for MRI examination, the impact of MRI result on treatment decision, and the change of cardiac MRI parameters after surgical intervention in selected cases.

Results: A total of 50 cardiac MRI examinations were performed in 36 patients with surgically corrected ToF from 2012 to 2017, 15 (30%) of those scans were follow-up examinations. After clinical and echocardiographic examination, a pediatric or adult cardiologist referred patients to a MRI scan, in most cases asking for specific information, mostly the right ventricular morphology and function (74%), and morphology of pulmonary arteries (52%). In all 50 scans the right ventricular absolute and indexed volumes and function, wall hypertrophy, fibrosis and wall motion abnormalities were evidenced. Furthermore, in all except one case left ventricular volumes and function were calculated. In 41 (82%) scans pulmonary regurgitation was detected, 20 (49%) of them were of at least a moderate value.

Conclusion: Cardiac MRI is the gold standard for quantification of right ventricular size and function, and pulmonary regurgitation in patients with total surgical correction of ToF. Clinicians are being more aware of its benefits, as can be seen in increase of MRI usage in the last two years, 28 (56%) scans were performed in that period.

EP32 INTERVENTIONAL RADIOLOGY IN THE TREATMENT OF METASTATIC LIVER CANCER

Volodymyr Dunaiev, Yuriy Avdosyev

Institution: Department of Surgical Diseases, Operative Surgery and Topographical Anatomy; School of Medicine; V. N. Karazin Kharkiv National University, Ukraine
Contact: vlad.dunayev@gmail.com
ORCID: Volodymyr Dunaiev 0000-0001-8557-4879, Yuriy Avdosyev 0000-0002-2677-4464

Key words: interventional radiology, metastatic liver cancer

In the late twentieth and early twenty-first century, there have been fundamental changes of the diagnostic and treatment algorithms of metastatic liver cancer. However, by the time of disease diagnosis radical removal of metastases is possible only in 20-30% of patients. Nowadays, systemic chemotherapy became the standard treatment for the inoperable patients. The aim of the study is to evaluate of effectiveness of methods of chemotherapy and chemoembolization in the treatment of metastatic liver cancer. We completed the analysis of intra-arterial treatment of 219 patients aged 17 to 82 years, who were treated for metastatic cancer of the liver of different etiology for the period from 2004 to 2017 at the State Institution "Zaytsev V.T. Institute of General and Urgent Surgery of National Academy of Medical Sciences of Ukraine". All intra-arterial interventions were performed with the help of X-ray machine and angiography equipment. The technical success of the target vessel catheterization was 93.5%. Clinical success (by RECIST) of intra-arterial treatment was 86.1% (tumor on CT or MRI is not defined - 10.4%; reduction in tumor size - 29.6%; process stabilization - 46.1%; progression of the process - 13.9% of patients). Progression of the disease after intra-arterial treatment was associated with the development of collateral blood supply to the tumor site from the so-called parasitic arteries. Median survival depending on the number of treatment courses (Kaplan-Mayer estimator) was as follows: 1st year - 11 months, 2nd year - 18 months, 3rd year - 25 months. Average life expectancy - $23,4 \pm 2,6$ months. Factors that influence the effectiveness of intravascular palliative treatment of the patients with metastatic cancer of the liver are the size and type of tumor vascularization, the size of emboli; the number of intra-arterial chemoembolization procedures; development of collateral and parasitic to the tumor site arteries.

EP33 CLINICAL ASPECTS OF CHILDHOOD STROKE

Merey Kemelbekova

Institution: Department of Pediatrics, Asfendiyarov Kazakh National Medical University, Romania

Contact: merei.kemelbekov@mail.ru

ORCID: Merey Kemelbekova 0000-0002-5376-8078

Key words: hemorrhagic stroke, children

Introduction. The variety of etiological factors leading to the development of strokes in young children determines the difficulty of timely diagnosis of strokes in children. Children's stroke is characterized by a high level of early disability and mortality.

Materials and method: We analyzed the materials of the pathologic bureau of Almaty for the period 2014-2016: 17 cases with pathoanatomical diagnosis: "Hemorrhagic stroke". The age of children ranged from 3 days to 10 years. **Results:** Status of children at the time of treatment was extremely difficult due to the symptoms of respiratory failure, cardio-pulmonary insufficiency, intoxication, neurological symptoms: cerebral and focal symptoms. In 5 cases the underlying diseases were intrauterine infections. In 5 cases the underlying diseases were congenital malformations. In 2 cases the underlying diseases were: 1) aplastic anemia 2) gemangioblastoma of the cerebellum. In all these 12 cases, the condition of patients was complicated by hemorrhagic stroke and the cause of death was hemorrhagic stroke. In 5 other cases the underlying diseases were directly nontraumatic subarachnoid hemorrhage. In these cases, the children had intrapartum hypoxia, birth asphyxia, low gestational age, immaturity, coagulopathy. In 7 cases, a discrepancy between the clinical and pathoanatomical diagnoses was revealed: hemorrhagic stroke clinically was appraised as an infection process.

Conclusion: So, we found that hemorrhagic stroke in children often is a complication of intrauterine infections, anomalies in the development of the vascular system, intrauterine hypoxia, birth asphyxia. In the cases, where was a discrepancy between clinical and pathoanatomical diagnoses, most of children were at the age under 2month. They mostly had symptoms of intoxication rather than neurological symptoms, which requires the need for stroke alertness of specialists.

EP34 USE OF CAMELID ANTIBODIES FOR TREATMENT OF NEURODEGENERATIVE DISEASES - A REVIEW

Emina Horvat Velić, Božena Odošašić

Institution: Department of Biology, Faculty of Science, University of Zagreb, Croatia

Contact: ehvelic@stud.biol.pmf.hr

ORCID: Emina Horvat Velić 0000-0002-8861-2719, Božena Odošašić 0000-0002-6959-7891

Key words: antibodies, camelid, monoclonal, therapeutic

Therapeutic antibodies are a type of monoclonal antibodies that have high affinity for bonding to specific molecules and are used for mapping out biochemical reactions step by step. By engineering the specific antibodies to combat many different diseases, molecular medicine can more specifically and individually help patients and more effectively discover ways to treat before thought untreatable conditions, such as Alzheimer's disease. In the case of humans, our antibodies are comprised of two major components, two light and two heavy chains, each unique in its structure and bonding places. However, it has been discovered that camelid antibodies are comprised of only heavy chains. Camelids are the only remaining family of the suborder Tylopoda of which the most notable are camels, llamas, and alpacas. From their antibodies that consist only of heavy chains, the first single-domain antibodies were constructed. These antibodies have shown to be very stable as well as easily obtained from microorganism cultures, yeast in particular. They were shown to cross the blood-brain barrier in limited quantities in mouse models and human brains. David et al. showed in 2014, while using an artificial blood-brain barrier that these camelid antibodies, an anti-prion species of antibody specifically, could cross the said barrier and even irreversibly block the prion activity. As camelid antibodies are smaller in size and very stable, they can penetrate areas that were before inaccessible. So far there were only trials done on mouse brain where the antibodies were able to detect the amyloid plaques, but scientists hope to move this to human trials. There is hope for the future, as antibody altering mechanisms get easier and more accessible, they will shed light onto molecular pathways of neurodegenerative diseases and be specialised diagnostic tools, and even open up a possibility of individually catered antibody therapy.

EP35 AUTOMATIC PLANT WATERING SYSTEM VIA SOIL MOISTURE SENSING BY MEANS OF SUITABLE ELECTRONICS

Nermin Đuzić

Institution: International Burch University Sarajevo; Faculty of Engineering and Information Technologies; Department of Genetics and Bioengineering, Bosnia and Herzegovina
Contact: nermin.djuzic@stu.ibu.edu.ba
ORCID: Nermin Đuzić 0000-0003-1091-1978

Key words: plant, sensor, moisture, system, electronics

Since nowadays, in the age of advanced electronics and technology, the life of human being should be simpler and more convenient, there is a need for many automated systems that are capable of replacing or reducing human effort. Here we introduce one such system, named as automatic plant watering system, which is a model of controlling irrigation facilities that use sensor technology to sense soil moisture with the microcontroller in order to make a smart switching device to help millions of people. Besides obvious benefits and utilities in the field of agriculture, there are also various applications of this system for medical purposes. The fact is that automated vertical farming uses about ten times less water and a hundred times less land than conventional farming and growing the food close to where it's consumed without transporting it large distances contributes to solving the undernourishment as one of the biggest problems worldwide. Farmers from all around the world would be able to automatically and without excessive effort cultivate and breed crops and plantations of these plants that are the most significant, wanted and used nowadays in diet. As another medical solution, there is an option to implement this system in cultivating some plants that are effective in removing air pollutants and also in preventing and reducing respiratory diseases and lung dysfunctions, which contributes to both better air and living quality of individuals. Therefore, using this system people are able to automatically irrigate and cultivate medically significant and famous plants such as medical herbs, weeping fig, ferns, which contribute to the reduction of dangerous, harmful and toxic air pollutants and pesticides like CO, CO₂, formaldehyde, benzene etc. Also, it would make someone able save the money on medicine.

EP36 ACOUSTIC LEVITATION OF THE ENGINEERING OF 3D CORTEX-LIKE CONSTRUCTIONS BY USING PRIMATE NEURAL STEM CELLS

Terezija Mišković¹, Federic Padilla², Florence Wianny³

Institution: ¹Croatian Institute for Brain Research, School of Medicine, University of Zagreb; ²LabTAU Unit 1032 INSERM, Lyon ³Stem Cell and Brain Research Institute
Contact: terezija21@gmail.com
ORCID: Terezija Mišković 0000-0003-1895-3451

Key words: ultrasound, tissue engineering, 3D hydrogel, neuraln construct, cortex neuraln stem cells

Herein we report the construction of in vitro multilayered 3D cortex-like structures. 2D culture models cannot recapitulate the 3-D aspects of neural connectivity or the brain microenvironment, for this fact acoustic radiation forces were used to levitate monkey neural stem cells (NSCs) in 3D multilayered fibrin tissue constructs. To closely mimic the developing cortex layered structure in vivo, three NSC populations, on different stage of differentiation were distinctively levitated in a fibrinogen and thrombin mix. In a single final construct, were present the NSCs at three stages of differentiation: (i) self-renewing NSCs corresponding to brain progenitor cells, (ii) NSC derivatives derived after one and (iii) two weeks of neuronal differentiation, corresponding to immature cerebral cortex neurons NSCs were derived from monkey embryonic stem cells that stably express a tau-GFP fusion protein (2). By binding the GFP to microtubules, tau-GFP tagging enables detailed visualization of living cell morphology, including dendrites and axons. The levitation process was repeated three times to superpose, in a single final construct with an interlayer distance of 180µm. Generated heterogeneous cell constructs were cultured in differentiation media, afterwards they were immunostained and prepared for the confocal microscopy analysis. Immunostaining analyses revealed multilayered organization and cells exhibiting neuronal and glial phenotypes. Furthermore, after 7 days of culture, the cells were still viable and most of them was proliferating. Profound, complex intercellular connections by neurons and glial cells were monitored, as well as extending processes and inter- and intralayer connections between layers of differentiated NSCs. In this way it was confirmed that our 3D hydrogel constructs support cell viability, proliferation, and cell behavior as observed in vivo. Thus, bio-acoustic levitation system provides an excellent platform to create physiologically relevant in vitro neuronal models of the brain, such as the multilayered cortex or the cerebellum. We demonstrate this method is simple, rapid and biocompatible, and can be used towards other applications such as engineering native organs or composing disease models, using patient iPS cells.

STEPP EMERGENCY MEDICINE WORKSHOP

WHO: StEPP

WHEN: Wednesday, April 19, 2017
15:30 - 17:00, CEPAMET



ABOUT WORKSHOP:

StEPP Emergency Medicine Workshop session consists of six parts that are organized as different emergency station. Goal of each station is to learn how to recognize life threatening situations and how to properly react and deal with them.

Our first CPR workshop deals with a person in cardiopulmonary arrest. We teach how to assess a person with a probable cardiac arrest through five different scenarios applying standard protocol in checking vital signs, diagnosing arrest and performing cardiopulmonary resuscitation.

In the Airway workshop, we teach how to assess patency of a person's airway. In case of an obstruction we teach proper ways of opening the airway using different techniques and devices, while also practicing manual ventilation. During this workshop we try to emphasize that airway management is the first and most important step in any form of resuscitation.

Remaining workshops deal with traumatized patients. First we teach how to correctly assess a critical patient by using ABCDE mnemonic and provide initial treatment. During the Immobilization and helmet removal workshop we teach when and how to remove a motorcycle helmet and how to properly immobilize the patient for transport using a spinal board and head fixator.

In Crash victim extrication workshop we focus on how to approach a car crash victim and how to extract an injured person.

Dealing with a wide specter of scenarios and through different roles in the rescue team, these workshops present the attendants with wide specter of medical emergencies and provide the required knowledge in order to properly resolve them.

ORAL HEALTH 101 – COMPREHENSIVE BASICS OF DENTISTRY FOR MDS

WHO: David Geštakovski, Ema Vindiš and
Larisa Musić dr.med.dent.

WHEN: Wednesday, April 19, 2017
15:30 - 17:00, CEPAMET

ABOUT WORKSHOP:

This interactive lecture and workshop is intended for all future medical doctors, guiding them through the basics of dentistry and oral health and giving ready-to-apply knowledge about this least known part of the human body. We've got you covered with a wide variety of conditions in the oral cavity, both physiological and pathological, ranging from the first days of a child's life until late age. They will be presented as real life cases which every medical doctor should know how to identify and understand. Part of the workshop will focus on a major public health problem, two of the most prevalent chronic

infective illnesses worldwide, periodontitis and tooth decay. Our aim is to raise awareness of these mostly overlooked diseases among our medical colleagues, also showing how simple everyday habits can help fight them. We'll apply what we've learned in a hands-on workshop (or should it be tooth-on?), demonstrating something very simple, but very often mistakenly done – fighting one's oral biofilm with a toothbrush, dental floss and interdental brushes. Last but not least, frequently asked questions will be addressed at the end of the workshop. (25-30 participants)

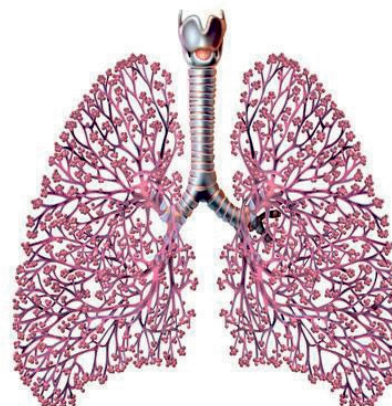
ACID-BASE INTERPRETATION: WORKSHOP

WHO: Students' Pulmology Section

WHEN: Wednesday, April 19, 2017
15:30 - 17:00, CEPAMET

ABOUT WORKSHOP:

Acid-base interpretation is one of essential tools in everyday work of most doctors. Therefore, adequate knowledge considering acid-base interpretation, combined with different pathological entities makes a cornerstone of good medical treatment. Over the 6 years of studying medicine one encounters acid-base interpretation couple of times. The aim of this workshop is to activate and put to practice the knowledge acquired during these 6 years. The workshop will start by revising the basics, proceeding with practical work on real diagnostic examples. It is our wish that the participants of this workshop gain more selfconfidence through independent work.



ECG WORKSHOP



WHO: Students' section of cardiology

WHEN: Thursday, April 20, 2017
15:30 - 17:00, CEPAMET

STUDENTS: Filip Medić, Borna Miličić,
Maja Dupček, Marija Čačić

MENTOR: Dora Fabijanović, MD

ABOUT WORKSHOP:

ECG workshop is a workshop where, in cooperation with cardiologists or cardiology residents, we endeavour to bring closer and educate medical students in the basics of reading ECGs, distinguishing between normal, variant of normal and basic forms of pathological findings. The goal of the workshop is to facilitate students to understand the ECG findings.

The very structure of the workshop consists of an introductory lecture, in which students are given instructions of the basic reading ECG findings, and for each part of the process of ECG reading a theoretical foundation with practical examples. The second part of the workshop consists of working with students within small groups. Each group is given their ECG instructor. Students are given ECG examples and each students analyzes it either individually or with the help of the instructor, and later they discuss about ECG findings.

ABOUT STUDENTS' SECTION OF CARDIOLOGY

Students' section of Cardiology was founded in 2012 by a group of enthusiastic medical students whose intention was to make cardiology more accessible to, not only medical students, but also others interested in cardiology. First president of the section was Gloria Bagadur. Since then, the Students' section of cardiology counts an enviable number of activities - numerous ECG and ultrasound workshops, BLS (basic life support) workshop, surgical knitting workshop, lectures, attendance to various cardiological symposiums and conferences. Our most important project is Kardio dan - an 1-day-event where we envelop all our workshops and students are given the opportunity to attend them all. In 2015 the leadership of the section was given to Petra Radić. In 2016 the new president of the section becomes Marija Čačić.

ULTRASOUND WORKSHOP

WHO: Student surgical society

WHEN: Thursday, April 20, 2017
15:30 - 17:00, ŠALATA 3, NEW HALL

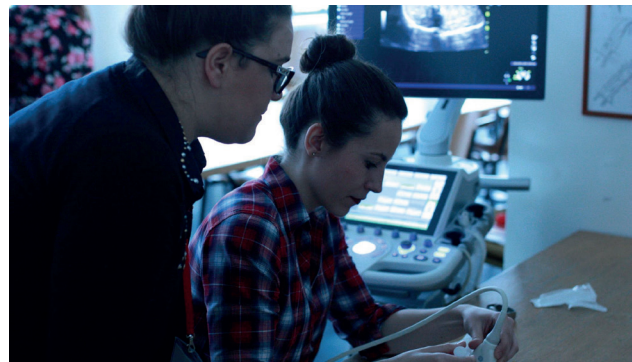
ABOUT WORKSHOP:

Student surgical society kindly invites you to the ultrasound workshop. At the workshop you will all be able to learn basic practical skills of ultrasonography and the theory behind it.

At the beginning you will become familiar with the basic concepts and expressions used in radiological findings such as anechogenic, hyperechogenic and hypoechogenic. How do different tissues look under the ultrasound screening and how can we differentiate them? What are different probes and modes for? How do we orientate the picture?

What does FAST stands for, when and why is it used? Is it ultrasound helpful when we suspect pneumothorax? Furthermore, everybody will learn how to perform FAST scan.

All this and much more is coming up at Cross ultrasound workshop with our great instructor Mislav Čavka M.D., Ph.D., Radiology Consultant, Ultrasound Subspecialist.



PRIMARY WOUND CARE WORKSHOP



WHO: Student surgical society

WHEN: Thursday, April 20, 2017
15:30 - 17:00, Šalata 3, NEW HALL

Friday, April 21, 2017
15:30 - 17:00

ABOUT WORKSHOP:

Student surgical society kindly invites you to the primary wound care workshop. As young doctors we will often come across wounds. But do we really know how to manage wounds? Do we know how to make proper history, examination and access to the wound? On our workshop, you will learn which wounds need special surgical attention, which wounds should and which should not be sutured. What kind of drugs do we use in wound care management and how often do we need to check the wound after the care. Also, we are going to teach you how to suture and show you how to make some basic, most common used knots in surgery.

LAPAROSCOPIC WORKSHOP

WHO: Student surgical society

WHEN: Friday, April 20, 2017
15:30 - 17:00, UHC ZAGREB

ABOUT WORKSHOP:

Student surgical society kindly invites you to the laparoscopic workshop. Laparoscopic surgery is one of the most revolutionary things that happened to surgery in the last decades and has become standard procedures in many surgical branches. By its minimally invasive approach, the surgeons are able to do less tissue damage, which produces less stress response, and the patient recovery is much faster. In this workshop each participant will have the opportunity to learn basic laparoscopic skills. There will be a simulator with a real laparoscope on which precipitants will be able to operate, assist and experience surgery simulation.

Hope to see you there!
Your Student surgical society



CAUSES AND TREATMENT OF HYPOVOLAEMIA IN CHILDREN WORKSHOP



WHO: Student Pediatric Section

WHEN: Friday, April 21, 2017
15:30 - 17:00, ŠALATA 4, CEPAMET

STUDENTS: Ana Matejčić, Jelena Pažur
Marija Štracak, Josip Tica,
Vanja Zvonar

ABOUT WORKSHOP:

At the beginning, workshop will assess fluid balance physiology and its specialty in children. In addition, most common causes of hypovolaemia within paediatric population will be gone through, beginning with their clinical presentation and diagnostics, all over to their management. Paediatric clinical cases will be presented at the end of the workshop.

Predicted duration is 90 minutes.

STUDENTS' SECTION FOR THE PROMOTION OF HEALTHY NUTRITION AND LIFESTYLE WORKSHOP

WHO: Students' section for the promotion of healthy nutrition and lifestyle

WHEN: Friday, April 21, 2017
15:30 - 17:00, CEPAMET



WORKSHOP PROGRAMME:

1. **PROF. ŽELJKO KRZNARIĆ, MD, PhD**



**MEDITERRANEAN DIET AS A GOLDEN
NUTRITION STANDARD, *lecture***

2. **DUNJA LESKOVAR AND IVA LUKAČEVIĆ**

**CHOCOLATE & WINE - "A POWERFUL DUO"
*workshop***

assistant to the moderators: **Laura Pavičić**
mentor: **ASS. PROF. DONATELLA VERBANAC, PhD**


13th International Biomedical
/ CROATIAN STUDENT SUMMIT /

INNOVATIONS

HEALTH

MEET US

ABOUT SCHOOL OF MEDICINE



The University of Zagreb School of Medicine (UZSM/ZSM) is the oldest, most respected and largest institution offering medical studies in the Republic of Croatia. The decision on its establishment was adopted by the Croatian parliament in **January 1917**, which is a precedent in the Croatian higher education. Classes officially started a year later after the inaugural lecture of Drago Perović about the direction of teaching and research in anatomy in the hall of the University of Zagreb. The first professors were appointed, which was followed by the establishment of the institutes: Department of Anatomy, Morphology-Biological Institute, Medical-Chemical Institute, Institute of Physiology, Pathological-Anatomical Institute, Department of General Experimental Pathology and Pharmacology and Public Health Institute. In the period from 1920 to 1922 most of the clinical departments were also established. In 1927, the Zagreb School of Medicine had a total of 17 teaching establishments, among which the oldest was the Sisters of Mercy Hospital, and in 1937 that number increased to 19. Most areas of the Faculty were on Šalata, on the area that was intended for the construction of the entire Medical School. In the academic year 1938/39, the total number of students at the Faculty was 921. After the Second World War, there was a need for more doctors, which in the year 1948/49 resulted in a significant increase in the number of students (2855). Since the academic year 1965/66, the practice of limited registration under the terms of an entry exam is established.

The development of medicine and health care in Croatia is inseparable from the University of Zagreb School of Medicine. Among the distinguished members of the Croatian medicine throughout history, and still today, by far the most doctors who have been or are pro-

fessors come from the Zagreb School of Medicine. For decades, it was the only institution for doctors in our country. In the 1950s, the need for medical studies increased in other parts of Croatia, and an initiative for the establishment of the School of Medicine in Rijeka was started at the Zagreb School of Medicine, which started operating in 1955. Medical studies in Split and Osijek, were opened as regional branches of the Zagreb School of Medicine in 1979, but they became independent in 1997 (Split) and 1998 (Osijek). The Dental School of Medicine in Zagreb became independent in 1962, and in 1997, the Health Studies were dissociated. Since the beginning of the 1990s, the Faculty has undergone significant changes. One of the most significant was the transition from five to six years of study. In the academic year 1990/91, the first generation of students for the teaching program of six years of study was enrolled, the new curriculum was accepted, and subjects were introduced in the sixth year of study that integrate previously acquired knowledge, optional courses throughout the study based on problem solving and innovations in teaching methods and verification of acquired competences. In 2002/03, courses organized in blocks were also implemented in preclinical subjects.




ABOUT UNIVERSITY OF ZAGREB



The University of Zagreb is the oldest and biggest university in Southeast Europe. As a comprehensive public Central European university, University of Zagreb offers education and research in all scientific fields (arts, biomedicine, biotechnology, engineering, humanities, natural sciences and social sciences) and a broad spectrum of courses at all study levels, from undergraduate to postgraduate. With 29 Faculties, 3 Art Academies and the University Centre for Croatian Studies it is the flagship educational institution in the country, a place where more than 7900 teachers and 72480 students develop knowledge and acquire skills.

History of the University began on September 23, 1669, when the Holy Roman Emperor Leopold I issued a decree granting the establishment of the Jesuit Academy of the Royal Free City of Zagreb. Bishop Josip Juraj Strossmayer proposed to the Croatian Parliament in 1861 founding of a University. Emperor Franz Joseph signed the decree on the establishment of the University of Zagreb in 1869. On October 19, 1874, a Royal University of Franz Joseph I was official opened.

The University excels not only in teaching, but also in research, contributing with over 50 percent to the annual research output in Croatia and 80 percent of scientific productivity of all Croatian universities. The central strategic issue of the future development of the University of Zagreb is for it to be a research oriented institution with teaching of high quality. Accordingly, the focus will be on master and doctoral programs, encompassing all fields of science and art, boosting transdisciplinarity and interdisciplinarity as well as translational research, nurturing the culture of innovation and transfer of knowledge. This should result in better intersectorial harmonization on local and regional levels.



ABOUT ZAGREB



Zagreb is the capital city of the Republic of Croatia and the largest city in the country. It represents its country's economic, cultural and scientific centre. Zagreb is situated along the Sava river, at the southern slopes of Medvednica mountain. Since the city is located in the northwest of the country, next to the Slovenian and the Hungarian borders, it is a key traffic point in this part of the continent. Zagreb is commonly referred to as the city where Central Europe, the Mediterranean and Southeast Europe meet.

The city grew from two settlements on neighbouring hills, Gradec and Kaptol, which form the core of today's Zagreb and its historic centre. Zagreb is especially known for its many cultural sites. Ban Jospip Jelačić Square is the heart of the Croatian metropolis. Kaptol and Gradec arise north of it. Kaptol has been the city's religious centre throughout its history, while Gradec was always considered the more secular part of town. The latter continued to become the country's political centre, where on St. Mark's Square the most important governmental buildings can be found. These include the Croatian Par-

liament, the Constitutional Court of Croatia and "Banski dvori", in which the Croatian Government convenes. Gradec and Kaptol are connected by Tkalčićeva Street, which is best known for its numerous coffee shops and restaurants.

There are lots of beautiful sites to be seen in - green parks, fountains, museums, theatres, cinemas, and so much more! In fact, Zagreb is the city with the most museums per capita in the world. Student life also flourishes in the city. Its rich nightlife and lots of events offer a little something for everyone's taste.



ABOUT CROATIA



The Republic of Croatia is a European country situated between Central Europe, Southeast Europe and the Mediterranean. It shares its land borders with Slovenia, Hungary, Serbia, Bosnia and Herzegovina, Montenegro, and also borders Italy (by sea). The capital city of Croatia is Zagreb.

Croatia covers 56,594 square kilometres and has diverse, mostly continental and Mediterranean climates. The country's population is 4.2 million, most of whom are Croats. The country was first established in the 8th century and has since gone through many different name and territorial changes, the last of which was in 1991, when Croatia declared its independence. Croatia has been a member of the EU since July, 2013.

Thanks to its convenient location, Croatia's terrain is very diverse, ranging from the flat plains of Slavonija in the east, through the hilly northern parts of Hrvatsko Zagorje, to the Dinaric Alps, a mountain chain with the country's highest point (1,831m). These mountains are in close proximity to the coast, making them a sight to be seen.

The country's Adriatic Sea coast contains more than a thousand islands. Croatia's coast, excluding the islands, is 1,777km long. That length measures over 6,000km with the islands included. This beautiful coast has already attracted many tourists from all over the world to come and visit Croatia.

Tourism plays an important role in Croatia's economy. It accounts for up to 20% of Croatian GDP. The bulk of the tourist industry is concentrated along the Adriatic Sea coast and most of the tourists visit in summer. Besides its sea, Croatia has lots of other areas that need to be seen. It has eight national parks, most famous of which is the Plitvice Lakes National Park – a string of 16 smaller and larger lakes with crystal blue and green water, situated in the central part of the country.

As of lately, continental parts of the country have become increasingly popular and groups of tourists can be seen throughout the year, especially in Zagreb.



CROSS PARTNER CONGRESSES



Annual International Medical Students Meeting



International Medical Students' Conference (IMSC)



ICMS - International Congress of Medical Sciences



Student Scientific Research Club International Medical Students' Research Congress



Indonesia International (Bio)Medical Students' Congress

Indonesia International (Bio)Medical Students' Congress



International Meeting on Emerging Diseases
and Surveillance - IMED



In4Med

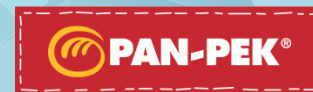

Yes Meeting | Young European Scientist Meet-
ing



The Young Scientists Council (YSC)

DONATIONS



INDEX OF AUTHORS

- Alikadic Nadja : C22
Alsardih Laidh: EP11
Antunović Marko: EP6, EP15, EP16, EP18, EP20
Anzic Ajda: C1, C2, C23
Arko Darja: EP26
Avdosyev Yuriy: EP32
Bakić Ljubica: EP5, EP13
Bandić Pavlović Daniela: EP2
Barović Marko: EP5, EP13
Batagelj Nevenka: C29
Berce Vojko: EP25
Blagajić Mariana: EP24
Bosić Martina: EP5, EP13
Bošnjak Ivan: EP28
Bošnjak Marija: EP28
Brguljan Hitij Jana: C8, C39
Bubalo Petra: EP3
Bukovec Petra: C13, EP30
Buterin Iva: EP3
Cerek Andreja Cerne: C23
Colnatic Jure: C31, C32, C33
Dilber Daniel: C26
Dolenc Primož: C8, C39
Dominiković Ana: C14
Drmić Željka: C37
Drobnič Matej: C28
Dujmović Dora: C37
Dunaiev Volodymyr: EP32
Đuzić Nermin: EP35
Fabijanić Tea: C26
Fadljević Martina: EP23
Fokhrul Abu Talha Bin: C24, EP22
Gašpar Sandro: C34, C35
Gojković Slaven: EP9, EP10, EP20, EP21
Gregorič Nadan: C21
Hamady Ibrahim Maiga: C8, C39
Hegy Peter: EP11
Herič Tjaša: C21
Hiršel Rebeka: C15, C16
Hižar Iva: C34, C35
Horvat Velić Emina: EP34
Hostnik Andrej: C3, C4
Huljev Vitomir: EP31
Janša Jošt: C9, C17
Jerman Anže: C5
Jurov Iva: C25
Kannappan Vignesh Chenna: EP1, EP29
Kariž Stojan: C29
Kavčič Sara: C25
Kemelbekova Merey: EP33
Kendžel Romana: C14
Kliček Robert: C34, C35
Kopač Cene: C6, C7, C30
Košnik Mitja: C38
Krezić Ivan: EP8, EP9, EP10, EP20, EP21
Kurent Urban: C22
Letilović Tomislav: C36
Lučovnik Miha: EP30
Lukyanova Yevegnya: EP27
Madunić Marina: EP7, EP8, EP15, EP17, EP18, EP19
Malekinušić Dominik: EP6, EP17
Maleth Jozsef: EP11
Marjanović Benjamin: C6
Miklič Bublic Martina: EP2
Mikuš Mislav: C27, C36
Milić Anastasija: EP5, EP13
Mišković Terezija, EP35
Mlakar Manca: C18, C19, C20

Molnar Reka: EP11
Možina Teja: C18, C19, C20
Munira Sirajum: C24, EP22
Novič Lana: C8, C39
Odobašić Božena: EP34
Perčin Luka: C27, C36
Perić Luka: EP12
Petraović Damir: C27
Pintar Špela: EP4
Pintarić Anja: EP25, EP26
Plut Domen: C5
Poznić Ema: C12
Preložnik Irena: C11
Pulanić Dražen: C14
Pušeljić Nora: C12
Pušeljić Silvija: C12, EP12
Radanović Igor: EP23
Rusan Matija: EP7, EP18, EP19
Salobir Barbara: C3, C30
Samara Mirjam: EP9, EP10, EP14, EP15, EP16, EP21
Skarlovnik Ajda: C1
Sobočan Monika: EP26
Starić Kristina Drusany: C13
Šparovec Rok: C9, C17
Švitek Luka: EP12
Takač Iztok: EP26
Tasić Jerneja: C7
Tomić Lucija: C27
Tudor Katarina Ivana: C27
Tul Mandić Nataša: EP30
Urbancić Rovana Vilma: C2
Vranješ Davorka: C27
Vrdoljak Borna: EP14
Zekan Paulo: EP24

Zore Andrej: C13
Župan Igor: C4
Župančić-Šalek Silva: EP3
Žaler Dora: EP7, EP8, EP14
Žargaj Anja: C38
Žgela Kristina: EP2
Živković Marta: C36
Žlak Nik: C28
Župan Igor: C10
Župan Matej: C10, C11

