



# LIJEČNIČKI VJESNIK

GLASILO HRVATSKOGA LIJEČNIČKOG ZBORA  
THE JOURNAL OF THE CROATIAN MEDICAL ASSOCIATION  
Utemeljen 1877.      Founded 1877

# Body & Mind

25<sup>th</sup> - 28<sup>th</sup> April, 2023



**18<sup>th</sup> International Biomedical  
Croatian Student Summit  
University of Zagreb School of Medicine**


# LIJEČNIČKI VJESNIK

THE JOURNAL OF THE CROATIAN MEDICAL ASSOCIATION

Founded 1877



<https://lijecnicki-vjesnik.hlz.hr/>  
<https://hrcak.srce.hr/lijecnicki-vjesnik>



UDK 61(061.231)=862=20

Liječnički vjesnik indexed or abstracted in: Scopus, EMBASE/Excerpta Medica, EBSCO, Hrcak, DOAJ, CrossRef

Liječnički vjesnik printed edition ISSN 0024-3477

Liječnički vjesnik online edition ISSN 1894-2177

Founder and Publisher  
CROATIAN MEDICAL ASSOCIATION

For Publisher  
ŽELJKO KRZNARIĆ

Editor-in-Chief  
BRANIMIR ANIĆ

Secretary of the Editorial Board  
Željko Ferenčić

Secretary of the Editorial Office  
Draženka Kontek

## ADVISORY BOARD

### President

Mladen Belicza

### Members

Nada Čikeš (Zagreb) – Hedviga Hricak (New York) – **Miroslav Hromadko** (Zagreb) – Mirko Jung (Zürich) – Ivica Kostović (Zagreb) – Ante Padjen (Montreal) – Marko Pečina (Zagreb) – Dinko Podrug (New York) – Miljenko Pukančić (Sydney) – Smiljan Puljić (Upper Saddle River, New Jersey) – Berislav Tomac (Hagen) – Marko Turina (Zürich)

## EDITORIAL BOARD

Branimir Anić (Zagreb) – Anko Antabak (Zagreb) – Branka Aukst Margetić (Zagreb) – Alen Babacanli (Zagreb) – Ivan Bojanić (Zagreb) – Boris Brkljačić (Zagreb) – Venija Cerovečki (Zagreb) – Mislav Čavka (Zagreb) – Željko Ferenčić (Zagreb) – Božo Krušlin (Zagreb) – Martin Kuhar (Zagreb) – Julije Meštrović (Split) – Mislav Planinc (Zagreb) – Dražen Pulanić (Zagreb) – Duje Rako (Zagreb) – Željko Reiner (Zagreb) – Zdenko Sonicki (Zagreb) – Davor Štimac (Rijeka) – Adriana Vince (Zagreb) – Miroslav Župčić (Rijeka)

## INTERNATIONAL EDITORIAL BOARD

Jurgen Deckert (Würzburg, Germany) – Patrick Erik Eppenberger (Zürich, Switzerland) – Michael Fuchsjaeger (Graz, Austria) – Primož Gradišek (Ljubljana, Slovenia) – Andrej Grajn (Manchester, UK) – Emir Q. Haxhija (Graz, Austria) – Tomas Jovaisa (Kaunas, Lithuania) – Jamin Kashwa (London, UK) – Živko Steven Pavletić (Bethesda, USA) – Semir Vranic (Doha, Qatar)

Zagreb 2023

Printed by

PRINTERA grupa – Franjo Tuđman street 14, Sveta Nedelja, Croatia

Edition

500 copies

## Description

The Croatian Medical Association started publishing its professional journal *Liječnički Vjesnik* in 1877. *Liječnički Vjesnik* is one of only about a hundred international journals that were coming out in the late 19<sup>th</sup> century, maintained continuity during the 20<sup>th</sup> century, and then entered the 21<sup>st</sup> century. It is also the oldest Croatian medical journal and regularly captures all important achievements, professional and trade events. Editorials, professional and scientific papers, review articles, patient reviews, medications and methods, preliminary scientific and expert papers, reviews, letters to the editor, book reviews, literature papers and other contributions are published in the journal *Liječnički Vjesnik*. Through publishing original scientific and professional papers by local authors, *Liječnički Vjesnik* has contributed to the overall health care improvement. All manuscripts are subjected to a review process. All articles should be addressed to the Croatian Medical Association, Office of Liječnički Vjesnik, Zagreb, Šubićeva 9, tel. (01) 46-93-300, e-mail: [lijecnicki-vjesnik@hlz.hr](mailto:lijecnicki-vjesnik@hlz.hr).

MEMBERSHIP AND SUBSCRIPTION: Membership, subscription or any other cash dispatches should be sent to the Croatian Medical Association, Zagreb, Šubićeva 9, Croatia. Bank account: HR7423600001101214818, VAT number HR60192951611. The membership fee for the Croatian Medical Association is 30 euros. The membership fee for the family member is 15 euros. Subscription fee for *Liječnički vjesnik* is 42 euros (84 euros). Members and other legal entities are advised to inform Croatian Medical Association – Editorial Board of Liječnički Vjesnik about any change of address in order to receive the journal regularly. Each member of the Croatian Medical Association is allowed to publish the article in the journal *Liječnički vjesnik* for free. Non-members are also allowed to publish the article with administration fee in amount of 27 euros + VAT.

Printed in Croatia



Author's. Published by: Croatian Medical Association.

All articles are freely available under the terms of the Creative Commons Attribution-NonCommercial-NoDerivates 4.0 International Licence. This license allows others to download works and share them with others as long as they credit you, but they can't change them in any way or use them commercially. <https://creativecommons.org/licenses/by-nc-nd/4.0/legalcode>



# BOOK OF ABSTRACTS

## BODY & MIND



**APRIL 25 – 28, 2023**

**Croatian Student Summit 18**

*University of Zagreb School of Medicine*





**18th International Biomedical  
Croatian Student Summit**

**Zagreb,  
April 25-28, 2023**

**EDITOR-IN-CHIEF**

Emio Halilović  
Aurora Vareško  
Dino Žujić

*School of Medicine, University of Zagreb*

**PUBLISHER**

University of Zagreb  
School of Medicine  
Šalata 3, Zagreb, Croatia

**FOR PUBLISHER**

Slavko Orešković, MD, PhD  
*School of Medicine, University of Zagreb*

# BODY & MIND

## TABLE OF CONTENTS

4	COMMITTEES	13	ABOUT THIS YEAR'S TOPIC
5	GENERAL INFORMATION	14	SCIENTIFIC PROGRAMME
6	RULES FOR SUBMISSION	33	ABSTRACTS
7	WELCOME TO CROSS 18	104	AUTHOR INDEX

# Committees

## ORGANISING COMMITTEE

Dino Žujić, *President*

Lazarela Cuparić, *Vice President*

Matija Martinić, *Vice President*

Petra Bašić

Zoya Jelovečki Đokić

Morana Belović

Ema Kazazić

Dora Cesarec

Vinka Potočki

Marina Dasović

Paulo Rinčić

Vinko Michael Dodig

Dora Softić

## COORDINATING TEAM

Robert Katinić

Mia Šelović

Lucija Lučev

Mirko Vilibić

Iva Šarac

Franka Vrtiprah

## DESIGN TEAM LOGISTICS TEAM

Manuela Frančić

Jakov Markić

Leonarda Maria Šitum

Adrijan Repušić

Martina Vidović

Mia Vukosav

## FUNDRAISING TEAM

David Preložiček

Stella Sara Worman

Karlo Tikvicki

Josip Živković

## SOCIAL MEDIA TEAM

Lucija Dobrić

Ivna Tomaš

Dea Maras

Ivica Zec

Morena Surać

## SOCIAL PROGRAMME TEAM

Laura Rudelj

Julija Žanetić

Lucija Trutina

Ana Žibrat

Josipa Vlahović

## TASK FORCE

Adriana Adamović

Mirela Kolak

Svea Anušić

Maša Mitrović

Lukrecija Anžić

Mara Močibob

Petra Banovec

Jelena Rukavina

Lea Belošević

Matilda Sabljak

Lucija Bešker

Rahela Šafarić

Luka Hanulak

Erna Šarić

Luka Horvat

Terezija Šobloher

Jana Jelčić

Dunja Tadić

Marina Karin

Vedran Vuglić

Terezija Knežević

Emanuela Žuna

## SCIENTIFIC PROGRAMME COMMITTEE

Emio Halilović, *President*

Karla Lužaić, *Poster Session Chair*

Gracia Grabarić, *Workshop Chair*

Đidi Delalić, *Poster Session Review Board Chair*

Marin Cvitić

Sebastijan Trifunović

Matej Dobrošević

Irena Valek

Luka Mitar

Aurora Vareško

Eva Stanec

Lea Župan

Matija Vid Prkačin, M.D.

Goran Ivkić, M.D., PhD

Grgur Salai, M.D.

Professor Robert Likić,

Tomislav Smoljo, M.D.

M.D., PhD

Asst. Professor Jure

Samardžić, M.D., PhD

Maja Baretić, *ex-officio member*

Marijana Braš, *ex-officio member*

Iva Dediol, *ex-officio member*

Vida Demarin, *ex-officio member*

Vesna Gall, *ex-officio member*

Marija Gomerčić-Palčić, *ex-officio member*

Hrvoje Handl, *ex-officio member*

Bojan Jelaković, *ex-officio member*

Tihana Jendričko, *ex-officio member*

Agata Ladić, *ex-officio member*

Mirella Lasić, *ex-officio member*

Davor Miličić, *ex-officio member*

Daniel Milošević, *ex-officio member*

Lucia Sekulić, *ex-officio member*

Katarina Skopljak, *ex-officio member*

Domagoj Vidović, *ex-officio member*

Darija Vranešić Bender, *ex-officio member*

Jurica Vuković, *ex-officio member*

## ORGANISED BY



STUDENT COUNCIL OF  
SCHOOL OF MEDICINE,  
UNIVERSITY OF ZAGREB



SCHOOL OF MEDICINE,  
UNIVERSITY OF ZAGREB

CROATIAN MEDICAL  
ASSOCIATION



# General Information

## VENUES

University of Zagreb, School of Medicine, Šalata 3  
Croatian Institute for Brain Research (CIBR), Šalata 12

## GUEST ATTENDANCE POLICY

All event activities (including workshops and meal functions) are exclusively reserved for registered attendees. Non-registered guests (including children, family members, colleagues, etc.) are not allowed in any of the event areas. Badges provided at registration are required for entrance into all functions and will be strictly enforced.

## REGISTRATION DESK

Registration desk will be open as follows:

Tuesday, April 25: 11:00 - 17:00

Wednesday, April 26: 8:00 - 14:00

Thursday, April 27: 8:00 - 14:00

Friday, April 28: 8:00 - 14:00

Our team will gladly assist you even if the registration desk is closed so please do not hesitate to contact us via email, social media, or your contact person.

## SOCIAL MEDIA

You are invited to follow CROSS 18 on the social media for updates and news, to share experiences and practices, or to simply ask for opinions.

Don't forget to use the hashtag #CROSS18 to share your experience at CROSS 18!

## LIABILITY AND INSURANCE

The Summit Organising Committee and School of Medicine cannot accept liability for personal accidents or loss of or damage to private property of participants. Participants are advised to take out their own personal travel and health insurance for their trip.

## CERTIFICATE OF ATTENDANCE

Certificates of attendance will be distributed via email. You will get your Certificate on the email address you entered while purchasing your ticket; it may take up to 15 days after the conclusion of the Summit for you to get your Certificate.

## PUBLIC TRANSPORTATION

The main building of the School of Medicine is located very near the city centre and as such is easily accessible by public transportation. Several tram lines make a stop at Draškovićevo (4, 8, 11, 12, 14), which is the closest stop from the main building. More information on our local public transportation network can be found at: <http://www.zet.hr/en>

## POSTER ORAL PRESENTATIONS

Posters specifically chosen by the Scientific Programme Committee will be discussed during the Poster Sessions. These posters do not require printing or production of materials –

as your work will be presented electronically. Posters will be available at the Poster stations at the Summit and in an online archive for one year following the Summit. Viewers will be able to easily find and browse and download the posters in PDF format when permitted by the presenter. Each poster presentation should be about 5 minutes long. During the Summit the Scientific-Programme Committee will ask questions following the evaluation of your presentation.

## EVENTS

We will host a number of events you may attend while at CROSS 18. Buffet dinner and networking reception will be held at the School of Medicine in front of Čačković conference hall on Tuesday, April 25, 19:05 - 20:05. Gala dinner will be held on Thursday, April 27 starting at 21:30. Before attending a social event, you must apply for the event. Application links will be sent out to participants via email.

NETWORKING EVENT - Pub Medvedgrad, Ilica 49  
Tuesday, April 25, 21:30

ZAGREB ZOO - Maksimir Park  
Wednesday, April 26, 9:00 - 11:00

BOTANICAL GARDEN ZAGREB - Marko Marulić Square 9a  
Wednesday, April 26, 9:00 - 11:00

MAKSIMIR WALK - Maksimir Park  
Wednesday, April 26, 11:00 - 13:00

ZAGREB 80'S MUSEUM - Radićeva 34  
Wednesday, April 26, 11:00 - 13:00

PUB QUIZ - Bustan bar, Varšavska 8  
Wednesday, April 26, 21:00

TRIP TO MEDVEDGRAD  
Thursday, April 27, 9:00 - 13:00

ZAGREB SIGHTSEEING TOUR  
Thursday, April 27, 9:00 - 11:00

ZAGREB CITY MUSEUM - Opatička 20  
Thursday, April 27, 11:00 - 13:00

AstraZeneca WORKSHOP - Petračića 4  
Meeting point at School of Medicine, University  
Friday, April 28, 9:00 - 13:00

CROSS 18 AFTER PARTY powered by BELUPO  
The Best Club, Jarunska 5  
Friday, April 28, 22:30



# Rules for Submission

## GENERAL RULES

All abstracts and e-posters must be submitted in English.

The CROSS Scientific Programme Committee will review all abstracts. Following the information regarding acceptance, scheduling information will be sent to the abstract submitter.

The CROSS Book of Abstracts will include plenary lectures, all accepted and presented e-poster presentation abstracts, as well as workshop abstracts.

All abstracts must be submitted and presented in clear English with accurate grammar and spelling of a quality suitable for publication.

Abstracts containing a large number of grammatical and spelling errors will not be accepted. Abstracts have to be original and must not have been published or presented at any other meeting prior to CROSS. Abstracts containing updated information or modified data to previously published or presented abstracts will not be considered or accepted for presentation.

Please note that each person may submit up to 1 abstract as a first author. No more than 1 abstract will be accepted for each individual first author. Furthermore, participants are allowed to be co-author on a maximum of 2 abstracts. The latter does not apply to mentors. One abstract may contain 1 first author and 3 co-authors. The latter does not include mentors.

Upon submission, the Abstract Submitter confirms that the abstract has been previewed and that all information is correct, accepts that the content of this abstract cannot be modified or corrected after final submission and is aware that it will be published exactly as submitted. Submission of the abstract constitutes the author's consent to publication (e.g. book of abstracts, CROSS website, programs and other promotional purposes).

Presenting authors of the accepted abstracts are required to upload their e-posters for the presentations within the period determined by the CROSS Scientific Programme Committee. Failure to comply with this rule will result in the exclusion of the abstract from the Book of Abstracts.

The Abstract Submitter warrants and represents that he/she is the sole owner or has the rights for all the information and content provided to CROSS 18 ("Organisers"). The publication of the abstract does not infringe any third-party rights including, but not limited to, intellectual property rights. The Abstract Submitter grants the Organisers a royalty-free, perpetual, irrevocable nonexclusive license to use, reproduce, publish, translate, distribute, and display the content. The Organisers reserve the right to remove from any publication an abstract which does not comply with the above.

Upon submission, the Abstract Submitter confirms that the contact details saved in the system are those of the corresponding author, who will be notified about the status of the abstract. The corresponding author is responsible for informing the other authors about the status of the abstract. The corresponding author is responsible for informing the other authors about the status of the abstract.

## ORCID® IDs



ORCID is a nonprofit organization whose mission is to solve the name ambiguity problem in scholarly communication by operating an open-access registry of persistent unique identifiers for individual researchers, and an open and transparent linking mechanism with other ID schemes and research objects such as publications, grants, and patents.



# WELCOME TO CROSS 18!

**APRIL 25-28, 2023**  
Croatian Student Summit 18  
*School of Medicine University of Zagreb*



# WELCOME TO ZAGREB...

Zagreb, the capital and the largest city of Croatia, ranks among the oldest cities in Central Europe but it is also a modern metropolis situated in the northwestern part of the country along the river Sava and beneath the Medvednica mountain. Due to its developed industries, scientific and research institutions and transport connections, Zagreb is also the cultural, scientific and economic centre of the country.

Although the history of Zagreb goes back to the Roman time, the first written reference to Zagreb dates to 1094 when it was divided into two parts: Kaptol with the Zagreb Cathedral and the larger part Gradec. Two parts were united in 1851 by the count (in Croatian “ban”) Josip Jelačić, whose statue today proudly stands on Zagreb's main square, named after the „ban“ himself.

There are many legends about Zagreb however, the most famous one is how Zagreb got its name. A thirsty knight saw a well as he was passing through this area and a local maiden named Manda was standing next to it. He pleaded: “MANDO, DUŠO, ZAGRABI!” (“Manda, sweetheart, scoop some water!”) Today, a small circular fountain called Manduševac is located at Zagreb’s main square, built above a natural spring that provided Zagreb with drinking water until the end of the 19th century.

Zagreb attracts visitors with the lively atmosphere of its streets, numerous coffee shops, restaurants and shopping. For a modern capital, Zagreb has a kind of small-town charm, with an amazing hilltop district of cobblestone streets and squares lit to this day by gas lamps. Prestigious fountains, beautiful park-woods and parks make it also one of the greenest cities in Europe. One of the most remarkable buildings in the city is

Zagreb Cathedral in Gothic style, St. Mark's Church from the 13th century with admirably colourful tiled roof and Croatian National Theatre, neo-baroque Zagreb masterpiece.

With approximately 20 theatres, 30 museums, 58 galleries and art collections (mostly located in the very centre of the city), a great zoo and almost a million inhabitants, Zagreb offers various possibilities to guests of all profiles. The best ways to explore Zagreb are walking through historical streets and observing its hidden beauties, or by using its blue trams, „the blood vessels“ of the city, which pulsate day and night making Zagreb a truly vibrant city. Whether you need some live music at a bar or a good sit-down meal, Tkalčićeva street (or just „Tkalča“ as Croatians call it), should be your first port of call. There is something for everyone - from underground clubs and cafes to creperie, burger bars and high-end restaurants.

Notable Zagreb souvenirs are the tie or cravat, an accessory named after Croats who wore characteristic scarves around their necks in the Thirty Years' War in the 17th century and licitars, honey dough cookies painted with red enamel and decorated with patterns and messages.

Zagreb is also known for its Christmas market which was several times elected as the best in Europe. Streets and squares lit up and offer a unique range of tidbits at their Christmas fair. However, the fun continues through the whole year as festivals of all kinds roll in week after week: coffee and chocolate, street food, art performances, music etc.





# ...AND OUR SCHOOL OF MEDICINE!

School of Medicine at the University of Zagreb was established in 1917. Just 5 years ago, we celebrated our 100th anniversary, which makes our School of Medicine the oldest one in the western Balkan region of Europe. It was founded around the time the Austro-Hungarian empire began falling apart, giving rise to an autonomous State of Slovenes, Croats and Serbs. This independence enabled Croats to expand the University of Zagreb. That is when Milan Rojc proposed the establishment of a medical school to the Croatian parliament. As a result of his efforts and that of many others who came after, Zagreb School of Medicine gave rise to many great doctors. One of the most well-known among them was Andrija Štampar, an especially notable mention in times of the coronavirus pandemic since he established the Public Health service in former Yugoslavia and later created the foundations of the public health system in Croatia. He subsequently went on to head the first Health Assembly in Geneva and wrote the constitution for WHO in 1948. In this brief text, however, examples of the modern life of a medical student at our School are provided with an overview of various extracurricular activities our students engage in.

Besides the classic overwhelming workload characteristic of any medical school our students are able to take part in numerous student organisations as well as having ample research opportunities. Such extracurricular activities enable students to focus on and further explore their fields of interest early on in their medical career. There are 16 student organisations covering numerous medical fields. There are also 2 student magazines active on our campus, *Medicinar* and *Gyrus*, and both are run and published by students. *Gyrus* mostly covers subjects related to the field of neuroscience while *Medicinar* covers a wide range of topics related to both student life and new interesting research in the Medical field. Both magazines provide

students with an opportunity to exercise their writing and publishing skills while providing a great platform for young researchers to publish their work.

Practical work experience is crucial for any young doctor, which is why our student organisations offer various workshops and volunteer work opportunities in hospitals. For example, the Student organisation for Surgery organises courses where students can learn basic stitching techniques. The Student organisation for Pediatrics offers opportunities for students to join and observe the work of paediatricians who are on call in hospitals. Most student organisations invite lecturers to talk about specific topics of interest that students may not have an opportunity to learn about during regular courses in Medical school. Finally, the Student Organisation for Infectology is currently collaborating with hospitals in an effort to gather volunteers to help deal with the coronavirus pandemic.

All in all, the activities described above serve to depict just some of the exciting opportunities that serve to form new generations of young doctors at the School of Medicine in Zagreb.



# Welcome Message

## PRESIDENT OF THE CROSS 18 ORGANISING COMMITTEE

Dear Friends,



It is my great honour and privilege to welcome you all to this year's edition of our beloved congress, Croatian Student Summit. We begin our four day immersive experience into the most complex, inseparable bond between two basic aspects of a human being - the body and mind. This time, for the eighteenth time in a row, young students and doctors are gathered at our School of Medicine in Zagreb to celebrate the beauty of science and medicine.

This year's topic is 'Body and Mind'. Although not a typical topic, I believe that it is one of the most important ones this congress has been centred on. Future generations of doctors need to view their patients as a whole, acknowledging every symptom and listening to every word the patient has to say. This April, we have assembled a programme of some of the biggest names and experts in medicine in this area, with our main goal being for our participants to learn from the best in the game, and to be inspired from their lectures.

CROSS is not only a place to learn from the best medical experts, but also a place to acquire new practical skills by attending our workshop sessions, which are hosted by our motivated and inspiring student societies. You will have the opportunity to go back home with new skills and wonderful memories. Of course, we pride ourselves on the status of an international congress, so we invite you to attend our well thought out and fun social programme, where you will begin networking with your future colleagues and meet people with whom one day you might be exchanging your knowledge and experiences - who knows, you might meet someone and keep in touch for life! And, when it comes to our active participants, they will have an opportunity to present their abstracts, which is a great way to practise presentation skills and it teaches them to stand proudly behind their work, while they answer questions and present their knowledge to their peers.

It is no wonder that CROSS continues to exist for eighteen years in a row. The recipe for success is, in my opinion, the amazing team of people behind the organisation, which is something that I can never emphasise enough. I consider myself extremely lucky to be this year's president and to be able to guide and coordinate these amazing individuals, who worked tirelessly for this congress to happen. Throughout this experience I have also grown and learnt so much. I extend my gratitude to our School of Medicine for supporting us on every step of the way, without the support they showed us none of this would have been possible. I thank every single one of my amazing friends that I've worked with for their loving support and trust, because none of this would have been possible if they hadn't been as amazing.

We've poured our hearts and souls into this congress with one main goal in mind - to educate. After months worth of preparations, careful planning and consideration, we've prepared for you a program which we hope will fulfil all of your expectations and expand your knowledge, leave you wanting more, motivate you and enrich your academic life as well as your personal one with new acquaintances, friendships and memories you will cherish years from now.

There is not much left for me to say, but to wish you a warm welcome and a great stay at our congress. Welcome and enjoy yourselves, as I am sure you will remember CROSS 18 for life!

**Dino Žujić**

*President of the CROSS 18 Organising Committee*



# Welcome Message

## PRESIDENT OF THE CROSS 18 SCIENTIFIC PROGRAMME COMMITTEE

Dear Colleagues and Friends,

On behalf of the Scientific Programme Committee, it is my great honour to wish you a warm welcome to the 18th Croatian Student Summit!

This year, CROSS turns 18 years, and we tried to make this CROSS memorable with its theme, the choice of lecturers, and the organization of workshops and poster presentations! Furthermore, this is one of the reasons why we chose Leonardo da Vinci's drawing, the Vitruvian Man, as the logo of CROSS 18. Although this drawing is a topic in art and architecture, we wanted to map its meaning to our theme of CROSS. Namely, the Vitruvian Man represents a combination of art and science of the Renaissance and a combination of man and nature called by da Vinci "cosmografia del minor mondo". Guided by Da Vinci's words that the human body is one unity, and shaped by nature, we decided to dedicate this year's CROSS to the unity of body and mind. Also, we have a great desire, especially this year, to show all participants how this century's medicine is holistic and that this is the century of psychosomatics, which is often forgotten! This year's CROSS is characterised by lectures that include many branches of medicine, so we are confident that every participant will have something that interests them. Of course, the selection of the best and most experienced lecturers in the field of psychosomatics is often challenging for medical students so I would like to take this opportunity to thank Professor Vida Demarin who was an incredible support and inspiration for me through the whole process of the organization! Personally, it was a great honour and privilege for me to meet and collaborate with Professor Vida Demarin from whom I learned a lot about psychoneuroendocrinology, and I hope that all of you will have the opportunity at CROSS to understand the importance of understanding the unity of mind and body in medicine. Also, I want to thank all of our invited speakers for their goodwill in passing on their knowledge to us and for becoming part of this beautiful story that continues to unfold for the 18th time in a row.



Another core idea of CROSS is to allow students and young medical doctors and scientists to take their first steps in the world of science and to learn from their successes and failures. This year is also a record year because of the number of abstracts submitted and I would like to thank everyone who recognized our Congress as an excellent opportunity to start! The Poster Team of the Scientific-Programme Committee, led by Karla Lužaić, has raised its criteria and introduced, in addition to last year's three assistants from the School of Medicine, three professors into its team so that both participants and student members of the Committee benefit from their experience on poster sessions and continue to grow. Likewise, it would be a shame if I did not mention here our colleague Đidi Delalić, the Poster Session Review Board Chair, who made a special effort to raise the criteria and quality of abstract revisions, and for that I thank him! To make the efforts of the participants see the light of day, we have prepared the very Book of Abstracts that you are holding in your hands. I would like to emphasize that the abstracts of all authors were submitted without the intervention and proofreading of the Scientific-Programme Committee. As the Editor-in-Chief, I am glad that we have continued our collaboration with Liječnički vjesnik, the official journal of the Croatian Medical Association. I express my sincere gratitude to The Editorial Board, Editor-in-Chief Prof. Branimir Anić, M.D., PhD, Secretary of the Editorial Office Draženka Kontek, and our School of Medicine for making this continuing partnership possible!

Last but not least, I have to mention the Workshop Sessions and thank all student sections and professors who responded to our invitation to enable our participants to learn or further improve in practical skills they don't have the opportunity to perform daily. I would like to say a big thanks to the Workshop team, led by Gracia Grabarić, who worked for months to raise the quality of the workshops and provide the participants with a great choice in improving their skills.

So far I have already listed many things that have been prepared for you, but none of this would have been possible without the fantastic members of the Scientific-Programme Committee who have invested their free time to improve the quality of the Congress and to make this CROSS the best so far! They dedicated six months of their free time to make this Congress a success so far, and for that, I thank them and bow to them!

In the end, I always like to emphasize the premise of CROSS. This year, I would like all of us to reject the previous way of experiencing our patients, grow ourselves, and embrace the unity of mind and body, which will help us to better understand others and ourselves.

I wish you a very successful and educational congress!

**Emio Halilović**

*President of the CROSS 18 Scientific Programme Committee*

# Welcome Message

## PRESIDENT OF THE STUDENT COUNCIL



Dear Participants,

On behalf of the Student council of the University of Zagreb School of Medicine, I am delighted to welcome you to the 18th Croatian Student Summit (CROSS), held under the theme “Body & Mind”!

As the president of the Student council, I am proud to say that CROSS is a completely student-led initiative that showcases the creativity, dedication and enthusiasm of our students, and has done so for the past eighteen years! CROSS is a unique event that brings together medical students and young scientists from all over the world to share their passion for research and innovation. It also offers a great opportunity to learn from experts, network with peers, and have fun in the beautiful city of Zagreb. Organizing the Summit is never an easy task but is always a rewarding one. We have worked hard to prepare an exciting and diverse program for you, featuring lectures, workshops and poster sessions. We hope that you will find something that sparks your curiosity and inspires you to pursue your own research projects.

Participating in CROSS is not only about gaining knowledge and skills, but also about making friends and memories. We want you to enjoy your time here and feel at home in our School of Medicine and our beautiful city. And of course, you can not miss our gala dinner, where you can relax, socialize and dance the night away.

As the famous philosopher Descartes once said, “I think, therefore I am”. At CROSS, we want you to think, but also to feel, to act and to be. We want you to experience the body and mind connection in all its aspects and dimensions. We want you to sense the world with us.

Thank you for choosing to be part of this summit. I wish you all a successful and enjoyable CROSS 18!

**Marina Dasović**  
*President of the Student council,  
School of Medicine, University of Zagreb*

# About This Year's Topic

## BODY & MIND

Today's medicine puts forth the unity of the body and soul, also known as the psychosomatic approach. The connection between the psychological and the physical is in itself a reciprocal one - on the one hand, the psychological state affects the occurrence of physiological illnesses (the psychosomatic theory as previously mentioned above) and on the other hand, the body itself affects the mind (also known as somatogenesis). Every disease could be classified as psychosomatic - it's just a matter of proportion.

The concept of the psychosomatic theory and the connection between the body and the mind in the genesis of various diseases dates back to ancient times. The preceding approach was changed by Aretaeus of Cappadocia by introducing and establishing the notion that emotional states influence homeostasis and the outcome of diseases. Throughout the history of medicine and the development of its various different clinical branches, many physicians started speaking out in favor of the possible connection between the psychological and the physical condition, two previously seemingly unrelated components. Today, we are familiar with and accept the biopsychosocial model which describes how the integration of multiple factors (physical and psychological) affects the progress of diseases.

Some of the most common diseases detectable in the practice of a general practitioner are psychosomatic, a research has shown that 60% of patients that contact and visit their general practitioner regarding physical injuries are actually suffering from psychosomatic issues. The treatment of said patients, along with primary and secondary prevention, poses a challenge for physicians.

The acceptance of the disease itself and the process every patient goes through is complex and more often than not requires an interdisciplinary approach. Experts and doctors of different specialities often

have to cooperate and create a treatment plan for the patient. Research concerning various different factors that affect the genesis and the outcome of diseases have been gaining more attention and importance, often mentioning stress and its influence on the disruption of homeostasis; the diseases themselves commonly either progress or the patients relapse, which results in making the treatment more challenging. From general practitioners, through internal medicine doctors, psychiatrists and various other experts, one goal remains the same - curing the patient.

As future doctors, we owe it to our patients to provide them with a thorough, complete examination, taking into account all of their symptoms and properly handling them. The integration of different medical fields is gradually becoming more apparent and important with numerous factors that influence the genesis of diseases while the perplexity of the pathology itself is growing rapidly.

During this year's CROSS, together we'll be diving into the complexities of the psychosomatic and the somatopsychic theory, exploring the connection between the body and the mind through a series of fascinating lectures from the aspects of numerous different medical fields in hopes of remembering an important message - our patients need adequate care which can only be given to them by acknowledging all of their symptoms and providing appropriate support. The future of medicine is integrated medicine, so let us give you a glimpse into the future and all the wonders it holds by attending this year's CROSS.

Dino Žujić



# SCIENTIFIC PROGRAMME

16 AGENDA

19 INVITED SPEAKERS

27 ABSTRACTS LIST



# Special Sponsors

Office of the President of  
the Republic of Croatia



Mayor of Zagreb



Platinum Sponsor

AstraZeneca 

# Tuesday

## APRIL 25th

*School of Medicine, Šalata 3*

**11:00 - 17:00**

**Arrival and Registration**

**17:00 - 17:30**

**Opening Ceremony** Čačković Conference Hall

**Welcome Messages**

**Introductory Plenary Session** Čačković Conference Hall

**17:30 - 18:00**

**Adopting the paradigm shift into clinical practice**

Professor Vida Demarin, M.D., PhD, FAAN, FAHA, FESO, FEAN, FWSO

**18:05 - 19:05**

**21<sup>st</sup> century medicine – challenges and goals**

Professor Vida Demarin, M.D., PhD, FAAN, FAHA, FESO, FEAN, FWSO

Professor Marijana Braš, M.D., PhD

Professor Bojan Jelaković, M.D., PhD, HAZU

Professor Davor Miličić, M.D., PhD, FESC, FACC

**19:05 - 20:05**

**Buffet Dinner**

**21:30**

**Networking Event** Pub Medvedgrad

# Wednesday

## APRIL 26th

**8:00 - 14:00**

**Arrival and Registration**

**8:30 - 10:30**

**Poster Session I** Croatian Institute for Brain Research, Seminar H2 Room

**9:00 - 11:00**

**Botanical Garden Zagreb or Zagreb ZOO visit**

**11:00 - 13:00**

**Poster Session II** Croatian Institute for Brain Research, Seminar H2 Room;

**Zagreb 80's Museum visit or Maksimir walk**

**13:00 - 14:00 Meal break**

**Plenary Session I** Čačković Conference Hall

**14:00 - 14:30**

**Psychodermatological burden of skin diseases**

Iva Dediol, M.D., PhD

**14:35 - 15:05**

**Psycho-oncology: yesterday, today, tomorrow**

Professor Marijana Braš, M.D., PhD

**15:10 - 15:30 Coffee break**

**15:30 - 16:00**

**Psychosomatic medicine in gynecology and obstetrics**

Vesna Gall, M.D., PhD

**16:05 - 16:35**

**Field of pediatrics and a sick child in the 21st century**

Professor Jurica Vuković, M.D., PhD

**16:50 - 19:50**

**Workshop Session I** Mašek, Wickerhauser, Šercer Conference Hall, Computer Room & Croatian Institute for Brain Research

**21:00 Pub Quiz** Bustan Bar

# Thursday

## APRIL 27th

**8:00 - 14:00**

**Arrival and Registration**

**8:30-10:30**

**Poster Session III** *Croatian Institute for Brain Research, Seminar H2 Room*

**09:00 - 13:00**

**Trip to Medvedgrad or Zagreb Sightseeing Tour & Zagreb City Museum visit**

**11:00 - 13:00**

**Poster Session IV** *Croatian Institute for Brain Research, Seminar H2 Room*

**13:00 - 14:00 Meal break**

**Plenary Session II** *Čačković Conference Hall*

**14:00 - 14:30**

**Irritable bowel syndrome and microbiota: special focus on diet**  
Professor Darija Vranešić Bender, BsC, PhD

**14:35 - 15:05**

**Functional gastrointestinal disorders**  
Agata Ladić, M.D., PhD

**15:10 - 15:30 Coffee break**

**15:30 - 16:00**

**Family in the bathroom**  
Hrvoje Handl, M.D.

**16:05 - 16:35**

**Impact of life event stress on patients with COPD**  
Assistant Professor Marija Gomerčić-Palčić, M.D., PhD

**16:50 - 19:50**

**Workshop Session II** *Mašek, Šercer Conference Hall, Computer Room & Croatian Institute for Brain Research*

**21:30**

**Gala Dinner** *Strojarska 20/26<sup>th</sup> floor*

# Friday

## APRIL 28th

**8:00 - 14:00**

**Arrival and Registration**

**08:30 - 10:30**

**Poster Session V** *Croatian Institute for Brain Research, Seminar H2 Room*

**9:00 - 13:00**

**From A to Z Health-Hack AstraZeneca Workshop**

**11:00 - 13:00**

**Poster Session VI** *Croatian Institute for Brain Research, Seminar H2 Room*

**13:00 - 14:00**

**Lunch break**

**Plenary Session III** *Čačković Conference Hall*

**14:00 - 14:30**

**Psychotherapy as a stress modulator – resilience and integration**

Associate Professor Tihana Jendričko, M.D., PhD

**14:35 - 15:05**

**Sleep disorders as risk factors for mental disorders**

Assistant Professor Domagoj Vidović, M.D., PhD

**15:10 - 15:30 Coffee break**

**15:30 - 16:00**

**Stress and the endocrine system**

Assistant Professor Maja Baretić, M.D., PhD

**16:05 - 16:25**

**Start by taking care of yourself**  
Mirella Lasić, M.D., Daniel Milošević, M.psych., Lucia Sekulić, M.D. & Katarina Skopljak, M.D.

**16:30 - 17:00**


**Closing ceremony** *Čačković Conference Hall*

**22:30**

**CROSS 18 After Party powered by BELUPO** *The Best Club, Jarunska Street 5*



# Silver Sponsors





# Invited Speakers

## Assistant Professor Maja Baretić, M.D., PhD

*Division of Endocrinology, Department of Internal Medicine, University Hospital Centre Zagreb  
School of Medicine, University of Zagreb*

**M**aja Baretić MD, PhD is a specialist in internal medicine, consultant endocrinologist and diabetologist working at University Hospital Centre Zagreb, Croatia as well as an assistant professor at the School of Medicine, University of Zagreb. She obtained her medical degree at the University of Zagreb, School of Medicine and received her PhD Degree from the University of Zagreb, Faculty of Science at the Department of Biology. Her main clinical interests are diabetes mellitus and innovative technologies, as well as diabetes in pregnancy, obesity and thyroid disorders. Her research interest focuses on the same subject and she has presented and published a significant number of scientific papers. Currently, she is leading the Croatian Obesity Treatment Referral Centre registered as a Collaborating Centre for Obesity Management of the European Association for the Study of Obesity. She is a member of the Croatian EUGOGO (European Group on Graves' Orbitopathy) team. Dr. Baretić is a Board Committee Member of the Croatian Society of Obesity, Croatian Society of Hypertension and Croatian Society of Rare Diseases.



## Professor Marijana Braš, M.D., PhD

*Center for Palliative Medicine, Medical Ethics and Communication Skills, School of Medicine, University of Zagreb*

**P**rof. Marijana Bras, M.D., PhD psychiatrist-psychotherapist, Head of the Department of Palliative medicine at the School of Medicine University of Zagreb, Head of the Center for Palliative Medicine, Medical Ethics and Communication Skills at the School of Medicine University in Zagreb. She finished postgraduate study of psychotherapy at the School of Medicine University of Zagreb and postgraduate course on biomedicine at the School of Natural Sciences of the University of Zagreb. She has Master Degree in psychotherapy and biomedicine. She has PhD in the field of biomedicine. Special field of interest in her clinical practice are PTSP, psychosomatic medicine and palliative medicine. President of the Croatian Society for Palliative Medicine of the Croatian Medical Association (2009-2013). Founder and head of the course Communication in medicine (4-5th year of School of Medicine), lecturer a at the longitudinal course Fundamentals of Medical Skills (1-6th year); founder and head at the course Palliative Medicine (6th year of School of medicine) . She is member of many national and international organizations ( American Pain Society, European Association for the Communication in Medicine and Healthcare (EACH), American Academy for the Communication in Healthcare, Croatian medical Association, Croatian Psychiatric Association, Croatian Association of Palliative Medicine etc.) Author of 70 scientific papers; editor of 10 books and author of more than 40 chapters in teaching and other books. Member of the International College for the Person-Centered Medicine and lecturer at several international pain and palliative care schools. Member of several national and international scientific projects. President of Zagreb's Institute for the Culture of Health.





### **Iva Dediol, M.D., PhD**

*Department of Dermatovenereology, University Hospital Centre "Sisters of Mercy"*

**I**va Dediol M.D, PhD is consultant at the Department of Dermatovenereology Sestre Milosrdnice, University Hospital Centre. After graduation she was a research associate in a scientific project of Ministry of science, education and sports of the Republic of Croatia called „Psychological status of patients with malignant skin diseases and other dermatoses“ and was teaching Dermatovenereology in Medical high school „Mlinarska“ in Zagreb. In 2017 she obtained PhD with the Thesis „Quality of life and psychiatric comorbidities in symptomatic and asymptomatic dermatovenereological patients“ at The Doctoral Study in Biomedicine and Health Sciences, Medical school,

University of Zagreb. She has done her training in pediatric dermatology abroad in London, UK and Padua, Italy. Apart from her clinical work in psoriasis, she has also been principal investigator in clinical trials in psoriasis and head of School of atopy – educational program for children with atopic dermatitis and their parents at Department of Dermatovenereology Sestre milosrdnice University Hospital Centre. Iva Dediol was a speaker at several international and national scientific congresses, meetings or symposia. She published many scientific articles and abstracts in medical journals and congress abstracts in abstract books. She is also an author of chapters in medical books. She is a member of several medical organisations including European Academy of Dermatology and Venereology, European Society for Pediatric Dermatology, Women’s Dermatologic Society, Croatian Medical Association and Croatian Dermatovenereological Society. Iva Dediol received John Stratigos Memorial Scholarship (EADV) in 2016 and Women's Dermatologic Society International Travel Award 2018.



### **Professor Vida Demarin, MD, PhD, FAAN, FAHA, FESO, FEAN, FWSO, HAZU**

*Department of Medical Sciences, Croatian Academy of Sciences and Arts*

**P**rofessor Vida Demarin, MD, Ph.D., specialist in neuropsychiatry graduated from School of Medicine, University of Zagreb, Croatia. She was Head of Department of Neurology in University Hospital Centre “Sestre Milosrdnice” in Zagreb and from 2015. she is director of International Institute for Brain Health. She authored about 1000 papers in national and international journals, several chapters in books and handbooks, organized and participated in numerous symposia, conferences and congresses. She is a founder and one of directors of Summer Stroke School, “Healthy

Lifestyle and Prevention of Stroke and Other Brain Impairments” within the academic program of Interuniversity Centre in Dubrovnik and the president of traditional Mind & Brain INPC in Pula. She is a member of numerous national and international professional societies and she serves on various scientific Advisory, Editorial and Review Boards. For two years in a row, she was within 2% of the world's scientists with the greatest influence on the profession. Through her professional and scientific work, she has significantly influenced the development of neurology and neuroscience in Croatia and the world, and has established fruitful cooperation with the world's most prestigious institutions, contributing to the WFN motto „There is no health, without brain health“!

CROSS

## Vesna Gall, M.D., PhD

*Delivery department, Clinic for Women's Diseases and Obstetrics, University Hospital Centre "Sisters of Mercy"*



Vesna Gall was born in 1977 in Varaždin Croatia. She graduated from the Faculty of Medicine in 2010. She became a subspecialist in fetal medicine in 2015. She received her doctorate at the Faculty of Dentistry in 2016. Since 2017, she has been the president of the Croatian Society for Psychosomatics in Gynecology and Obstetrics at Croatian Medical Association. She is the head of the Delivery Department at the KBSCM Clinic for Women's Diseases and Obstetrics. She is the author of numerous professional and scientific papers and lectures in various fields of gynecology and obstetrics with an emphasis on psychosomatics in gynecology and obstetrics. Also is the co-author of the book "Psychosomatic medicine in gynecology and obstetrics."

## Assistant Professor Marija Gomerčić-Palčić, M.D., PhD

*Diagnostic and interventional pulmonology clinic, Department of Clinical Immunology, Pulmonology and Rheumatology, University Hospital Centre "Sisters of Mercy" School of Medicine, University of Zagreb*



I was born in Otočac on July 24th 1983. Following graduation from high school -the VIIth Gymnasium in Zagreb, I enrolled at the University of Zagreb School of Medicine in 2001. During my student days, I worked as a student teaching assistant for Pathology class. I graduated university in 2007 and completed the national bar exam in 2008, following a year of internship. From 2008 to 2015 I worked as a scientific assistant on the project of the Croatian Ministry of science, education and sport named "Research into non-alcoholic fatty liver disease in the context of metabolic syndrome", spearheaded by professor Marko Duvnjak, MD, PhD. I started by residency in internal medicine in 2010 and finished it in 2015. I completed my PhD in 2015 and finished my subspecialisation in pulmonology in 2018. I also became head of the Diagnostic and interventional pulmonology clinic, part of the Department of pulmonology in Clinical Hospital Centre "Sisters of Mercy" in Zagreb. I have been a senior assistant for the Department of Internal Medicine at University of Zagreb School of Medicine and have gained the title of assistant professor in 2020. From 2019 onwards I have been the head of the so-called "Quarantine", later renamed to the "COVID-19 centre"(the hospital ward dedicated to the management of patients with COVID-19) in Clinical Hospital Centre "Sisters of Mercy" From 2020 to 2021 I was the physician coordinator for the "Arena" COVID-19 centre. In 2022 I was named head of the Department of pulmonology. Initially my primary interest was in hepatology and gastroenterology, later changed to pulmonology. I have been active in student education at the University of Zagreb School of Medicine since the beginning of my career. I am also a lecturer for the 1st category postgraduate course of continuing medical education named "Abdominal ultrasound". I am a member of several domestic and international physician societies, reviewer for journal and an author or co-author of 10 scientific articles published in indexed journals (6 of which are journals indexed in "Current Contents"), several chapters in three professional books and several congress correspondences. I was part of the organizational committees for several medical symposia. I was awarded the prize for the best poster presentation on three different international congresses. I was a participant of several international clinical and scientific conferences related to gastroenterology, hepatology and pulmonology.

## Hrvoje Handl, M.D.



*Day hospital for eating disorders H(RANA), Clinic for Psychiatry "Sveti Ivan"*


57 years ago I was born as a child of a journalist and of course a doctor in hometown of FC Dinamo. I finished some music school, some high school, medicine, acting academy, specialization in psychiatry, subspecialty in psychotherapy, psychoanalytic education... Or they finished me. I didn't write a lot of papers, but I gave lectures a lot because narcissism dictated it to me. I'm teaching less now, but I'm the proud head of the wonderful day hospital Team for eating disorders called H(rana) for the last nine years. I love Her, my children, my friends and The Team. I don't like social media, catchphrases like "OK," emoticons and plum compote. I am a dedicated follower of observing people and their madness.



## Professor Bojan Jelaković, M.D., PhD, HAZU

*Croatian Academy of Sciences and Arts  
Department of Nephrology, Arterial Hypertension and Dialysis, University  
Hospital Centre Zagreb  
School of Medicine, University of Zagreb*

Bojan Jelaković is a professor of internal medicine at the University of Zagreb's School of Medicine, Head of the Internal Medicine Clinic's Department of nephrology, dialysis and arterial hypertension at the Clinical Hospital Centre Zagreb and the president of the Croatian society of arterial hypertension. He is the leading Croatian hypertensiologist with an impressive international renown and one of the leading european experts and investigators in the field of arterial hypertension. His research on endemic nephropathy have resulted in the complete clarification of its etiology and have thus become part of the history of Croatian medicine. His scientific and publicistic activity and leadership of scientific projects place professor Jelaković at the apex of Croatian clinical medicine science, as well as science in general. He is exceptionally active in the organization of scientific and professional conferences and has been an invited lecturer all over Europe and the globe for years. He is also very successful as a mentor to young scientists and residents. He has published a series of valuable educational texts in important textbooks of internal medicine, nephrology and hypertensiology. He is also characterized by strong ethical principles that he fervently upholds in his professional, scientific and educational work. He was elected as a regular member of the Croatian Academy of Science and Art in 2020.





## Associate Professor Tihana Jendričko, M.D., PhD

*Department of Psychotherapy, University Psychiatric Hospital Vrapče  
Study of Social work, Faculty of Law, University of Zagreb  
School of Medicine, University of Zagreb  
Croatian Psychiatric Association*



Associate professor Tihana Jendričko is the Head of the Department of Psychotherapy at the University Psychiatric Hospital Vrapče. She is an Associate professor in the Study of social work at the Faculty of Law, University of Zagreb. She holds the course Psychotherapy as part of the Postgraduate Specialist Study in Psychiatry at the School of Medicine of the Croatian Catholic University in Zagreb, lectures in the course of Cognitive-behavioral, integrative and systemic psychotherapy as part of the postgraduate specialist study in Psychiatry at the School of Medicine, University of Zagreb. She participates in conducting education in psychodrama psychotherapy and she is a member of the Educational Board of the Center for Psychodrama. She is the author and co-author of several professional and scientific works, she participated in the implementation of several professional and scientific researches and projects. She is an active member of several domestic and foreign professional associations and is the President of the Croatian Psychiatric Association.

## Agata Ladić, M.D., PhD

*Department of Gastroenterology and Hepatology, Department of Internal Medicine, University Hospital Centre Zagreb*



Agata Ladić was born in Zagreb in 1977, where she finished science and math gymnasium, as well as secondary music school. After secondary school, she spent a year in Norfolk, UK, where she served as an assistant in a private school and was educated from the London Academy of Music and Dramatic Art. Upon returning to Zagreb, she obtained her MD in 2002 and started working in University Hospital Centre Zagreb, Department of Gastroenterology and Hepatology in 2004. Since 2014, she is highly involved in the field of functional diseases in gastroenterology and was the first one in the UHC Zagreb to start performing functional diagnostics. She was trained in the UK, Belgium and in the Netherlands, but also attended many courses on this matter. In 2018, she obtained her PhD in bioscience from Medical School Zagreb. Considering a deep gut-brain connection, she is currently being trained in cognitive-behavioural therapy. She also serves as a member of both multidisciplinary cystic fibrosis team in her hospital and of the European Society of Neurogastroenterology and Motility. She is a mother of five daughters and besides medicine is deeply involved in music.

## Mirella Lasić, M.D.

*University Psychiatric Hospital Vrapče*

Mirella Lasić, MD, is a psychiatry resident at the University Psychiatric Hospital Vrapče, educator of psychoanalytic psychotherapy and head of the “Pogled u sebe” project. She graduated from the School of Medicine in Zagreb. During her studies, she was awarded three Rector's awards of the University of Zagreb. She participated in the work of many domestic and international projects and participated in the organisation of several lectures, congresses and conferences. 6 years ago she joined the leadership of the “Pogled u sebe” project, which deals with the promotion of mental health. While in college, she showed great affinity for work in the field of mental health through volunteer work and student collaborations. She has attended many medical congresses and courses and regularly improves her knowledge and skills. Beside psychiatry and psychotherapy, she is a lover of long walks, sea and sun.



knowledge and skills.



### **Professor Davor Miličić, M.D., PhD, FESC, FACC**

*Croatian Academy of Sciences and Arts  
Department of Cardiovascular Diseases, University Hospital Centre Zagreb  
School of Medicine, University of Zagreb*

**D**avor Miličić was born in Zagreb, 1962. He graduated from the University of Zagreb School of Medicine in 1986. He started his medical career at the University Hospital Centre in Zagreb and received PhD from the University of Zagreb in 1990. In 1993, he got a National Board Certificate in Internal medicine, and 2000 in Cardiology. During 1995/6, as a DAAD awardee he was educated at the Cardiology Department, University Hospital Eppendorf, Hamburg, Germany. In 2003 he became an Associate Professor of Internal Medicine and Cardiology at the University of Zagreb School of Medicine, and a Full Professor in 2009. He also served there as a Dean in two mandates, from 2007-2015. Now he is a permanent Fellow /Full Member of the Croatian Academy of Sciences and Arts since 2012, and since 2019 it's Vice President. Professor Miličić's current professional positions are Head of Department of Cardiovascular Diseases at the University Hospital Centre Zagreb, President of The Croatian Cardiac Society and Founding Director of the Croatian Heart Foundation. He is Co-Founder of Croatian Primary pCI Network for patients with acute myocardial infarction, Founding Director of the Croatian Referral Centre for Heart Failure and Heart Transplantation and Founding Director of the Croatian Referral Centre for Intensive and Acute Cardiology. He was active in many bodies of the European Society of Cardiology since many years, including position of a Councillor of the ESC Board 2012-2014. He is a Board Member of HFA-ESC since 2016, where he served as a Chair of the Advanced Heart Failure Committee, and since 2020 was a Chairman of the HFA-ESC Clinical Section, and a Member of the HFA-ESC Executive Board. He is also a current EUROTRANSPLANT Heart & Lung Transplantation Section's National Representative. Professor Miličić regularly participates as an invited speaker on scientific congresses and conferences in Europe and worldwide. He was a Chairman of ten consecutive National Cardiology Congresses and six consecutive ESC Update Meetings, named Cardiology Highlights. He has been a member of Steering Committee/National Coordinator and/or Principal Investigator of more than 20 international RCTs. He is an author/co-author of about 300 publications in extenso, with more than 27000 citations, about 700 abstracts, 4 books (co-editor), 20 articles in international and Croatian textbooks and monographies. He also serves as a National Coordinator for the Specialty in Cardiology and founding Director of the University of Zagreb Postgraduate Studies in Cardiology.



### **Daniel Milošević, M.psych.**

*Protection of Mental Health of Children and Youth, Mental Health and Addiction Prevention Service, Public Health "Dr. Andrija Štampar"*

**D**aniel Milošević is a Master of Psychology who began his internship in the field of school psychology at V. Gymnasium in Zagreb, and continued it in the field of clinical psychology at the Center for Protection of Mental Health of Children and Youth, part of the Mental Health and Addiction Prevention Service at the Teaching Institute of Public Health "Dr. Andrija Štampar" in Zagreb. He is actively involved in volunteering and community work, particularly in the area of youth mental health. He has conducted over fifty workshops in high schools in Zagreb as part of the work of various associations (Brave Phone - Children's House Borovje; European Federation of Psychology Student Associations - Mind the Mind, Better Together; BEA Center for Eating Disorders; International Association of Medical Students Croatia - CroMSIC Zagreb). During his studies at the University of Zagreb, he was a recipient of several Rector's Awards for the promotion of psychology as a science and the promotion of mental health. He is the leader of the youth mental health project "Working on Mental Health - Inside Out". He volunteers as a professional psychologist at the counselling centre of the Iskorak Association. He also engages in research work at the Clinic for Psychiatry of the Clinical Hospital Dubrava.

## Lucia Sekulić, M.D.

*Health Center Karlovac*

Lucia Sekulić is a medical doctor with a keen interest in mental health and psychiatry. She has experience in student exchange organisations and mental health, volunteering in non-profit organisation management, and as a peer educator in mental health workshops. Currently pursuing psychoanalytic therapy education, she is also one of the leaders of the "Working on Mental Health - Inside Out" project. During her studies, she actively participated in international meetings, perfecting her skills and knowledge while actively promoting mental health. She has been awarded three Rector's awards for her community service work in the academic and wider community. Lucia is an active contributor to the Croatian Medical Students Association, where she volunteers, organises student exchanges, symposiums, international meetings, she perfects her organisational skills and promotes mental health.



and education. Through

## Katarina Skopljak, M.D.

*Clinic for Psychiatry "Sveti Ivan"*

Katarina Skopljak, MD is a psychiatry resident at the Psychiatric hospital Sveti Ivan, Zagreb. She finished primary school and gymnasium in Zagreb, as well as the School of Medicine of the University of Zagreb. During her studying, she actively participated in the work of CroMSIC and EMSA, took part in numerous domestic and international projects, was part of organising committees of several conferences and was awarded Dean's Award for socially beneficial work in the academic and wider community. She is one of the founders and part of the leadership team of the project "Pogled u sebe" ("Inside Out") which is actively involved in adolescent mental health promotion. She is currently finishing her education in logotherapy and regularly participates in domestic conferences, education and training. She is passionate about psychiatry, psychotherapy, reading and parenting.



## Assistant Professor Domagoj Vidović, M.D., PhD

*Department of Psychophysiology and Organically Conditioned Mental Disorders,  
University Psychiatric Hospital Vrapče*

Domagoj Vidović was born on January 6, 1976. in Split. He finished elementary school and the Third Mathematical Gymnasium in his hometown, and in 1994 he moved to Zagreb, where he still lives today. In 2000., he graduated from the School of Medicine of the University of Zagreb and in the same year he was employed at the Vrapče Psychiatry Clinic. In the Clinic, he went through a professional path from an intern doctor to the Deputy Director of the Clinic. He received his PhD at the School of Medicine of the University of Zagreb in 2016. He is a subspecialist in biological psychiatry, a certified somnologist, a permanent court expert, and a university master of quality management in healthcare. He is the author of several chapters in books and textbooks, as well as a number of professional and scientific papers, mainly in the field of sleep disorders. For many years he was the treasurer of the Croatian Psychiatric Society, he is the president of the Croatian Apnea Society of the Croatian Medical Association.







### Professor Darija Vranešić Bender, BsC, PhD

*Unit of Clinical Nutrition, Department of Internal Medicine, University Hospital Centre Zagreb*

*Faculty of Food Technology and Biotechnology*

*School of Medicine, University of Zagreb*

**P**rof. Darija Vranešić Bender, BSc, PhD is a clinical nutritionist at the University Hospital Zagreb, Unit of Clinical Nutrition and works as a member of hospital nutrition support team. Her special interest is diet therapy in gastrointestinal diseases. She is the president of Croatian Society of Nutritionists and Dietitians, vice-president of Croatian Society of Clinical Nutrition Croatian Medical Association and member ECPC committee of European Society of Clinical Nutrition and Metabolism (ESPEN). She obtained bachelors degree in biotechnology in year 2000, PhD in field of nutrition in 2005, and Associate Professor status in 2018 at the Faculty of Food Technology and Biotechnology. She teaches diet therapy, nutrition and clinical nutrition at the University of Zagreb Faculty of Food Technology and Biotechnology and Zagreb School of Medicine (regular and study in English language). She participated at several national and international research projects and published number of scientific and professional papers as well as guidelines, textbooks and popular books on nutrition, clinical nutrition and diet therapy.




### Professor Jurica Vuković, M.D., PhD

*Department of Pediatrics, University Hospital Centre Zagreb*

*School of Medicine, University of Zagreb*

**J**urica Vuković, MD, PhD, pediatrician, hepatologist. He is a full Professor, Vice-dean for Postgraduate Studies, University of Zagreb, School of Medicine and Head, Dept of Pediatrics, University Hospital Center Zagreb. Advocate of case-based learning and bedside skills. Author of few papers in medical journals. The most read ones are those dealing with signs and symptoms, and simple clinical problems. Most cited one describes previously unknown mutation causing very rare disease. Whole professional life has passed in-between. Guilty pleasures: science fiction and rock music. Proud father of four, and granddaddy of two.



# Abstracts List

## Basic Science

**BS01** Effect of Pentadecapeptide BPC 157 on Hemodynamic and ECG Disorders Caused by Sotalol in Wistar Albino Rats

*Marjeta Linarić Lipnjak, Matej Lacković, Helen Marie Chiddenton*

**BS02** Effect of Pentadecapeptide BPC 157 on Hypercalcaemia in Rats

*Matej Lacković, Helen Marie Chiddenton, Sara Burić*

**BS03** Effects of Stable gastric pentadecapeptide BPC 157 and osteogenic material on bone regeneration in mandibula

*Andrej Vrdoljak, Petra Horvat, Marjeta Linarić Lipnjak*

**BS04** Hepatoprotective effects of BPC-157 - paracetamol overdose

*Sara Burić, Hrvoje Vraneš, Vlasta Vuković*

**BS05** Histological aspects of Therapeutic effects of Stable gastric pentadecapeptide BPC 157 on stomach perforation

*Petra Horvat, Marjeta Linarić Lipnjak, Matej Lacković*

**BS06** ISOSORBIDE-5-MONONITRATE INDUCED PERIPHERAL AND CENTRAL VASCULAR DYSFUNCTION IN RATS AND TREATMENT WITH STABLE GASTRIC PENTADECAPETIDE BPC 157

*Vlasta Vuković, Hrvoje Vraneš, Luka Kalogjera*

**BS07** Molecular effects of stable gastric pentadecapeptide BPC 157 on psoriasis

*Hrvoje Vraneš, Luka Kalogjera, Ivan Maria Smoday*

**BS08** PENTADECAPETIDE BPC 157 RESOLVES TOURNIQUET INDUCED ISCHEMIA-REPERFUSION INJURY

*Katarina Oroz, Luka Ćorić, Andrej Vrdoljak, Leon Palac*

**BS09** Potential role of peripheral and central vascular failure in neuroleptic, amphetamine and domperidone pharmacodynamics and toxicology.

*Ivan Maria Smoday, Katarina Oroz, Luka Ćorić*

**BS10** Stable Gastric Pentadecapeptide BPC 157 Macroscopic Effect on Haematoma and Swelling in Spinal Cord Injured Rats

*Luka Ćorić, Andrej Vrdoljak, Petra Horvat, Marija Ćorić*

**BS11** The effects of a varying doses of pilocarpine and lithium induced status epilepticus, and treatment with BPC-157

*Helen Marie Chiddenton, Sara Burić, Vlasta Vuković*

**BS12** The effects of pentadecapeptide BPC 157 on the healing of the incisional skin wound in rats

*Luka Kalogjera, Ivan Maria Smoday*

## Case reports

**CR01** Ankylosing spondylitis: how does it affect the quality of life?

*Eva Perak, Valerija Plečko, Antonija Gračanin, Ana Gudelj Gračanin*

**CR02** Association between venous anomaly of the cerebellum and tremor

*Martina Periša, Karla Periša, Srđana Telarović*

**CR03** Bumpy road on a way to diagnose sarcoidosis

*Maro Brbora, Marcela Babić, Marija Gomerčić Palčić*

**CR04** Ovarian thecoma in adolescent – a rare case of hirsutism

*Nika Baldani, Marko Gavrančić, Vita Jugovac, Lana Škrgatić*

**CR05** Brain tumor in the morbidly obese patient: Diagnostic and therapeutic challenges

*Afan Ališić, David Glavaš Weinberger, Božidar Novoselović*

**CR06** Brain-gut axis dysfunction in young athlete with unfulfilled dreams - irritable bowel syndrome

*Karlo Tkalec, Petra Terzić, Adrijan Tiku, Silvija Ćuković-Čavka*

**CR07** Breaking the Boundaries: A Case of Humerus Reconstruction using a Fibula Autograft

*Lovro Mikulić, Lea Hasnaš, Tomislav Sečan*

**CR08** Cardiogenic Shock Necessitating Extracorporeal Membrane Oxygenation In a Previously Healthy Child

*Zara Gumzej, Alan Ćurković, Filip Rubić*

**CR09** Cardiotoxicity caused by gemcitabine

*Marat Gripp, Anastasia Fatyanova, Irina Babkova, Yuri Isaakyan, Ilona Sarukhanyan*

**CR10** CHALLENGING MANAGEMENT OF SEVERE MYOCARDITIS WITH COMPLETE RECOVERY – a case report

*Jelena Koprivica, Jure Samardžić*

**CR11** Congenital intrathoracic hiatal herniation of left-sided abdominal organs in an adult woman

*Krunoslav Budimir, Tomislav Brajković, Valentina Ratkajec, Tajana Pavić*

**CR12** A Case of Severe Epstein-Barr Virus Encephalitis in a Child  
*Barbara Mikuc, Tena Matek, Lorna Stemberger Marić*

**CR13** AN UNCOMMON CLINICAL PRESENTATION OF DIROFILARIASIS IN A CHILD – A CASE REPORT  
*Viktoria Knežević, Ivan Petračić, Anto Pajić, Andro Gliha, Stjepan Višnjic*

**CR14** An unusual case of anemia and intestinal obstruction caused by a benign duodenal tumor  
*Klara Brekalo, Ivan Borlinić, Maja Cvitanović, Tajana Filipec Kanižaj*

**CR15** Approach to Buschke-Löwenstein tumor associated with malignant transformation  
*Patricia Barić, Drago Baković, Antonia Alfrević, Suzana Ljubojević Hadžavdić*

**CR16** Arthritis as a presentation of paraneoplastic syndrome: A case report  
*Matea Lukić, Ivan Prigl, Dora Uršić, Ana Marija Masle*

**CR17** Beyond the Ear: Complications Following Otitis Media  
*Tian Košar, Ana Klobučar, Andro Košec*

**CR18** Carcinoma of the parathyroid gland: a case report  
*Matea Kostić, Andrea Kostić, Maja Baretić*

**CR19** Functioning pituitary gonadotroph microadenoma responding to GnRH antagonist therapy: a case report  
*Petra Potrebnica, Velimir Altabas*

**CR20** Intermittent claudications of the hand after supracondylar humeral fracture in a 2-year old boy  
*Nora Knez, Karmen Jeričević, Luka Kelčec, Tomislav Vlahek, Dino Papeš*

**CR21** Juvenile idiopathic arthritis-associated uveitis  
*Matej Krišto, Sandro Kukić, Sanja Perić*

**CR22** Nature's Bandage: Exploring the Benefits of Amniotic Membrane Therapy  
*Lea Hasnaš, Lovro Mikulić, Tomislav Sečan*

**CR23** Refractory ventricular fibrillation in a patient with ST-elevation myocardial infarction (STEMI)  
*Petra Relota, Martina Periša, Lorena Remenar, Karla Schwarz, Tomislav Letilović*

**CR24** Renal artery stenting in a patient with renovascular hypertension  
*Lucija Čolaković, Bruno Bumči, Mia Edl, Antonio Kovačević, Tajana Turk*

**CR25** Simultaneous Occurrence of Acute Myeloid Leukemia and Chronic Lymphocytic Leukemia: A Case Report  
*Stjepan Galić, Ozren Jakšić*

**CR26** Spontaneous pneumomediastinum and pneumopericardium in a young female: a case report  
*Mihovil Santini, Lana Nikše, Pavao Mioč, Jakov Santini, Iva Tokić, Ivan Zeljković*

**CR27** Sub-inner limiting membrane haemorrhage successfully treated with pars plana vitrectomy – case report  
*Mislav Mokos, Lorena Karla Rudež, Tomislav Jukić*

**CR28** Takotsubo cardiomyopathy (broken heart syndrome)  
*Doroteja Đekić, Anja Čuk, Boško Skorić*

**CR29** Uncovering the Connection Between Stress and Cancer: A Case Report  
*Klara Dorešić, Maja Grubeša, Lara Fotez, Lucija Galiot, Jasmina Marić Brozić*

**CR30** Delayed Onset Of Acute Abdomen Revealing Foreign Body Ingestion  
*Ozana Miličević, Tomislav Knotek, Leo Matijašević, Iva Barišić*

**CR31** Diabetes Mellitus and diabetic ketoacidosis associated with pembrolizumab  
*Karla Lauš, Hrvoje Centner, Ema Schönberger, Silviija Canecki-Varžić*

**CR32** Dressler syndrome after myocardial infarction: a case report  
*Maja Alaber, Tina Stanković, Maša Sorić*

**CR33** Drug - drug interaction in a patient with epilepsy and newly diagnosed paroxysmal atrial fibrillation  
*Klara Bardač, Lucija Dafne Blažević, Lucija Nevena Barišić, Iveta Merćep*

**CR34** DYNAMIC LEFT INTRAVENTRICULAR OBSTRUCTION IN TAKOTSUBO CARDIOMYOPATHY IN A 62-YEAR-OLD WOMAN: A CASE REPORT  
*Stella Guštek, Petra Nežić, Mario Udovičić*

**CR35** Effectiveness of electroconvulsive therapy  
*Bruno Bumči, Hanna Pašić, Mia Edl, Lucija Čolaković, Antun Botica*

**CR36** Electroconvulsive treatment of patients with treatment-resistant schizophrenia and empty sella syndrome: two case reports  
*Zrinka Vuksan-Čusa, Iva Radoš, Eleonora Goluža, Marina Šagud*



**CR37** Emphysematous cystitis: a non-specific presentation

*Ivan Borlinić, Klara Brekalo, Lucija Dafne Blažević, Anna Braniša, Delfa Radić-Krišto*

**CR38** Endobronchial ultrasound-guided transbronchial fine needle aspiration (EBUS-TBNA): Solitary fibrous tumor of the mediastinum

*Robert Gečević, Darjan Ranilović, Ivan Marasović, Damir Vukoja, Đivo Ljubičić*

**CR39** Endoscopic treatment of mediastinal pancreatic pseudocyst using lumen apposing metal stents - Case report

*Sandro Kukić, Dominik Kralj, Tajana Pavić*

**CR40** Exceptionally large juvenile xanthogranuloma – a case report

*Luka Bulić, Eva Brenner, Suzana Ožanić Bulić*

**CR41** From Azoospermia to Fertility: A Successful Case of mTESE Treatment

*Lara Fotez, Martin Bobek, Klara Dorešić, Lucija Fotez, Dinko Hauptman*

**CR42** FROM PITYRIASIS LICHENOIDES CHRONICA TO SYPHILIS AND HIV – A DETECTIVE’S APPROACH

*Lorena Dolački, Josip Prnjak, Liborija Lugović-Mihić*

**CR43** From Polyuria to Pathological Fracture: A Challenging Case of Multiple Myeloma

*Lucija Galiot, Zdravko Mitrović*

**CR44** Fungus Balls in the Ureter of a Patient with Generalized Candida Mycosis

*Antonia Bukovac, Gabrijela Buljan, Ingrid Prkačin*

**CR45** Hereditary neuropathy with liability to pressure palsies as a possible predisposing factor to the development of Chronic inflammatory demyelinating polyneuropathy

*Marija Bukvić, Marija Ćorić, Rafael Toni Kovač, Krunoslav Budimir, Hrvoje Bilić*

**CR46** Herlyn-Werner-Wunderlich syndrome in a adolescent girl

*Vita Jugovac, Nika Baldani, Marko Gavrančić, Iva Mažić, Dinka Pavičić Baldani*

**CR47** Innovative Genome Joint Analysis for identification of novel deep-intronic de novo pathogenic variants in KMT2A gene - Wiedemann-Steiner Syndrome

*Matea Bagarić, Nives Živković, Mario Ćuk*

**CR48** Innovative Whole Genome Joint Analysis – case report of early diagnosis and preventive approach to**HFE Hemochromatosis**

*Marjan Kulaš, Dina Gržan, Sandro Kukić, Luka Lovrenčić, Mario Ćuk*

**CR49** Insulinoma as a rare cause of hypoglycemia - a case report

*Lucija Fotez, Lara Fotez, Alen Gabrić, Maja Baretić*

**CR50** Intraocular tuberculosis – case report

*Petra Galić, Lucija Matić, Lea Arambašić, Zara Miočić*

**CR51** The effect of art therapy on the degree of depression and the outcomes of Parkinson’s disease treatment

*Lorena Loje, Tea Kržak, Srđana Telarović*

**CR52** Left ventricular pseudoaneurysm of the inferior wall with thrombus: diagnosis and management

*Laura Carla Kraljević, Matija Marković*

**CR53** Management of Cushing’s disease when surgery is a tricky option – a case report

*Lucija Vusić, Vedrana Verić, Matea Živko, Velimir Altabas*

**CR54** Management of metabolic crisis in three-day-old newborn

*Tea Kržak, Lorena Loje, Ivo Barić, Dorotea Ninković*

**CR55** Mechanical Thrombectomy as an Effective Treatment for Pulmonary Embolism in Intermediate-high risk patients

*Alen Gabrić, Lucija Fotez, Lucija Ercegovac, Luka Novosel*

**CR56** Metastatic thyroid cancer after thyroidectomy in patient with MEN2A syndrome: a case report

*Ana Čala, Tina Dušek*

**CR57** Mild carnitine uptake defect due to a novel homozygous mutation in the SLC22A5 gene detected by newborn screening

*Lea Klepač, Klara Miljanić, Danijela Petković Ramadža, Ivo Barić, Tamara Žigman*

**CR58** ModuLifeTM- a novel dietary approach in management of a patient with moderate Crohn’s disease

*Alisa Fejzić, Hana Franić, Ana Barišić, Irena Karas*

**CR59** Myocardial bridge stenting complicated by coronary artery perforation and midLAD right ventricle fistula formation in NSTEMI patient

*Jelena Bošnjak, Stela Marković, Matias Trbušić*

**CR60** Myocardial Bridging: A cause for concern?

*Marin Boban, Antun Zvonimir Kovač, Mladen Jukić, Petar Medaković*

**CR61** Obstipation as a manifestation of bilateral hydronephrosis

*Marina Andrešić, Nikolina Novak, Josipa Živko, Maša Sorić*

**CR62** Personalized approach to patients with statin intolerance based on pharmacogenomics (function of OATP1B1 protein)

*Anja Čuk, Doroteja Đekić, Dunja Leskovar, Livija Šimičević*

**CR63** Pneumonitis as a side effect of breast cancer treatment: T-DXd and/or SBRT?

*Džana Bjelić, Sara Bognar, Jelena Benčić, Manuela Bajan, Natalija Dedić Plavetić*

**CR64** Posaconazole-induced Glucocorticoid Deficiency in a Patient with Myelodysplastic syndrome.

*Antonia Precali, Ivana Kraljević*

**CR65** Pulmonary embolism as a cause of cardiac arrest in a patient after a stroke

*Ena Parać, Stjepan Herceg, Marin Boban, Paola Negovetić, Nikolina Borščak Tolić*

**CR66** Rare complications of Sjögren's syndrome in a female patient

*Tin Rosan, Jana Jelenić, Marija Bakula*

**CR67** Recurrent acute pancreatitis

*Hana Franić, Alisa Fežić, Nedo Marčinković*

**CR68** Senile purpura, disseminated intravascular coagulation or a crime scene?

*Kristijan Harak, Lidija Ister, Marta Grgat, Lana Ivanišević*

**CR69** Spinal shock after a ground-level fall

*Leo Matijašević, Ines Trkulja, Andrija Matijević, Danijel Mikulić, Filip Miočinović, Iva Barišić*

**CR70** Spontaneous renal artery dissection possibly associated with antiphospholipid syndrome

*Gabrijela Buljan, Antonia Bukovac, Ingrid Prkačin*

**CR71** The Importance of a Watchful Eye: Multiple Infections in Immunocompromised Patient

*Ana Klobučar, Tian Košar, Nadira Duraković*

**CR72** The importance of CT-guided adrenal biopsy in an oncological patient: a case report

*Ante Listeš, Tajana Turk*

**CR73** Transcatheter Pulmonary Valve-in-Valve Implantation due to Severe Valve Stenosis Following Bioprosthetic Pulmonary Valve Replacement Degeneration

*Helena Ljulj, Sara Komljenović, Antonia Lovrenčić, Mario Udovičić*

**CR74** Treatment of enterocutaneous fistula with total parenteral nutrition in combination with octreotide: a case report

*Antonia Alfirević, Dina Ljubas Kelečić, Patricia Barić, Ana*

*Barišić*

**CR75** Unrecognized psychosis leads to severe hyponatremia, a case report

*Frano Šušak, Luka Bielen*

**CR76** 100 BLOOD TRANSFUSIONS IN 10 MONTHS DUE TO HEYDE SYNDROME

*Iva Barišić, Ozana Miličević, Leo Matijašević, Luka Blažević*

**CR77** Vertebrobasilar insufficiency due to subclavian-vertebral artery steal

*Marina Nađ, Mladen Pospišil, Eva Pleško*

**CR78** Virchow's node as the first manifestation of disseminated prostatic cancer

*Tina Stanković, Maja Alaber, Maša Sorić*

**CR79** Whole Genome Joint Analysis for identification of rare non-coding causative variants - case report of a child with mitochondrial diseases

*Dina Gržan, Marjan Kulaš, Lea Jukić, Petra Sulić, Mario Čuk*

**CR80** USE OF IMMUNOTHERAPY IN THE TREATMENT OF A PATIENT WITH TWO SIMULTANEOUS METASTATIC DISEASES

*Matej Penava, Anđelo Kurtin, Katarina Čular, Tajana Silovski*

## Clinical medicine

**CM01** Efficacy of oral formulation of semaglutide in obese patients with type 2 diabetes mellitus - a retrospective study

*Mateja Živko, Laura Vidović, Vedrana Verić, Tomislav Božek*

**CM02** Intraoperative floppy iris syndrome: comparison of two different alpha-adrenergic blockers

*Jurica Putrić Posavec, Sanja Masnec, Miro Kalauz, Matija Kalauz, Matea Severin*

**CM03** Prevalence of hepatitis E antibodies in solid organ and hematopoietic stem cell transplant candidates

*Ana-Marija Petani, Vesna Pečevski, Tatjana Vilibić Čavlek, Anna Mrzljak*

**CM04** Travel-related imported dengue infections in Croatia

*Vesna Pečevski, Ana-Marija Petani, Vladimir Savić, Tatjana Vilibić Čavlek*

**CM05** Correlating prostate imaging reporting and data system (PIRADS) version 2 scores with results of targeted biopsy of the prostate

*Domagoj Šarić, Tomislav Kuliš, Zoran Zimak, Bojan Čikić, Toni Zekulić, Željko Kaštalan*

**CM06** Dry eye disease and phacoemulsification cataract surgery*Mia Edl, Suzana Matić, Lucija Matić, Lucija Čolaković, Bruno Bumči***CM07** Effectiveness of bare sclera technique versus conjunctival autograft transplantation for pterygium treatment*Nina Krobot Čutura, Goran Tomičić***CM08** Higher occurrence of chronic kidney disease in JAK2 V617F mutated MPN patients with higher mutant allele burden*Petra Veić, Ena Sorić, Marko Lucijanić, Rajko Kušec***CM09** Patient-Oriented Severity Index (MD POSI) as Quality of Life (QoL) Assessment Tool for Patients with Menier's disease*Stela Marković, Jelena Bošnjak, Andro Košec***CM10** What makes women in Croatia satisfied with childbirth?*Klara Miljanić, Iva Tkalčec, Stela Majetić, Aida Mujkić***CM11** Original research- COVID 19 pandemic impact on newly discovered cancer in family medicine practice: a five-year comparison*Eva Pleško, Mladen Pospišil, Marina Nađ*

## Literature review

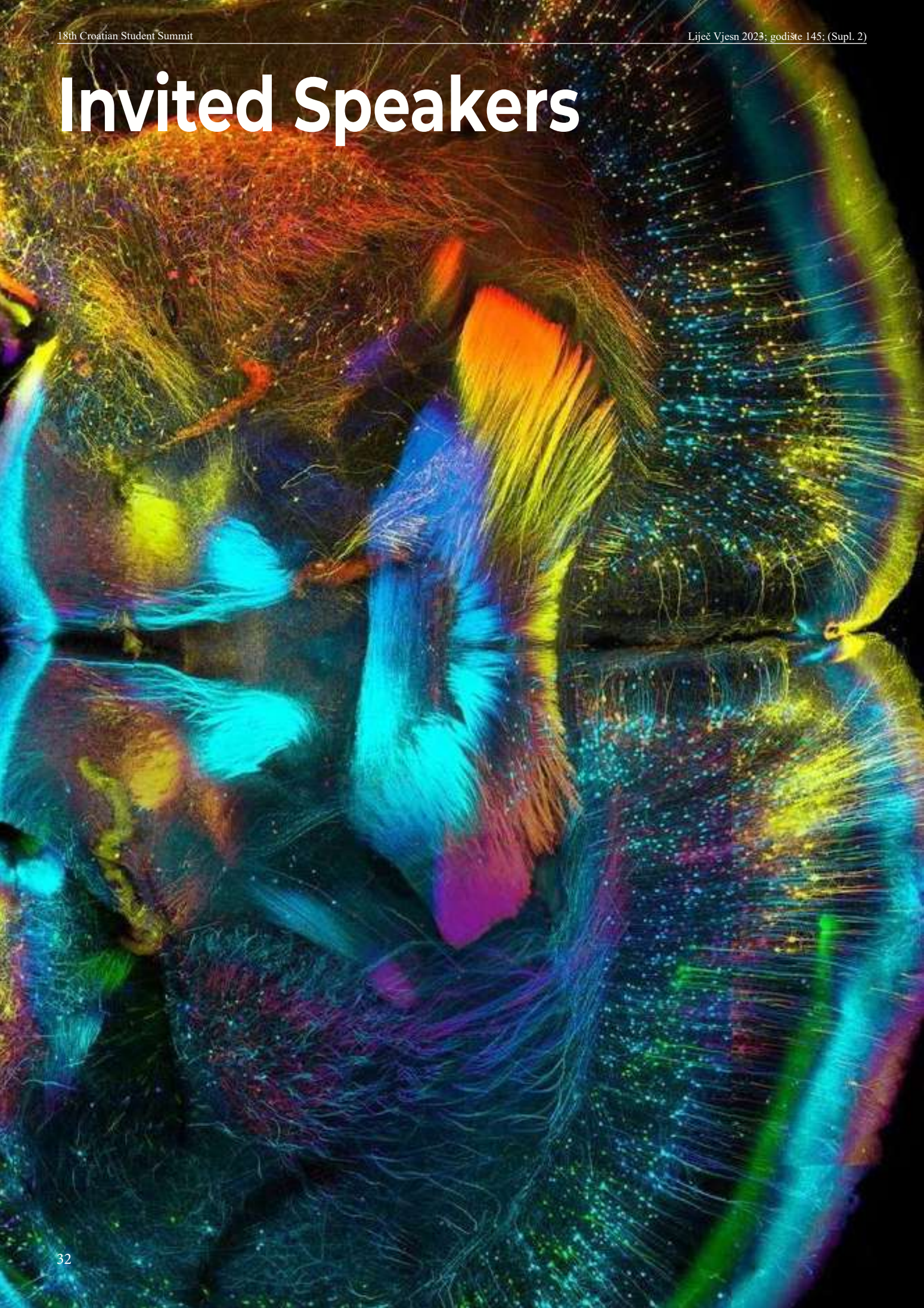**LR01** HIV and depression*Mirta Peček, Ante Orbanić, Lea Tomašić*

## Other

**O01** How to have perfect skin and an even better workshop – our experience with organizing a cricothyrotomy workshop*Josip Kajan, Jelena Pokos, Nenad Nešković, Josip Grbavac, Slavica Kvolik***O02** Anticipating Moral Injury In Medical Students*Laura Ivanović Martić, Borna Katić, Lada Zibar*



# Invited Speakers





## ABSTRACTS

## Invited Speakers

## IS01

**Stress and the endocrine system**

Assistant Professor Maja Baretić, M.D., PhD

*Division of Endocrinology, Department of Internal Medicine, University Hospital Centre Zagreb  
School of Medicine, University of Zagreb*

DOI: <https://doi.org/10.26800/LV-145-supl2-IS01>

Stress as a state of unbalanced homeostasis, triggered by intrinsic or extrinsic agents that affect physiologic and behavioral responses aiming to get optimal body balance. Stress affects all systems of the body, as well as endocrine glands. The main parts of the endocrine system involved in the response to stress are the hypothalamic-pituitary-adrenal axis and the autonomic nervous system which interact with other parts of the central nervous system and peripheral organs. The catecholamine hormones epinephrine and norepinephrine reacted rapidly to stress being secreted from the adrenal medulla. They have numerous effects on behaviour, metabolism, and the cardiovascular system and their response is commonly termed the fight-or-flight-or-freeze response. The glucocorticoid hormones are released from the adrenal cortex interacting with intracellular receptors and initiating gene transcription. It means that glucocorticoids have a delayed, but more sustained effect than catecholamines. The glucocorticoids orchestrate a wide array of responses to the stressor. They have direct effects on behavior, metabolism and energy exchange, reproduction, growth, and the immune system. Stress can also lead to changes in the serum level of many other hormones like growth hormone and prolactin. Numerous endocrine disorders can be caused and/or worsened by stressors like gonadal dysfunction, psychosexual dwarfism, and obesity. Exposure to endogenous or exogenous stress can also alter the clinical status of many preexistent endocrine disorders such as precipitation of adrenal crisis and thyroid storm. The aim of hormonal response to stress is to pull together adaptive responses against the specific agent that triggers tension. If a response to stress is deficient or excessive it can result in psychological pathology and alerted endocrine response. Even more, under conditions of long-term stress, the glucocorticoid-mediated effects become maladaptive and can lead to disease. Long-term exposure to common stress in experimental animals showed epigenetic changes in DNA influencing how genes that control mood and behaviour are expressed.

## IS02

**Psycho-oncology: yesterday, today, tomorrow**

Professor Marijana Braš, M.D., PhD

*Center for Palliative Medicine, Medical Ethics and Communication Skills, School of Medicine, University of Zagreb*

DOI: <https://doi.org/10.26800/LV-145-supl2-IS02>

Modern knowledge about the psychosocial and psychobiological dimensions of oncological diseases, resulting from clinical experiences and numerous types of research, led to the intensive development of psycho-oncology, which is characterized by a strong integration between several professional disciplines (oncology, psychiatry, psychological and social sciences, neuroscience, family medicine, palliative medicine, etc.). Psychosocial aspects of oncological diseases have attracted a lot of attention during the last few decades due to the high prevalence and mortality of oncological diseases, but also because of the development of psycho-neuro-endocrine-immunology and novel insights about the interconnectedness of soul and body in the whole of medicine. In this presentation, the historical development of psycho-oncology will be shortly discussed, followed by a review of the current state of psycho-oncology in the world and in the Republic of Croatia. Special emphasis will be placed on the clinical presentations of the most common psychiatric disorders in oncology and the discussion of individual therapeutic interventions (psychotherapy, psychopharmacotherapy, sociotherapy, the role of art in therapy, etc.), but also on the importance of promoting various preventive activities. Psychiatric/psychological support helps the patient's cooperation in all phases of treatment, with the aim of the "oncology patient" retaining their personhood with their usual life challenges, responsibilities, and pleasures. Communication skills in oncology are extremely important, so the latest knowledge about the most common communication "challenges" will be presented, such as telling bad news, discussing the prognosis and risks of certain forms of treatment, conversations related to the end of life, conducting family meetings, etc. How to promote person-centered medicine and people-centered health care in psycho-oncology? How to educate health professionals, patients, and the general public about this area? How to use new technologies in psycho-oncology? What can we expect in the future? The presentation will try to answer these questions, but it is even more important to stimulate the discussion and thoughts of other participants with the aim of faster development of psycho-oncology in the Republic of Croatia and a better understanding of "mind-body" medicine in this century, which we proudly call the century of the mind.

**IS03****Psychodermatological burden of skin diseases**

Iva Dediol, M.D., PhD, Professor Mirna Šitum, M.D., PhD

*Department of Dermatovenereology, University Hospital Centre "Sisters of Mercy"*

DOI: <https://doi.org/10.26800/LV-145-sup12-IS03>

Skin diseases are mostly chronic and lifelong with recurrences. The special thing about skin diseases is their psychosocial burden. Pruritus and in fewer instances pain are common physical symptoms of skin diseases. All of these facts influence a patient's life, social network and psychological status. Different dimensions of quality of life and psychiatric comorbidities: depression and anxiety were evaluated among patients with dermatovenereological diseases. Two hundred and ninety female and male patients suffering from different dermatoses and venereological diseases participated in the study. All participants were treated in an inpatient and outpatient treatment at the Department of Dermatovenereology. Participants were divided into three groups. The first group of patients were those with symptomatic dermatoses like psoriasis, atopic dermatitis and venous ulcer. The second group were asymptomatic dermatoses like vitiligo, alopecia and acne. The third group involved venereological patients with diagnoses of anogenital warts, genital Herpes simplex infection and Balanopostitis. Consenting participants completed the following standardized psychological questionnaires: Dermatology Specific Quality of Life Index, Beck's Index of Depression and State and Trait Anxiety Inventory. Participants with symptomatic skin diseases had the highest influence of the disease on their quality of life.. Depression and anxiety symptoms were mild but 4,1 % of the participants had high depression scores and 13-15 % had very high anxiety scores. Patients with high intensity of the skin lesions were more depressed, but patients with always exposed lesions were more anxious as a state and trait. Patients with pruritic and painful dermatoses have the highest influence of skin disease on their quality of life. Localisation and intensity of the dermatovenereological disease influence symptoms of depression and anxiety.

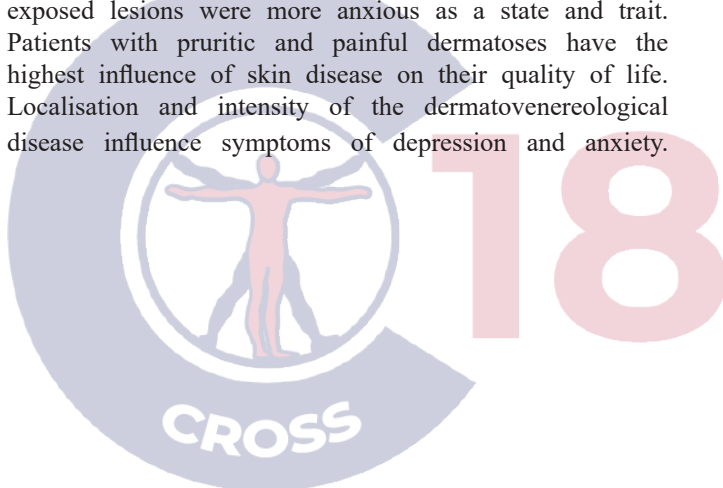
**IS04****Adopting the paradigm shift into clinical practice**

Professor Vida Demarin, MD, PhD, FAAN, FAHA, FESO, FEAN, FWSO, HAZU

*Department of Medical Sciences, Croatian Academy of Sciences and Arts*

DOI: <https://doi.org/10.26800/LV-145-sup12-IS04>

Growing evidence demonstrates an intimate relationship between the immune system and the endocrine and nervous systems. The psychoneuroendocrine system can influence the immune response and thereby the capacity of the organism to cope with the illness and vice-versa the immune system can have an impact on neuroendocrine functions. Such cross-talk among systems is dependent upon feedback loops working to maintain homeostatic equilibrium, thus pointing out the need for an interdisciplinary, integrative approach where biological and psychological systems interact with each other reciprocally. Diseases are the result of an alteration at the bio-psycho-social level that can indicate lifestyle changes that should be made in addition to appropriate medical management and treatment. Emotions and stress significantly affect health and one's susceptibility to pathology, as well as one's ability to recover from an illness. This idea is the embodiment of a new physiology in clinical practice, leading to paradigm shift, which should be incorporated into clinical practice. Such a vision forms the basis of a new integrated approach in prevention and therapy and at the same time opens the possibility of removing the historical and philosophical opposition between mind and body, as well as medicine and psychology.





**IS05****Psychosomatic medicine in gynecology and obstetrics**

Vesna Gall, M.D., PhD

*Delivery department, Clinic for Women's Diseases and Obstetrics, University Hospital Centre "Sisters of Mercy"**Croatian Society for Psychosomatics in Gynecology and Obstetrics*DOI: <https://doi.org/10.26800/LV-145-supl2-IS05>

Throughout history, the body and mind have been connected. Today, thanks to deeper study and understanding of psychology and physiology and the relationship between the mind and the body, the influence of psychosocial factors on physiological changes in the body has been confirmed. Modern understanding of psychosomatics takes into account the interaction of physical and psychological factors in all disorders and illnesses. Therefore, psychosomatic medicine is an interdisciplinary medical field that relates the influence of social, psychological, and behavioral factors on bodily processes and quality of life. It integrates interdisciplinary evaluation and multidisciplinary approach to diagnosis and treatment. According to the International Classification of Diseases, 10th revision (ICD-10) of the World Health Organization, these diseases are classified in the category "Psychological and behavioral factors associated with disorders or diseases classified elsewhere" (F54). To be categorized as such, psychological and behavioral factors should be identified in the etiology of physical disorders, such as asthma, dermatitis, gastric ulcers, mucous colitis, ulcerative colitis, urticaria, and others. A psychosomatic disorder is a psychological condition that leads to physical symptoms often without any evident medical explanation. The symptoms are caused by worry or dissatisfaction or other mental problems, and not a physical problem, although it may also exist as a result of the impact of the psychological state on the body or "vice versa". People with this disorder often seek medical help believing that their problems are caused by medical conditions but also becoming frustrated without a diagnosis, and the symptoms of psychological distress remain unrecognized. Women have somatic pain about 10 times more often than men. Studies have revealed risk factors for developing somatic symptoms such as chaotic lifestyle, difficulties in recognizing and expressing emotions, neglect in childhood, a history of sexual abuse, and other psychological conditions such as depression or personality disorders, substance abuse (such as alcoholism or drug addiction), and unemployment. The most common symptoms that can develop are fatigue, insomnia, pain (such as muscle pain or back pain), high blood pressure (hypertension), breathing difficulties (dyspnea or shortness of breath), digestive disorders (upset stomach), headaches and migraines, erectile dysfunction (impotence), skin rash (dermatitis), and gastric ulcers (peptic ulcers). In addition to the somatic symptom itself (such as pain or stomach upset), people with psychosomatic disorders often develop additional symptoms of anger and irritability, depression, and anxiety. Such patients often visit healthcare providers, often jumping from one doctor to another. They have difficulty functioning

at work, school, or in society. The most common problem is precisely the failure to recognize the problem from the medical side, and then the patient's non-acceptance of the diagnosis. These are the two main factors that adversely affect the outcome. In gynecology and obstetrics, there are various conditions that can lead to psychosomatic disorders, such as: loss of a child, premature birth, complications in pregnancy, fear of parenthood, facing the fear of pregnancy, fear of chromosomal or structural defects of the fetus, fear of childbirth (tokophobia), fear of infertility, especially expressed in couples undergoing assisted reproductive techniques. In gynecology, the most common symptoms that can be associated with psychosomatic disorders are abdominal pain, vulvovaginitis, dyspareunia, sexual dysfunction, disrupted body image (aesthetic genital surgeries), dysmenorrhea, oncology patients and other. Treatment is based on the following methods: cognitive-behavioral therapy, medication (usually anxiolytics and antidepressants), mindfulness-based therapy, and referral to a mental health professional (psychiatrist or psychologist). What to recommend to such patients? Talk about awareness of what they can control and what they cannot. Learn methods of controlling their emotions, keep a journal to increase awareness of their thoughts and feelings, engage in regular physical activity, get enough sleep, set boundaries to reduce pressure on themselves, limit alcohol and avoid smoking, maintain a healthy diet and body weight, meditate, practice progressive muscle relaxation, and seek the support of loved ones. In obstetrics, the situation is more complicated as there is a limited time period for diagnosing problems, and therefore, less time to establish the previously mentioned techniques, given that pregnancy itself is a stressor for the body with hormonal and consequent emotional upheavals. Nevertheless, some of the above techniques and lifestyle habits can be learned and acquired to reduce potential complications in pregnancy, childbirth, and early parenthood. In conclusion, a psychosomatic disorder is a psychological condition that leads to physical symptoms, usually without any other medical explanation or diagnosis. People with somatic symptoms often seek medical help for tests and treatment. These are real and distressing symptoms but of psychological origin. Behavioral therapies and lifestyle changes can help. They can also prevent unnecessary tests and treatments and significantly improve treatment outcomes.



**IS06****Impact of life event stress on patients with COPD**

Assistant Professor Marija Gomerčić-Palčić, M.D., PhD

*Diagnostic and interventional pulmonology clinic,  
Department of Clinical Immunology, Pulmonology and  
Rheumatology, University Hospital Centre "Sisters of  
Mercy"*

*School of Medicine, University of Zagreb*

DOI: <https://doi.org/10.26800/LV-145-supl2-IS06>

Anxiety and depression are more common in patients with COPD (6–80%) than in the general population and are usually underdiagnosed comorbidities in COPD. Both are related with poor prognosis, lower lung function, younger age, female gender, smoking, cough and lower quality of life.

(1) COPD patients have a relative risk of 1.69 of developing depression and the risk is greater in patients who experience more pronounced breathlessness. Anxiety evolves most often during exacerbations and patients claim that stress deteriorates their dyspnea. Increased life event stress can increase tobacco use which increases the risk of disease progression, pronounced symptoms, exacerbation, and lung cancer (2). Life event stress can also increase the risk of anxiety and depression. It was shown that elevated levels of psychological distress are related to more frequent and longer hospitalizations for exacerbations among COPD patients. A greater impact of life event stress on psychological status and quality of life in COPD patients is possibly due to different perception of stressful life events compared to perception of patients without COPD and poorer coping skills as well as low socio-economic status. (3) Depression disrupts hypothalamic-pituitary-adrenal activities that regulate responses to stress and immune system resistance to disease and is associated with impaired immune defenses due to chronic elevated levels of cortisol. Aforementioned cause loss of memory resulting in forgetting patients to take their medication or follow medical advice (4). During chronic stress, a prolonged increase in cortisol leads to glucocorticoid resistance, high inflammatory markers, and increased susceptibility to respiratory viruses, all of which may increase the risk of COPD exacerbations. Under stressful situations, it is common for people to hyperventilate which can also cause COPD flare-ups. A stress response is found to trigger the release of molecules such as histamines and leukotrienes resulting in narrowing of the airways. Stress stimulates the activity of the vagus nerve. Parasympathetic activity contributes to airway obstruction in multiple ways in COPD: bronchoconstriction, mucus secretion and airway remodeling by increased proliferation of both fibroblasts and smooth muscle cells. COPD patients with an increased basal cholinergic tone and/or with vagal fluctuations induced by anxiety and stress could benefit from anticholinergic agents as the first therapeutic option. There is no evidence that anxiety and depression should be treated differently in the presence of COPD. Pulmonary rehabilitation should be encouraged since studies have found that physical exercise has a beneficial effect on depression in general.

(1) GOLD 2023 dostupno na: <https://goldcopd.org/2023-gold-report-2/>

- (2) Kulik MC, Glantz SA. Softening among U.S. smokers with psychological distress: more quit attempts and lower consumption as smoking drops. *Am J Prev Med.* 2017;53(6):810-817. doi: [HTTPS://DOI.ORG/10.1016/J.AMEPRE.2017.08.004](https://doi.org/10.1016/j.amepre.2017.08.004)
- (3) Lu Y, Nyunt MS, Gwee X, Feng L, Feng L, Kua EH, Kumar R, Ng TP. Life event stress and chronic obstructive pulmonary disease (COPD): associations with mental well-being and quality of life in a population-based study. *BMJ Open.* 2012 Nov 19;2(6):e001674. doi: 10.1136/bmjopen-2012-001674. PMID: 23166130; PMCID: PMC3533009
- (4) Piper L. Depressive symptoms contribute to death in chronic obstructive pulmonary disease. *Chest.* 2009; 135: 619–625

**IS07****Family in the bathroom**

Hrvoje Handl, M.D.

*Day hospital for eating disorders H(RANA), Clinic for  
Psychiatry "Sveti Ivan"*

DOI: <https://doi.org/10.26800/LV-145-supl2-IS07>

When distinguished members of a large family inhabit their house bathroom, all of us, like voyeurs, can see the dynamic or psychodynamic of many eating disorders.

So let me just point to some scenes in this "bathroom play" and talk about psychosomatic energy in emotions behind the closed door.

This is, shortly to say, the theme of my presentation although it isn't sponsored by any bathroom industry.

**IS08****Psychotherapy as a stress modulator – resilience and integration**

Associate Professor Tihana Jendričko, M.D., PhD

*Department of Psychotherapy, University Psychiatric Hospital Vrapče**Study of Social work, Faculty of Law, University of Zagreb**School of Medicine, University of Zagreb*DOI: <https://doi.org/10.26800/LV-145-supl2-IS08>

Coping with stress can represent an adaptive factor of resilience. Some of the positive effects of stress are stimulation of the brain, short-term improvement of immunity, improvement of resilience and motivation of a person for success. The phenomenon of “stress inoculation” is a process during which a person develops an adaptive response to mild or moderate stressors and better resilience to the negative effects of future stressors. The ability to experience all emotions, including negative ones, is important for our psychological development. Negative experiences need to be integrated into the understanding of one’s own life, relationships, and the outside world. Our personality is constantly developing and enables us to understand the significance of various life events. Negative experiences and frustrations encourage our development, with them we do not stagnate except in the case of an excessive amount of frustrations that drain us and can lead to a breakdown. Although we do not prefer negative experiences, they can stimulate mental processes that promote a sense of meaning through a new perspective of their value in everyday life. One of the important roles of psychotherapy is to help develop a sense of continuity over time, the simultaneous integration of negative and positive experiences, in order to develop an integrated sense of self and more flexible, adapted functioning.

**IS09****Functional gastrointestinal disorders**

Agata Ladić, M.D., PhD

*Department of Gastroenterology and Hepatology, Department of Internal Medicine, University Hospital Centre Zagreb*DOI: <https://doi.org/10.26800/LV-145-supl2-IS09>

A vast number of patients visiting gastrointestinal offices suffer of functional gastrointestinal disorders. The main characteristic of these disorders is that patients have no organic explanation for their symptoms, which often leads to stigmatization of patients and labelling them as psychiatric cases. Functional disorders encompass a broad spectrum of entities, covering every section of GI tract - from the foregut to the hindgut. The most frequent diagnoses are irritable bowel syndrome, functional dyspepsia and functional constipation. Since there is still no valid biomarker which would define certain functional disorder, the diagnosis is verifiable on the basis of distinctive symptoms, signs and exclusion of an organic disease. This often leads to a high utilization of a health-care system. The pathophysiology involves dysregulation of gut-brain interaction, gut microbial dysbiosis, visceral hypersensitivity, abnormal GI motility and altered immune function. Next to that, very common is psychological comorbidity, which should be treated accordingly. The general principles of treatment are based on a biopsychosocial understanding and involve management of physical symptoms and psychological counselling when appropriate. In the future, treatment approaches to functional gastrointestinal disorders are likely to become targeted and personalised - based not only on symptoms but also on underlying pathophysiology and psychology.





**IS10****Start by taking care of yourself**

Mirella Lasić, M.D., Daniel Milošević, M.Osych.,  
Lucia Sekulić, M.D., Katarina Skopljak, M.D.

*University Psychiatric Hospital Vrapče  
Protection of Mental Health of Children and Youth,  
Mental Health and Addiction Prevention Service,  
Public Health "Dr. Andrija Štampar"  
Health Center Karlovac  
Clinic for Psychiatry "Sveti Ivan"*

DOI: <https://doi.org/10.26800/LV-145-supl2-IS10>

In the medical profession, every patient that comes knocking on our door needs to be assessed and treated, no exceptions. This requires us to give away parts of ourselves to others, but is also one of the reasons why we often forget to consider our own well-being in the process. How often do we advise our patients on how to live a healthy and fulfilling life, but at the same time don't give ourselves time and opportunities to do the same? We often feel that our value is recognized only through our academic and professional achievements. Rarely do we ever bring into question our own health as it's become common to consider it as part of the sacrifices that are made to succeed as a physician. So, do we adequately take care of our own health? Mental health awareness is crucial to our calling as the ever growing demands and expectations of our field are a burden that not only do we struggle with in our work life but also carry into our personal lives. More often than not, this repeated cycle takes its toll and prevents us from fulfilling our duty, but also affects our personal lives. How do we deal with the ensuing disappointment and dissatisfaction or the success without the following gratification leaving us feeling empty, questioning the point of everything? By simply asking ourselves this question means we're finally ready to take action and prioritise our mental health through properly maintained mental hygiene, for as many as there are ways to disrupt and decompensate our mental health, there are countless more to improve and nurture it. So, let's finally roll those dice and see where taking action gets us.


**IS11****Sleep disorders as risk factors for mental disorders**

Assistant Professor Domagoj Vidović, M.D., PhD

*Department of Psychophysiology and Organically  
Conditioned Mental Disorders, University Psychiatric  
Hospital Vrapče*

DOI: <https://doi.org/10.26800/LV-145-supl2-IS11>

Observed from an evolutionary perspective, time spent in sleep is extremely dangerous due to exposure to various threats. Today, sleep can be seen as a time of isolation, rest, and mental and physical recovery. Modern man, overwhelmed by information available through social networks and physically inactive, faces a series of sleep disorders that disturb his health. The importance of sleep disorders as risk factors for the development of psychological disorders will be shown through life-span and transdiagnostics, all with the aim of emphasizing adequate sleep in achieving a fruitful life.



**IS12****Irritable bowel syndrome and microbiota: special focus on diet**

Professor Darija Vranešić Bender, BsC, PhD

*Unit of Clinical Nutrition, Department of Internal Medicine, University Hospital Centre Zagreb  
Faculty of Food Technology and Biotechnology  
School of Medicine, University of Zagreb*

DOI: <https://doi.org/10.26800/LV-145-sup12-IS12>

Irritable Bowel Syndrome (IBS) is a common gastrointestinal disorder that is manifested by abdominal pain and a changed rhythm of bowel movements lasting at least three months. It affects the small and large intestine, and 10-15% of adults, mostly women, suffer from the disorder. The exact cause is not known, but it is assumed that inflammation and infection, stress, and disruption of the balance of neurotransmitters and microbiota contribute to the development of the syndrome. Available treatments are numerous and include dietary supplements (eg. dietary fiber, peppermint oil, probiotics), dietary changes, antidepressants, psychotherapy, acupuncture, antidiarrheals, and laxatives. Sometimes irritable bowel syndrome is also called stomach headache or “nervous bowel”. IBS is associated with gut microbial dysbiosis, bacterial and other communities of the microbiota, such as fungi, viruses, archaea, and other parasitic microorganisms. Patients with IBS show less fungal and viral diversity and increased abundance of *Candida albicans*. Therefore, novel therapeutic methods inhibitors targeting fungal pathogenic pathways, probiotic fungi, prebiotics, and fecal microbiota transplantation. Regardless of the true factors that cause irritable bowel syndrome (infection, hormones, stress or gut microbiota imbalance), changes in eating habits can have a significant impact on pain and discomfort in people suffering from the syndrome. When prescribing a diet, the overlap of this condition with certain food intolerances (lactose, fructose, carbohydrates, histamine), food allergies, and non-celiac gluten sensitivity (NCGS) should be taken into account. Recent scientific evidence indicates that a relatively restrictive elimination diet low in certain natural sugars can alleviate the feeling of bloating, reduce the amount of gas, relieve pain and other symptoms in patients with irritable bowel syndrome. In recent years, several studies have shown a significant improvement in symptoms in patients who eliminated foods rich in certain natural sugars (fermentable sugars, oligosaccharides, disaccharides, monosaccharides and polyols - the so-called FODMAP foods) from their diet, such as rye, wheat, garlic, onions, artichoke, mushroom, cauliflower, beans, chickpeas, lentils, honey, apple... Although a diet that excludes the so-called FODMAP food does not work for all patients, an increasing number of experts support its principles, at least when it comes to short-term use. However, such a diet is quite complex and must be carried out under the supervision of a doctor or nutritionist so that the diet remains nutritionally balanced. The long-term use of the FODMAP diet has not been sufficiently researched to date, and a gradual liberalization of the diet after a reduction in the intensity of symptoms is mainly advocated, especially in the light of knowledge about the influence of this diet on the diversity of the intestinal microbiota.

**IS13****Field of pediatrics and sick child in the 21st century**

Professor Jurica Vuković, M.D., PhD

*Department of Pediatrics, University Hospital Centre Zagreb  
School of Medicine, University of Zagreb*

DOI: <https://doi.org/10.26800/LV-145-sup12-IS13>

Greater picture: overpopulation is the gravest concern for well-being of planet Earth

Frame within frame: In Croatia number of newborn babies in 1961 was roughly 62 000, in 2021 it was 34 000 and declining.

Our ultimate goal: don't let our babies grow up to be sick, make them be healthy and prosperous parents and grandparents

Paths to the finish line:

Make love not war

Prevent social and emotional deprivation

As a medical professional choose the life of learning and devotion

Listen to your patient and his parents, learn about his whereabouts, sit by his bedside, do the physical exams repeatedly, use lab and diagnostic tools prudently, analyze, learn throughout the life and make yourself available whenever its necessary.

Join the fight against all forms of addiction.

Use the AI in field of medicine for the benefit of society and individual.



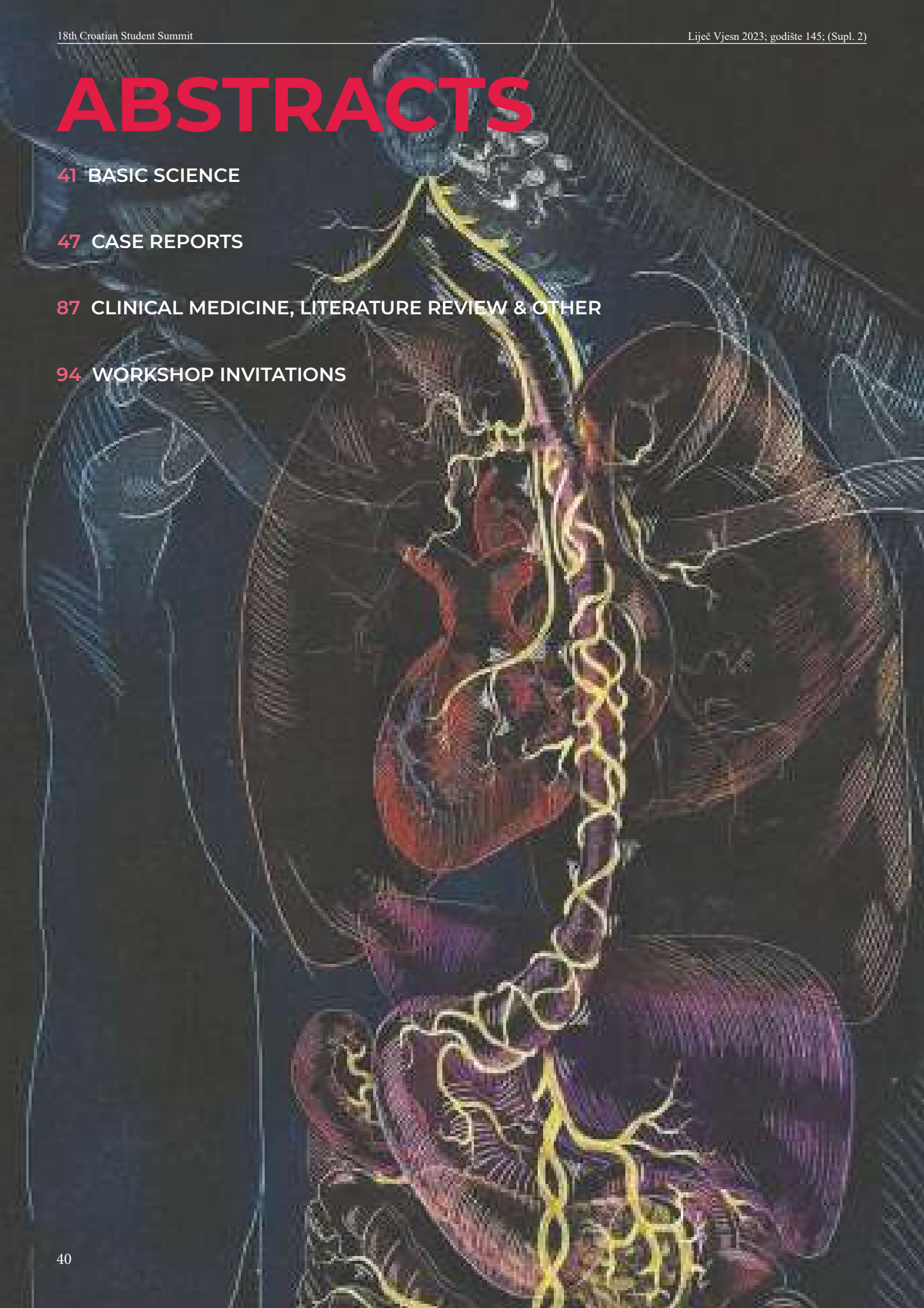
# ABSTRACTS

**41** BASIC SCIENCE

**47** CASE REPORTS

**87** CLINICAL MEDICINE, LITERATURE REVIEW & OTHER



**94** WORKSHOP INVITATIONS





## ABSTRACTS

## Basic Science

**BS01 Effect of Pentadecapeptide BPC 157 on Hemodynamic and ECG Disorders Caused by Sotalol in Wistar Albino Rats**Marjeta Linarić Lipnjak<sup>a</sup>, Matej Lacković<sup>a</sup>, Helen Marie Chiddenton<sup>a</sup><sup>a</sup> Department of Pharmacology, School of Medicine, University of Zagreb, Zagreb, CroatiaDOI: <https://doi.org/10.26800/LV-145-supl2-BS01> Marjeta Linarić Lipnjak 0009-0009-0778-3582, Matej Lacković 0009-0001-1830-5916, Helen Marie Chiddenton 0009-0002-6399-2011**KEYWORDS:** antiarrhythmic sotalol; BPC 157; pharmacology; therapy**INTRODUCTION/OBJECTIVES:** The cytoprotective stable gastric pentadecapeptide BPC 157 has already shown beneficial cardiovascular, antiarrhythmic, antioclusive effects. In this research, we examined the effect of BPC 157 on hemodynamic disorders caused by sotalol, a class II and III antiarrhythmic.**MATERIALS AND METHODS:** Albino Wistar rats were administered sotalol (80 mg / kg, intragastric) and treated with saline or BPC 157 (10 ng / kg, 1mL, intragastric) for 5 minutes thereafter. In deeply anesthetised rats, with a cannula connected to a pressure transducer, inserted into the portal vein, inferior caval vein and abdominal aorta at 15 min 90 min or 180 min after sotalol. The superior sagittal sinus was cannulated then after laparotomy, the pressure recording in the portal vein, inferior vena cava, and abdominal aorta was performed.**RESULTS:** In the control group, an increase in superior sagittal sinus pressure ( $12 \pm 11$  mmHg), as well as an increase in portal vein ( $18 \pm 1$  mmHg) and inferior caval vein pressures ( $12 \pm 1$  mmHg) were noted, along with the decrease in abdominal aortic pressure ( $52 \pm 2$  mmHg). These effects were attenuated in BPC treated animals ( $-2 \pm 1$  mmHg for superior sagittal sinus,  $6 \pm 1$  mmHg in portal vein,  $5 \pm 1$  mmHg in inferior caval vein, and  $83 \pm 2$  mmHg in abdominal aorta).**CONCLUSION:** In summary, BPC 157 attenuated detrimental hemodynamic effects of sotalol while the effects on ECG parameters were also noted, but not as lasting, as hemodynamic ones, supporting the view of BPC 157 as a rapid-acting protective agent.**BS02 Effect of Pentadecapeptide BPC 157 on Hypercalcaemia in Rats**Matej Lacković<sup>a</sup>, Helen Marie Chiddenton<sup>a</sup>, Sara Burić<sup>a</sup><sup>a</sup> Department of Pharmacology, School of Medicine, University of Zagreb, Zagreb, CroatiaDOI: <https://doi.org/10.26800/LV-145-supl2-BS02> Matej Lacković 0009-0001-1830-5916, Helen Marie Chiddenton 0009-0002-6399-2011, Sara Burić 0009-0009-6472-786X**KEYWORDS:** BPC 157, hypercalcaemia, pharmacology**INTRODUCTION/OBJECTIVES:** Isolated from gastric juice stable pentadecapeptide BPC 157 has already shown cytoprotective and organoprotective properties. Beneficial effects of BPC 157 on various organic systems such as cardiovascular, digestive, skeletomuscular system have already been proven. Focus of this research is hypercalcaemia and its effects on general function of the organism, ECG and haemodynamic and their presentation after BPC 157 administration.**MATERIALS AND METHODS:** CaCl<sub>2</sub> was administrated to Albino Wistar rats (250mg/kg, intraperitoneal) after which saline (1ml) or BPC 157 (10ng/kg, 1ml, intraperitoneal) were immediately applied. Subjects were observed for 9 minutes after administration, and every 3 minutes their motoric function was tested on rotating grid. ECG leads were then recorded as well as blood pressures in superior sagittal sinus, inferior caval vein, superior mesenteric vein and aorta. Brain and internal organs were recorded.**RESULTS:** Nontreated animals showed muscle weakness very early while testing motoric functions. BPC 157 treated animals stayed on rotating grid while nontreated animals were often falling. Blood pressures measured in superior sagittal sinus, inferior caval vein and superior mesenteric vein in nontreated animals were higher than blood pressures in BPC 157 treated animals. Aortic blood pressure of nontreated animals was lower than aortic pressure in treated ones. Brain of nontreated animals had visible oedema while brain of treated animals didn't. Nontreated animals developed gastric and duodenal stress ulcers whereas treated didn't. Nontreated animals developed acute pancreatitis whereas treated had less lesions.**CONCLUSION:** In summary, BPC 157 mitigated disruptive effect of hypercalcaemia on motoric functions as well as cardiovascular functions and reduced negative effect on internal organs.

### BS03 Effects of Stable gastric pentadecapeptide BPC 157 and osteogenic material on bone regeneration in mandibula

Andrej Vrdoljak<sup>a</sup>, Petra Horvat<sup>a</sup>, Marjeta Linarić Lipnjak<sup>a</sup>

<sup>a</sup> Department of Pharmacology, School of Medicine, University of Zagreb, Zagreb, Croatia

DOI: <https://doi.org/10.26800/LV-145-supl2-BS03>

 Andrej Vrdoljak 0009-0007-4588-964X, Petra Horvat 0009-0007-4632-208X, Marjeta Linarić Lipnjak 0009-0009-0778-3582

**KEYWORDS:** BPC-157; mandible; ossification; pharmacology

**INTRODUCTION/OBJECTIVES:** INTRODUCTION: Our work was focused on the effect of Stable gastric pentadecapeptide BPC-157 on the osteointegration of synthetic hydroxyapatite in a 2mm cavity located on the left mandibular body

**MATERIALS AND METHODS:** MATERIALS AND METHODS: After drilling a 2mm hole using a surgical drill in the mandibular body of anesthetized Wistar rats, the cavity was filled using synthetic bone particles of hydroxyapatite. BPC 157 (10µg/kg or 10ng/kg) was applied to one group while the other group received saline solution (1ml/rat). Solutions were given directly to the injury after which it was treated using stitches. The control group of rats was given food and water for the next 2 months while the BPC-157 treated rats were drinking the BPC-157 solution instead of regular water. The rats were scanned twice at intervals of 1 month using an x-ray machine. After 2 months the rats were sacrificed and the heads were stored in 4% formalin.

**RESULTS:** In the control saline-treated group there were visible fragments of synthetic bone particles around the filled cavity as well as visible non-continuity of the bone meaning the bone did not regenerate fully. In BPC-157 treated rats the synthetic bone fragments around the cavity have been absorbed and the visible continuity of the bone is present which indicates that the bone had healed much faster.


**CONCLUSION:** CONCLUSION: Animals treated with BPC-157 have shown much better results in bone and injury healing as seen on radiographical images.

### BS04 Hepatoprotective effects of BPC-157 - paracetamol overdose

Sara Burić<sup>a</sup>, Hrvoje Vraneš<sup>a</sup>, Vlasta Vuković<sup>a</sup>

<sup>a</sup> Department of Pharmacology, School of Medicine, University of Zagreb, Zagreb, Croatia

DOI: <https://doi.org/10.26800/LV-145-supl2-BS04>

 Sara Burić 0009-0009-6472-786X, Hrvoje Vraneš 0000-0003-3544-8385, Vlasta Vuković 0009-0004-3095-6289

**KEYWORDS:** BPC-157; hepatotoxicity; paracetamol; pharmacology

**INTRODUCTION/OBJECTIVES:** Paracetamol, also known as acetaminophen, is a widely used medication to treat pain and fever. As it's one of the over-the-counter medications, it's easily accessible to everyone. Its mechanism of action is the inhibition of prostaglandin synthesis in the CNS to reduce hyperalgesia. It also influences the thermoregulatory center in the hypothalamus and lowers fever. 90-95% of paracetamol is metabolized in the liver where it's conjugated with glucuronic acid and sulfates into inactive metabolites, and the rest via cytochrome-p450. Its main side effect is hepatotoxicity and acute liver injury. Here we investigate the hepatoprotective effects of BPC-157 while administering a toxic dose of paracetamol intraperitoneally in rats.

**MATERIALS AND METHODS:** The dose of paracetamol was 5 g/kg and we used deeply anesthetized Wistar rats that weighed 250g. After anesthetizing the rats, a craniotomy was performed. After that, paracetamol was administered intraperitoneally along with BPC-157 (10 ng/1mL, 1 mL solution) in treated groups or saline (1 mL) in control groups. 10 minutes after the administration the brain swelling and ECG were recorded, and 15 minutes after, abdominal veins were photographed.

**RESULTS:** When comparing the sizes of abdominal veins and brains of rats that were given BPC-157 and those that were not, we can see a difference in swelling. It's more apparent in the control group. On some ECG recordings, STEMI was detected in the control group, while no similar findings occurred in the BPC-157 group.


**CONCLUSION:** We can see that the toxicity of paracetamol on the brain and blood vessels was mitigated when BPC-157 was administered.

## BS05 Histological aspects of Therapeutic effects of Stable gastric pentadecapeptide BPC 157 on stomach perforation

Petra Horvat<sup>a</sup>, Marjeta Linarić Lipnjak<sup>a</sup>, Matej Lacković<sup>a</sup>

<sup>a</sup> Department of Pharmacology, School of Medicine, University of Zagreb, Zagreb, Croatia

DOI: <https://doi.org/10.26800/LV-145-supl2-BS05>

 Petra Horvat 0009-0007-4632-208X, Marjeta Linarić Lipnjak 0009-0009-0778-3582, Matej Lacković 0009-0001-1830-5916

**KEYWORDS:** BPC 157; histology; pharmacology; stomach perforation

**INTRODUCTION/OBJECTIVES:** We focused on histological aspects of the cytoprotective effects of Stable gastric pentadecapeptide BPC 157 after stomach perforation in rats was performed.

**MATERIALS AND METHODS:** After performing stomach perforation on anesthetized and laparotomized Wistar rats, to one group of animals BPC 157 (10 µg or 10 ng/kg) was applied, and to the other saline (1 ml/rat) was applied through the perforated defect in the stomach. BPC 157-treated and saline-treated groups were sacrificed 15 and 60 minutes after perforation. Representative tissue specimens of the liver, brain, stomach, kidney, small and large intestine, heart, and lungs fixed in 10% formalin were embedded in paraffin. Cross sections were stained with hemalaun and eosin and analyzed under a light microscope. Appropriate pathological scoring systems were used to grade injury.

**RESULTS:** In saline-treated animals, cerebral hemorrhage of the neocortex was present together with congestion in all mentioned organs. In BPC-157 treated rats there were no changes in the heart, liver, and kidney, with only mild congestion of the lung and small cerebral hemorrhage of the neocortex. In the control group, margins of stomach perforation showed mucosal congestion. Transmural hyperemia was present in perforation margins and the rest of the stomach wall. Contrary, in BPC-157 rats only mild mucosal congestion was observed at perforation margins.


**CONCLUSION:** BPC-157 shows a beneficial effect in healing the perforated defect. As seen histologically, it reduces congestion and hemorrhage in organs.

## BS06 ISOSORBIDE-5-MONONITRATE INDUCED PERIPHERAL AND CENTRAL VASCULAR DYSFUNCTION IN RATS AND TREATMENT WITH STABLE GASTRIC PENTADECAPETIDE BPC 157

Vlasta Vuković<sup>a</sup>, Hrvoje Vraneš<sup>a</sup>, Luka Kalogjera<sup>a</sup>

<sup>a</sup> Department of Pharmacology, School of Medicine, University of Zagreb, Zagreb, Croatia

DOI: <https://doi.org/10.26800/LV-145-supl2-BS06>

 Vlasta Vuković 0009-0004-3095-6289, Hrvoje Vraneš 0000-0003-3544-8385, Luka Kalogjera 0000-0002-1703-0033

**KEYWORDS:** BPC157; IS-5-MN; migraine; pharmacology; vascular dysfunction


**INTRODUCTION/OBJECTIVES:** Introduction: Although the understanding of migraine pathophysiology is incomplete, it is now well accepted that this neurovascular syndrome is mainly due to cranial vasodilation. Several experimental migraine models have been developed, including the use of a nitric oxide (NO) donor, such as isosorbide-5-mononitrate (IS-5-MN). Nitric oxide regulates cerebral and extracerebral cranial blood flow and arterial diameters. We observed the therapeutic effects of stable gastric pentadecapeptide BPC 157 on peripheral and central vascular dysfunction caused by IS-5-MN administration.

**MATERIALS AND METHODS:** Materials and methods: We used deeply anesthetized male Wistar rats, weighing 250 g. IS-5-MN was administered in the solution, intraperitoneally (four groups; 20 mg, 30 mg, 40 mg, 50 mg). We divided each group into controls and treated animals and applied saline bath intraperitoneally (1 ml solution) to the control group and BPC157 (10 ng/mL, 1 ml solution) to the treated group. 5 minutes after administration, we monitored macroscopic organ features, volume assessment with Image J and blood pressures in: inferior caval vein, portal vein, aorta and superior sagittal sinus.

**RESULTS:** Results: In the control group, volume assessment with Image J showed macroscopic signs of brain edema, heart congestion, caval and portal vein congestion and collapsed aorta and azygos vein. Regarding blood pressures, rats in the control group had portal hypertension, caval hypertension, increased intracranial pressure and aortic hypotension. These effects were counteracted in BPC 157 treated rats.

**CONCLUSION:** Conclusion: We found beneficial effects of BPC 157 in the treatment of IS-5-MN induced peripheral and central vascular dysfunction which was observed as a migraine model.



**BS07 Molecular effects of stable gastric pentadecapeptide BPC 157 on psoriasis**Hrvoje Vraneš<sup>a</sup>, Luka Kalogjera<sup>a</sup>, Ivan Maria Smoday<sup>a</sup><sup>a</sup> Department of Pharmacology, School of Medicine, University of Zagreb, Zagreb, CroatiaDOI: <https://doi.org/10.26800/LV-145-sup12-BS07> Hrvoje Vraneš 0000-0003-3544-8385, Luka Kalogjera 0000-0002-1703-0033, Ivan Maria Smoday 0000-0002-4416-7262


KEYWORDS: BPC 157; pharmacology; psoriasis

**INTRODUCTION/OBJECTIVES:** Psoriasis is a chronic, relapsing, immune-mediated skin disease. Etiopathogenesis of psoriasis includes pro-inflammatory cytokines such as: TNF-alpha, IL-12, IL-17, IL-23 etc. IL-17 exerts its effect by binding to IL-17R (Interleukin-17 receptor) on keratinocytes. Keratinocytes then in response produce  $\beta$ 2-defensin.  $\beta$ -defensins have multiple antimicrobial and pro-inflammatory effects that are observed in psoriasis. Since stable gastric pentadecapeptide BPC 157 has shown anti-inflammatory effects in several studies, in this research we explored anti-inflammatory effects of BPC 157 on molecular level in psoriasis.

**MATERIALS AND METHODS:** We treated HaCat cells (keratinocyte cell line) with IL-17A (100 ng/ml). We also applied BPC 157 (10  $\mu$ g/ml) or saline and then checked for  $\beta$ 2-defensin mRNA expression in intervals of 1h and 48h following the IL-17A application and therefore mRNA induction. We have also checked if BPC157 inhibits  $\beta$ 2-defensin mRNA expression by treating cells before, after or at the same time as IL-17A. For this purpose, keratinocytes were pre-treated for 1h with BPC 157, treated with IL-17A for 1h and then treated with BPC 157, or treated with IL17A and BPC 157 at the same time.

**RESULTS:** We verify that  $\beta$ 2-defensin mRNA induction was inhibited by treatment with BPC157 in a statistically significant manner. Only the concomitant treatment inhibits the expression of  $\beta$ 2-defensin mRNA.

**CONCLUSION:** In conclusion, our results show that BPC157 inhibits the pro-inflammatory effects induced by in vitro treatment of keratinocytes with IL-17A. This explains anti-inflammatory effects of BPC 157 on psoriasis.

**BS08 PENTADECAPEPTIDE BPC 157 RESOLVES TOURNIQUET INDUCED ISCHEMIA-REPERFUSION INJURY**Katarina Oroz<sup>a</sup>, Luka Ćorić<sup>a</sup>, Andrej Vrdoljak<sup>a</sup>, Leon Palac<sup>a</sup><sup>a</sup> Department of Pharmacology, School of Medicine, University of Zagreb, Zagreb, CroatiaDOI: <https://doi.org/10.26800/LV-145-sup12-BS08> Katarina Oroz 0000-0002-4861-9529, Luka Ćorić 0000-0002-1965-9660, Andrej Vrdoljak 0009-0007-4588-964X, Leon Palac 0000-0002-2666-5911



KEYWORDS: BPC 157; compartment syndrome; pharmacology; tourniquet

**INTRODUCTION/OBJECTIVES:** This study aimed to investigate tourniquet-induced compartment syndrome of the limb, consequential development of multiple organ dysfunction syndrome, and its counteraction with pentadecapeptide BPC 157 therapy.

**MATERIALS AND METHODS:** Rubber-band tourniquet was placed on the left knee of anesthetized rats to induce 20 minutes long ischemia. Injection of either saline (5 ml/kg b.w.) or BPC 157 (2  $\mu$ g/kg b.w.) was intraperitoneally administered at 30 - 60 seconds post removing the rubber band. Changes in volume and color of both legs were recorded with a USB microcamera pre- and post-inducing ischemia and after removing the tourniquet. After 15 minutes of reperfusion, the internal organs, vessels, and brains of rats were recorded. Furthermore, blood pressure was measured via intravascular cannulation.

**RESULTS:** Rubber band-induced compartment syndrome caused progressing leg swelling and congestion, huge noxious syndrome, and multiorgan failure. Rats developed intracranial, portal, and caval hypertension, and aortal hypotension. Treating rats with BPC 157 at the beginning of reperfusion, reduced leg swelling and congestion progression and, after 15 minutes of reperfusion, treated rats had normal leg presentation. BPC 157 also counteracted changes in blood pressure, and reduced brain swelling and congestion of internal organs. Contrary, the leg of the control animal was persistently swollen. Changes in the blood pressure were not resolved after 15 minutes of reperfusion and consequentially internal organs were congested.

**CONCLUSION:** The application of BPC 157 at the beginning of reperfusion after 20 minutes long tourniquet-induced ischemia, reduces leg swelling, and counteracts the multiorgan failure caused by ischemia-reperfusion injury.


**BS09 Potential role of peripheral and central vascular failure in neuroleptic, amphetamine and domperidone pharmacodynamics and toxicology.**Ivan Maria Smoday<sup>a</sup>, Katarina Oroz<sup>a</sup>, Luka Ćorić<sup>a</sup><sup>a</sup> Department of Pharmacology, School of Medicine, University of Zagreb, Zagreb, CroatiaDOI: <https://doi.org/10.26800/LV-145-supl2-BS09> Ivan Maria Smoday 0000-0002-4416-7262, Katarina Oroz 0000-0002-4861-9529, Luka Ćorić 0000-0002-1965-9660**KEYWORDS:** amphetamine; antipsychotic agents; cytoprotection; domperidone**INTRODUCTION/OBJECTIVES:** Vascular failure is a pathological entity that seems to be antecedent to various pathological processes. This investigation theorized that vascular failure-related phenomena would be apparent in early phases after the application of neuroleptics, amphetamine, and domperidone before their expected behavioral and neurological symptoms. BPC-157 pentadecapeptide (BPC157) showed vascular failure mitigating properties in previous investigations and was used to further elaborate findings.**MATERIALS AND METHODS:** Deeply anesthetized male Wistar rats were used for investigation. Neuroleptics and/or amphetamine and domperidone were given i.p. After 30 seconds, i.p. treatment was applied with 1mL of saline (control group) or 1mL of BPC157 solution (1µg/L, treated group). 5 minutes after treatment application, ECG, brain swelling, vein congestion, heart congestion, invasive blood pressure, thrombus in major vessels, and phd assessments were conducted.**RESULTS:** Compared with healthy animals neuroleptics and/or amphetamine and domperidone caused vascular failure manifesting as ECG disturbances (QTc interval prolongation), brain swelling, heart congestion, aortic hypotension, venous hypertension, thrombosis in major blood vessels, as well as pathohistological signs of hemorrhage and thrombosis centrally (brain) and peripherally (lungs, heart, viscera, kidneys). BPC157 mitigated these changes.**CONCLUSION:** These vascular failure-related changes could play a key role in their pharmacodynamics and toxicology since these changes emerge before the expected behavioral and neurological symptoms. Assessment of the expression of genes, oxidative radicals, and NO concentration relevant to vasoactivity will give a genetic base for these findings.**BS10 Stable Gastric Pentadecapeptide BPC 157 Macroscopic Effect on Haematoma and Swelling in Spinal Cord Injured Rats**Luka Ćorić<sup>a</sup>, Andrej Vrdoljak<sup>a</sup>, Petra Horvat<sup>a</sup>, Marija Ćorić<sup>a</sup><sup>a</sup> Department of Pharmacology, School of Medicine, University of Zagreb, Zagreb, CroatiaDOI: <https://doi.org/10.26800/LV-145-supl2-BS10> Luka Ćorić 0000-0002-1965-9660, Andrej Vrdoljak 0009-0007-4588-964X, Petra Horvat 0009-0007-4632-208X, Marija Ćorić 0009-0001-8153-5052**KEYWORDS:** BPC 157; Laminectomy; Pharmacology; Spinal Cord Injury**INTRODUCTION/OBJECTIVES:** The aim of this study is to investigate the effect of stable gastric pentadecapeptide BPC 157 effect on counteracting haematoma and swelling caused by spinal cord injury.**MATERIALS AND METHODS:** Wistar rats were anaesthetized and underwent laminectomy at the level of L2-L3. To create a compressive injury, a neurosurgical piston was placed over the exposed dura mater and left for 60 seconds. Four groups of rats were randomized: one to BPC 157 2 µg/kg, 1mL, another to 1mL saline, both applied intraperitoneally 10 minutes after the injury. The spinal cord was filmed under a microcamera for 20 minutes, after which the rats were sacrificed. The remaining two groups were operated in the same manner and left untreated until day 4, when they were reoperated, with either BPC 157 (10 ng/kg 1mL) or saline (1mL) administered intragastrically and recorded. We singled out photographs from the video at specific timestamps: 0 minutes, 5 minutes, 10 minutes and 20 minutes after the application. Using ImageJ software and applying the Square-cube law, relative swelling and haematoma volumes were calculated and graphically displayed.**RESULTS:** Compared to a healthy spinal cord, there is an increase in swelling 10 minutes after the injury. After administering the medication, relative volumes of haematoma and swelling in BPC 157 treated rats are significantly decreased with the passage of time, while the same parameters in the control group continued to increase.**CONCLUSION:** These beneficial macroscopic effects are base for further research of BPC 157 as a therapeutic solution for spinal cord injury.

## BS11 The effects of a varying doses of pilocarpine and lithium induced status epilepticus, and treatment with BPC-157

Helen Marie Chiddenton<sup>a</sup>, Sara Burić<sup>a</sup>, Vlasta Vuković<sup>a</sup>

<sup>a</sup> Department of Pharmacology, School of Medicine, University of Zagreb, Zagreb, Croatia

DOI: <https://doi.org/10.26800/LV-145-supl2-BS11>

 Helen Marie Chiddenton 0009-0002-6399-2011, Sara Burić 0009-0009-6472-786X, Vlasta Vuković 0009-0004-3095-6289

**KEYWORDS:** BPC-157; Lithium; pharmacology; pilocarpine; Status epilepticus

**INTRODUCTION/OBJECTIVES:** Peptadecapeptide BPC-157 has been reported to have a large spectrum of in vivo activities, from anti-ulcer to central action on the brain dopaminergic system, in addition to the aforementioned, BPC-157 might counteract standard convulsant induced seizures, insulin-, paracetamol-, alcohol withdrawal- and serotonin-syndrome-induced convulsion. The pilocarpine model of temporal lobe epilepsy uses a cholinomimetic convulsant, pilocarpine, to induce status epilepticus; as a result, hippocampal damage occurs thus resulting in the development of spontaneous recurrent seizures. In rats, pilocarpine can be administered with lithium, thus significantly reducing the pilocarpine dose required to induce status epilepticus and resulting in a higher percentage of animals developing status epilepticus.

**MATERIALS AND METHODS:** We reported the effect of the BPC-157 (given in doses of 10 µg/kg, 10 ng/kg), L-NAME (5 mg/kg), L-arginine (100 mg/kg), given intraperitoneally alone and/or combined on the status epilepticus in rats induced by pilocarpine and lithium given by intraperitoneal application. Pilocarpine was administered in a variety of doses 60, 80 and 120 mg/kg, accompanied by a lithium dose of 127 mg/kg.

**RESULTS:** BPC-157 application partially counteracted pilocarpine/lithium convulsions. L-NAME consistently aggravated the convulsion presentation and was associated with a fatal outcome during the observation period. Interestingly, L-arginine also consistently aggravated the convulsion presentation. When given together, these aggravating effects did not counteract each other. These effects were consistently attenuated by the BPC-157 application.


**CONCLUSION:** In conclusion the pilocarpine/lithium convulsions are mitigated by BPC-157. Since L-NAME and L-arginine effects did not counter each other in effect, another non-NO-system might also be involved.

## BS12 The effects of pentadecapeptide BPC 157 on the healing of the incisional skin wound in rats

Luka Kalogjera<sup>a</sup>, Ivan Maria Smoday<sup>a</sup>

<sup>a</sup> Department of Pharmacology, School of Medicine, University of Zagreb, Zagreb, Croatia

DOI: <https://doi.org/10.26800/LV-145-supl2-BS12>

 Luka Kalogjera 0000-0002-1703-0033, Ivan Maria Smoday 0000-0002-4416-7262

**KEYWORDS:** BPC 157, incision, wound healing, skin

**INTRODUCTION/OBJECTIVES:** Healing of the wounds is accomplished by: the resolution of vessel constriction, the primary platelet plug formation, the fibrin mesh which acts to stabilize the platelet plug and finally resolution of the clot. By simultaneously curing cutaneous and other tissue wounds (colocutaneous, gastrocutaneous, esophagocutaneous, duodenocutaneous, vesicovaginal, and rectovaginal) in rats, the potency of stable gastric pentadecapeptide BPC 157 (Body Protective Compound 157) has been already proven. We focused on the unexplored therapy effect of BPC 157 on an incisional wound.

**MATERIALS AND METHODS:** Male Wistar rats, 180-220 g body mass, were used in this experiment. Animals were divided into two groups, the treated group received 10 µg/kg BPC 157 1mL topically immediately after wound induction, and the control group received an equal volume of saline. Rats were anaesthetized and the surgical site was shaved and prepared for the procedure. Scalpel (size 12) was used to make a skin wound in the middle line on the back of the animals. The wound was observed and photographed 2, 5, 7 and 10 days after the procedure and tissue specimens were prepared for histology after sacrifice on the 10th day.

**RESULTS:** Reticulin and collagen formation in BPC 157-treated animals were accelerated compared with controls. Treated animals showed fully developed reticulin fibres already after 10 days. Macroscopically, wound healing was healing faster in BPC 157 treated group.

**CONCLUSION:** BPC 157 exhibits a strong, promoting involvement in the healing process of incisional skin wounds in a rat experimental model.



## ABSTRACTS

## Case Reports

**CR01 Ankylosing spondylitis: how does it affect the quality of life?**

Eva Perak<sup>a</sup>, Valerija Plečko<sup>a</sup>, Antonija Gračanin<sup>a</sup>, Ana Gudelj Gračanin<sup>a,b</sup>

<sup>a</sup> School of Medicine, University of Zagreb, Zagreb, Croatia

<sup>b</sup> Department of Clinical Immunology, Rheumatology and Pulmonology, University Hospital Sveti Duh, Zagreb, Croatia

DOI: <https://doi.org/10.26800/LV-145-supl2-CR01>

 Eva Perak 0000-0001-7279-0345, Valerija Plečko 0000-0002-6161-8707, Antonija Gračanin 0009-0004-5643-1683, Ana Gudelj Gračanin 0000-0003-2651-2664

**KEYWORDS:** ankylosing spondylitis; mental health; quality of life; upadacitinib

**INTRODUCTION/OBJECTIVES:** Ankylosing spondylitis is a progressive and debilitating disease known to immensely affect the quality of life and frequently cause disability. There are several instruments that measure this effect, such as Bath Ankylosing Spondylitis Disease Activity Index (BASDAI), Bath Ankylosing Spondylitis Functional Index (BASFI), Visual Analogue Scale (VAS), Patient Global Assessment (PGA) etc.

**CASE PRESENTATION:** In 2023 a 43-year-old man with ankylosing spondylitis underwent disease activity and function evaluation as well as screening for depression. Several self-administered questionnaires were used. The results were 5.4/10 for BASDAI, 5.1/10 for BASFI, 7/10 for PGA of disease activity, VAS scores were 6/10 for pain and fatigue and 70/100 for impairment of overall health, all indicating significant level of disease activity. Surprisingly, Beck's Depression Inventory (BDI) score was only 1/63 indicating almost perfect mental health despite symptom intensity. Due to persistence of symptoms on NSAIDs, upadacitinib (1x15 mg) was initiated. Disease activity reevaluation 3 weeks later showed no significant improvement and even worsening in some assessments (BASDAI 6.6/10, BASFI 6.6/10, PGA 7/10, VAS for pain 6/10, fatigue 6/10 and impairment of overall health 30/100), although mental health was still impeccable (BDI 0/63). According to guidelines, full reevaluation of upadacitinib effect is made after 3 months, as 3 weeks is too soon.

**CONCLUSION:** Effects of rheumatologic diseases on life quality and mental health must be evaluated for each patient individually. Discordance between disease severity and patient's mental wellbeing is possible, as is shown in this case. Nonetheless, alternative treatment options should be considered until adequate disease control is achieved.


**CR02 Association between venous anomaly of the cerebellum and tremor**

Martina Periša<sup>a</sup>, Karla Periša<sup>a</sup>, Srđana Telarović<sup>a,b</sup>

<sup>a</sup> School of Medicine, University of Zagreb, Zagreb, Croatia

<sup>b</sup> Department of Neurology, University Hospital Center Zagreb, Zagreb, Croatia

DOI: <https://doi.org/10.26800/LV-145-supl2-CR02>

 Martina Periša 0000-0001-6854-5080, Karla Periša 0000-0002-6669-0812, Srđana Telarović 0000-0002-1287-6144

**KEYWORDS:** cerebellum; clonazepam; tremor; venous anomaly

**INTRODUCTION/OBJECTIVES:** Tremor is an involuntary movement of a body part that often occurs due to damage to the extrapyramidal system. Action-intention tremor usually occurs in ipsilateral lesions of the cerebellum. Such lesions can be caused by changes in venous drainage created by venous anomalies.

**CASE PRESENTATION:** A 73-year-old man is presented for his first examination in the Polyclinic for Extrapyramidal Diseases upon referral from a neurosurgeon due to left hand tremor that had appeared in the certain activities, positions, and stress over the past three years. His medical history includes hyperlipidemia, hypertension and a right kidney nephrectomy at the age of 69 due to cancer. He was also diagnosed with a venous anomaly in the right cerebellar hemisphere. He did not take dopamine receptor blockers and there were no reports of tremor in other family members. Upon examination, a postural and action tremor of the left hand was observed, without rigidity and with coordination tests consistent with the tremor. To rule out suspicion of paraneoplastic syndrome, anti-Hu, anti-Yo, and anti-Ri antibodies were requested, which were negative. The diagnosis of a movement disorder, most likely primarily caused by venous anomaly of the cerebellum, with contralateral presentation, was established. Clonazepam therapy was recommended. An excellent effect of the drug was observed during the follow-up examination, with only a slight tremor noticeable.

**CONCLUSION:** The venous anomaly of the right cerebellar hemisphere caused a contralateral tremor of the left hand, which is a nonspecific finding of a malformation with such localization. The patient is successfully treated with clonazepam.

**CR03 Bumpy road on a way to diagnose sarcoidosis**Maro Brbora<sup>a</sup>, Marcela Babić<sup>a</sup>, Marija Gomerčić Palčić<sup>b</sup><sup>a</sup> School of Medicine, University of Zagreb, Zagreb, Croatia<sup>b</sup> Department of pulmonology, Sestre milosrdnice University Hospital Center, Zagreb, CroatiaDOI: <https://doi.org/10.26800/LV-145-supl2-CR03>

 Maro Brbora 0009-0004-3482-1293, Marcela Babić 0000-0002-7161-2464, Marija Gomerčić Palčić 0000-0002-6836-4447

**KEYWORDS:** arthritis; joint diseases; lymphadenopathy; sarcoidosis


**INTRODUCTION/OBJECTIVES:** Sarcoidosis is a systemic disease with unknown etiology characterized by noncaseating granulomas in any organ, most commonly the lungs and intrathoracic lymph nodes. Approximately 10 to 15 percent of patients with sarcoidosis have an associated arthropathy. Diagnosis may be difficult when a patient presents with articular complaints alone, so the presence of sarcoidosis is usually established after other organs are affected.

**CASE PRESENTATION:** A 50-year-old female patient first presented with pain in small joints of hands and feet and was treated as reactive arthritis due to a positive finding of *Ureaplasma urealyticum*. Treatment with doxycycline and NSAIDs resulted in complete articular pain relief. An extensive workup

was done. Chest X-rays showed small bilateral nonspecific noduli and blood results revealed higher anti-CCP levels (11.8 IU/mL). Patient's serum and 24-hour urine calcium levels, ACE and chitotriosidase were normal. Seven months later patient started to cough and noticed dyspnea in exertion. Physical examination revealed right basal inspiratory crackles. Spirometry showed mild restriction, and CO diffusion was altered too. Chest CT was done and lung fibrosis and mediastinal and bilateral lymphadenopathy were seen. Bronchoalveolar lavage didn't show disease activity (CD4:CD8 1.5) and there were no granulomas in the pathology specimen. Endobronchial ultrasound-guided fine-needle aspiration was done and sarcoidosis of the lymph nodes was proved.

**CONCLUSION:** Painful joints as the first presentation of sarcoidosis can easily be misinterpreted if it is the only marker of the disease. Suspicion of reactive arthritis and rheumatoid arthritis misled us and the patient got her diagnosis only after ten months.

**CR04 Ovarian thecoma in adolescent – a rare case of hirsutism**Nika Baldani<sup>a</sup>, Marko Gavrančić<sup>a</sup>, Vita Jugovac<sup>a</sup>, Lana Škratić<sup>a,b</sup><sup>a</sup> School of Medicine, University of Zagreb, Zagreb, Croatia<sup>b</sup> Division for Reproductive Medicine and Gynaecological Endocrinology, Department of Obstetric and Gynecology, Clinical Hospital Centre Zagreb, Zagreb, CroatiaDOI: <https://doi.org/10.26800/LV-145-supl2-CR04>

 Nika Baldani 0000-0002-8412-3598, Marko Gavrančić 0000-0002-5262-956X, Vita Jugovac 0000-0003-1989-6276, Lana Škratić 0000-0002-6416-3736

**KEYWORDS:** Adolescent; Hirsutism; Thecoma

**INTRODUCTION/OBJECTIVES:** The main goal of managing hirsutism in adolescent girls is to distinguish familial idiopathic hirsutism from endocrinological disorders such as PCOS and androgen-secreting tumors. The latter account for <0.02% cases and typically present with rapidly progressing hirsutism, virilization and elevation of serum androgens. Some rare benign ovarian tumors have a slow progression and long duration of symptoms before diagnosis. Ovarian thecomas typically occur in postmenopausal women but few cases have been reported in adolescence. Thecomas are almost always estrogenic; 10% of the luteinized forms are androgenic. They are usually clinically benign, although several have been reported malignant in literature.

**CASE PRESENTATION:** A 19 year-old female, presented with progressive facial hirsutism in the last 4 years. BMI was 21 kg/m<sup>2</sup>. Physical examination revealed terminal coarse hair growth over lips and chin. Ferriman-Gallwey score was 8. She presented without acanthosis nigricans, clitoromegaly, voice hoarseness, galactorrhea and features of Cushing's syndrome or acromegaly. Her hormonal profile showed slightly elevated testosterone levels with normal TSH, LH, FSH, DHEAS, PRL and 8 a.m. cortisol. She was diagnosed with idiopathic hirsutism and treated with laser hair removal and eflornithine. After 4 years of treatment and unsatisfactory results, trans-abdominal ultrasound revealed a normal-sized uterus and right-sided solid ovarian mass (4x3 cm). A laparotomy and unilateral salpingo-oophorectomy was performed. Histological examination confirmed a luteinized thecoma with no malignancy. Postoperatively hirsutism improved.

**CONCLUSION:** Identification of non-PCOS pathology with hyperandrogenism represents a diagnostic challenge and may be missed without a pragmatic screening approach. In all cases of hirsutism ovarian ultrasound should be performed.


### CR05 Brain tumor in the morbidly obese patient: Diagnostic and therapeutic challenges

Afan Ališić<sup>a</sup>, David Glavaš Weinberger<sup>a</sup>, Božidar Novoselović<sup>b</sup>

<sup>a</sup> School of Medicine, University of Zagreb, Zagreb, Croatia

<sup>b</sup> Department of Endocrinology, Diabetes and Metabolic diseases „Mladen Sekso“, Sestre Milosrdnice University Hospital, Zagreb, Croatia

DOI: <https://doi.org/10.26800/LV-145-supl2-CR05>

 Afan Ališić 0000-0003-1945-6262, David Glavaš Weinberger 0000-0003-4671-7499, Božidar Novoselović 0009-0005-7736-4974

**KEYWORDS:** brain tumor; magnetic resonance imaging; obesity

**INTRODUCTION/OBJECTIVES:** Tumors of the sellar and the suprasellar region are complex tumors and high-quality imaging is fundamental for diagnosis, characterization, and guidance of treatment planning. While the gold standard for diagnostics is contrast-enhanced magnetic resonance imaging (MRI), it is a challenging procedure in morbidly obese patients. This report aims to present a case of a morbidly obese patient with a brain tumor and the diagnostic and therapeutic challenges of its treatment.

**CASE PRESENTATION:** A 51-year-old female patient with an expansive brain tumor of the sellar region was transferred from General Hospital Šibenik in December 2022. Because of the patient's weight of 215 kg, a BMI (body mass index) of 82,8 kg/m<sup>2</sup>, and immobility for the last 2 years, the standard MRI was infeasible. An organization of further diagnostics procedures like computerized tomography (CT) was demanding and resulted in poor diagnostics. During hospitalization in our clinic, she lost 40 kilograms due to a reduced diet and treatment for diabetes mellitus. After four weeks of difficult nursing and caring for the patient an open MRI was arranged and confirmed a diagnosis of a suprasellar tumor formation. Two weeks later she was transferred to the department of Neurosurgery for transcranial surgery of a tumor mass. The patient is currently recovering in the intensive care unit (ICU).

**CONCLUSION:** Although sellar and suprasellar tumors are diagnosed with standard MRI, an open MRI is an alternative procedure for morbidly obese patients. Globally, the incidence of obesity is increasing so diagnostic and therapeutic procedures should be adjusted for these patients.


### CR06 Brain-gut axis dysfunction in young athlete with unfulfilled dreams - irritable bowel syndrome

Karlo Tkalec<sup>a</sup>, Petra Terzić<sup>a</sup>, Adrijan Tiku<sup>a</sup>, Silvija Čuković-Čavka<sup>b</sup>

<sup>a</sup> School of Medicine, University of Zagreb, Zagreb, Croatia

<sup>b</sup> Division of Gastroenterology, University Hospital Center Zagreb, Zagreb, Croatia

DOI: <https://doi.org/10.26800/LV-145-supl2-CR06>

 Karlo Tkalec 0000-0003-2811-8716, Petra Terzić 0000-0002-7687-1430, Adrijan Tiku 0000-0001-5564-467X, Silvija Čuković-Čavka 0000-0002-6176-7948

**KEYWORDS:** brain-gut axis; irritable bowel syndrome; psychiatric treatment

**INTRODUCTION/OBJECTIVES:** Irritable bowel syndrome (IBS) is a disorder characterized by recurrent abdominal pain and bowel movement alterations in combination with psychological complaints. The exact etiology of IBS is not fully understood, however it seems that gut-brain dysfunction is the predominant cause.

**CASE PRESENTATION:** The patient is an 18-year-old student and athlete who presented with severe muscular and joint pain, abdominal cramps, constipation alternating with diarrhea, headache and concentration difficulties. Initially, he was referred to a rheumatologist who suspected arthropathy and inflammatory bowel disease, which was ruled out with complete blood count, C-reactive protein and fecal calprotectin being normal and negative tTG serology. A gastroenterologist ruled out IBD and, in accordance to Rome IV criteria confirmed IBS with fibromyalgia. Due to the symptoms being so intensive, the patient didn't believe in a diagnosis of IBS. He sought help from two other gastroenterologists and a neurologist who did extensive investigations (intestinal ultrasound, colonoscopy, MR enterography, neurological tests and brain MRI) to rule out chronic enteropathy and neurologic disease. The patient started with antispasmodic treatment and a six-week low FODMAP diet resulting in no improvement. On the contrary, fatigue and arthralgia were worse. The patient initially refused to see a psychiatrist, but eventually psychological evaluation found anxiety and depression due to an unfulfilled sports career. He was helped with prolonged tricyclic antidepressant (TCA) treatment and cognitive behavioural therapy (CBT). **CONCLUSION:** Psychological disturbance was the cause of severe IBS. Antispasmodic treatment and diet changes were unsuccessful without extensive psychiatric treatment. Diagnostics and treatment for IBS can be demanding.



## CR07 Breaking the Boundaries: A Case of Humerus Reconstruction using a Fibula Autograft

Lovro Mikulić<sup>a</sup>, Lea Hasnaš<sup>a</sup>, Tomislav Sečan<sup>b</sup>

<sup>a</sup> School of Medicine, University of Zagreb, Zagreb, Croatia

<sup>b</sup> Department of Surgery, University Hospital Centre Zagreb, Zagreb, Croatia

DOI: <https://doi.org/10.26800/LV-145-supl2-CR07>

 Lovro Mikulić 0009-0004-4784-8399, Lea Hasnaš 0009-0004-4456-0605, Tomislav Sečan 0000-0001-5627-800X

**KEYWORDS:** Bone Transplantation; Fibula; Humeral Fracture

**INTRODUCTION/OBJECTIVES:** The treatment of fractures, refractures, and bone nonunions with avascular segments of osteoporotic bones still represents a problem in surgical practice. The major concerns are the biological potential and biomechanical instability of the bone. Therefore, new osteosynthetic techniques and implants are constantly being developed.

**CASE PRESENTATION:** A 71-year-old female patient was admitted to the ER with a comminuted osteoporotic fracture of the right humerus caused by a low-altitude fall. Initially, she underwent closed reduction and humerus antegrade intramedullary nailing. After seven weeks the patient suffered refracture and the implant had to be surgically removed due to irritation. Postoperatively, the patient was immobilized using an extremity cast splint. After nine weeks, a follow-up X-ray showed dislocated avascular bone fragments without radiological signs of bone healing, indicating the need for revision surgery. Therefore, it was decided to isolate the segment of the patient's right fibula and use it as a structural autograft for bone reconstruction. Open refracture reduction and extramedullary osteosynthesis were performed. To further promote bone healing, an autospangioplasty using the tissue of the right iliac crest was performed during the same procedure. The patient was discharged, and eight weeks later, radiological signs of bone healing were observed. The patient was pain-free, with a satisfactory outcome and function of the right arm.

**CONCLUSION:** The distal part of the fibula is not a key weight-bearing portion of the lower extremity, making it an ideal choice for treating humeral shaft fractures in older, less demanding patients, especially when adequate bone allograft is not available.

## CR08 Cardiogenic Shock Necessitating Extracorporeal Membrane Oxygenation In a Previously Healthy Child

Zara Gumzej<sup>a</sup>, Alan Ćurković<sup>a</sup>, Filip Rubić<sup>b</sup>

<sup>a</sup> School of Medicine, University of Zagreb, Zagreb, Croatia

<sup>b</sup> Division for Pediatric Intensive Care Unit, Department of Pediatrics, University Hospital Centre Zagreb, Croatia

DOI: <https://doi.org/10.26800/LV-145-supl2-CR08>



 Zara Gumzej 0000-0002-7703-4044, Alan Ćurković 0009-0001-5456-3365, Filip Rubić 0009-0002-8627-133X

**KEYWORDS:** COVID-19; Extracorporeal Membrane Oxygenation; Pediatric Multisystem Inflammatory Disease, COVID-19 Related; Shock, Cardiogenic

**INTRODUCTION:** Multisystem inflammatory syndrome in children (MIS-C) is a hyperinflammatory complication of SARS-Cov2 infection. While early reports insinuated less severe infections in pediatric populations, MIS-C is becoming a more recognized clinical manifestation. Cardiac involvement is common, although severe cases requiring extracorporeal membrane oxygenation (ECMO) remain infrequent.

**CASE PRESENTATION:** A previously healthy 8-year-old male presenting with dyspnea, cyanosis, bradycardia, profuse emesis, epigastric pain, and fever (39.7°C) was admitted to the pediatric ICU for suspected cardiogenic shock. Due to rapid deterioration, intubation and resuscitation were performed, with the return of spontaneous circulation quickly achieved. Despite corrective measures and administration of dopamine and norepinephrine, the patient remained hypotensive and anuric in deep lactic acidosis. Echocardiogram confirmed suspected fulminant myocarditis with valvulitis, regurgitation on AV valves (TR III, MR III), and significantly reduced systolic function of the left ventricular myocardium (EF 20%). To ensure hemodynamic stability, the decision was made to cannulate the patient for venoarterial-ECMO. RT-PCR for SARS-Cov2 was negative; however, previous infection was subsequently confirmed through IgG seropositivity. According to WHO guidelines, the patient fulfilled the criteria to confirm the development of MIS-C. Therapy was carried out with intravenous immunoglobulins, methylprednisolone, and supportive intensive care measures. Due to the gradual recovery of systolic function, he was weaned from ECMO on day eight and extubated two days later.

**CONCLUSION:** MIS-C remains a rare but serious complication of SARS-Cov2 infections that may have initially been mild or asymptomatic in pediatric patients. Early recognition and appropriate supportive care play a critical role in reducing the long-term externalities of MIS-C.

**CR09 Cardiotoxicity caused by gemcitabine**Marat Gripp<sup>a</sup>, Anastasia Fatyanova<sup>a</sup>, Irina Babkova<sup>a</sup>, Yuri Isaakyan<sup>a</sup>, Ilona Sarukhanyan<sup>a</sup><sup>a</sup> Department of Oncology, Radiotherapy and Reconstructive Surgery, I.M. Sechenov First Moscow State Medical University of the Ministry of Health of the Russian Federation (Sechenov University)DOI: <https://doi.org/10.26800/LV-145-supl2-CR09> Marat Gripp 0000-0003-2179-3671, Anastasia Fatyanova 0000-0002-5004-8307, Irina Babkova 0000-0002-9403-0563, Yuri Isaakyan 0000-0002-7614-2836, Ilona Sarukhanyan 0000-0002-6931-2649**KEYWORDS:** cardiotoxicity; chemotherapy; gemcitabine**INTRODUCTION/OBJECTIVES:** The use of anticancer drugs leads to the development of various adverse effects, particularly cardiovascular complications. Cardiotoxic effects are awaited, using pyrimidine antimetabolites. Gemcitabine, though being a representative of pyrimidine antagonist group, is considered to have minimal cardiotoxicity. We present the case of a patient with pancreatic cancer and takotsubo syndrome on gemcitabine monotherapy.**CASE PRESENTATION:** A 61-year-old female patient got treatment for stage IV T2N2M1 pancreatic tail cancer, adenocarcinoma G2 with peritoneal carcinomatosis, hepatic metastasis. She has no anamnesis of any cardiovascular disease. She was on monochemotherapy with Gemcitabine 1000 mg/m<sup>2</sup> intravenously on days 1/8/15. She got the 1st cycle of chemo, which was well tolerated. Nevertheless, soon after the last 3rd infusion of the second cycle (1800mg) the patient's condition dramatically worsened (tachycardia, hypotension). Electrocardiography: paroxysmal atrial fibrillation with transient right bundle branch block (was treated by injection of amiodarone). Echocardiography: reduced left ventricular ejection fraction, right heart dilatation, tricuspid regurgitation. Cardiogenic shock was caused by acute cardiotoxicity. The patient's condition was stabilized; further condition was complicated by multiorgan ischemic injuries, which made further chemotherapy impossible.**CONCLUSION:** Gemcitabine is considered to be minimally cardiotoxic compared to other members of the antimetabolite group. Our observation is a rare described case, however, the analysis of the literature allows to conclude that the rate of cardiotoxic reactions during gemcitabine therapy is comparable with other antitumor drugs. Only nonspecific electrocardiography changes can be detected during chemotherapy, which requires more attention to such patients. The use of anticancer antimetabolites necessitates careful monitoring of cardiovascular adverse events.**CR10 CHALLENGING MANAGEMENT OF SEVERE MYOCARDITIS WITH COMPLETE RECOVERY – a case report**Jelena Koprivica<sup>a</sup>, Jure Samardžić<sup>a,b</sup><sup>a</sup> School of Medicine, University of Zagreb, Zagreb<sup>b</sup> Department for Cardiovascular Diseases, University Hospital Centre Zagreb, Zagreb, CroatiaDOI: <https://doi.org/10.26800/LV-145-supl2-CR10> Jelena Koprivica 0009-0001-0098-9133, Jure Samardžić 0000-0002-9346-6402**KEYWORDS:** cardiogenic shock; extracorporeal membrane oxygenation; heart failure; myocarditis; ventricular assist device**INTRODUCTION/OBJECTIVES:** Cardiogenic shock has a high mortality rate (up to 60%). Different respiratory and mechanical circulatory support (MCS) is sometimes needed in treating these critically ill patients. We present a young patient with severe acute myocarditis and cardiogenic shock successfully treated to full recovery which required different extracorporeal membrane oxygenation (ECMO) configurations and a percutaneous left ventricular assist device (LVAD).**CASE PRESENTATION:** A previously healthy 21-year-old male was hospitalized in a local hospital after three weeks of intermittent fever, chest pain, cough and dyspnea. He was diagnosed with myopericarditis. Four days later his condition deteriorated to cardiogenic shock and cardiopulmonary arrest. He was successfully resuscitated and put on veno-arterial (VA) ECMO and mechanical ventilation (MV). Two days later he was transferred to our institution for further treatment. Echocardiography revealed severely reduced left ventricular (LV) ejection fraction (20%) and chest X-ray showed right-side pneumonia and "ECMO" lungs, confirmed by right-heart catheterization with severely elevated pulmonary capillary wedge pressure. A percutaneous LVAD was placed to unload LV. Thereafter, reconfiguration to V-A-V ECMO was required because of Harlequin syndrome development. Following sufficient recovery, ECMO was switched to V-V configuration. On 8th day of MCS he was weaned from ECMO, and from LVAD and MV the following day. His heart function and general condition recovered completely. On the 31st day of hospitalization he was discharged home.**CONCLUSION:** Severe heart failure management may require different MCS systems. Intensive contemporary care and timely referral of selected patients to experienced centers can improve outcomes and save lives.


## CR11 Congenital intrathoracic hiatal herniation of left-sided abdominal organs in an adult woman

Krunoslav Budimir<sup>a</sup>, Tomislav Brajković<sup>a</sup>, Valentina Ratkajec<sup>b</sup>, Tajana Pavić<sup>a,b</sup>

<sup>a</sup> School of Medicine, University of Zagreb, Zagreb

<sup>b</sup> Department of Gastroenterology and Hepatology, Sestre milosrdnice University Hospital Center, Zagreb, Croatia

DOI: <https://doi.org/10.26800/LV-145-supl2-CR11>

 Krunoslav Budimir 0000-0002-7738-0326, Tomislav Brajković 0009-0009-9269-5885, Valentina Ratkajec 0000-0002-5393-0792, Tajana Pavić 0000-0002-0370-5001

**KEYWORDS:** colonoscopy; CT colonography; hematochezia; hernia

**INTRODUCTION/OBJECTIVES:** Bochdalek hernia represents a rare condition accounting for 0,17-6% of all diaphragmatic hernias due to failure of pleuroperitoneal membrane closure in utero causing incompetence of posterolateral foramina to fuse properly. Clinical manifestations often arise in children, especially on the left side. Infrequently, it can go undiagnosed until its symptomatic presentation in adulthood or even being asymptomatic incidental multi-sliced computed tomography (MSCT) finding.

**CASE PRESENTATION:** A 27-year-old female patient has been referred for occasional pain in the left shoulder, left hypochondrium, and umbilicus that was initially described in 2014 during college admission but recently has become more frequent with higher intensity. The pain was accompanied by occasional right mandibular stiffness and could have been resolved with non-steroidal anti-inflammatory drugs. Hematochezia and post-defecation pain were also reported and attributed to a doubtful anal fissure. In previous years, she underwent an extensive, but inconclusive medical evaluation including orthopedic, psychiatric, allergological, and partial GI. During the actual GI assessment, a colonoscopy was attempted but could not be completed because of the severe abdominal and shoulder pain. Subsequent CT colonography revealed elongated descending and part of the transverse colon with spleen and left kidney situated almost adjacent to the left pulmonary apex. Finally, she underwent a surgical procedure consisting of a left posterolateral thoracotomy with diaphragmatic hernioplasty.

**CONCLUSION:** Even though Bochdalek hernia is a rare entity, it should be kept in mind when we evaluate patients with non-specific symptoms of longer duration. Despite an incomplete colonoscopy, evaluation of pain and GI hemorrhage should be finalized by radiological examination.


## CR12 A Case of Severe Epstein-Barr Virus Encephalitis in a Child

Barbara Mikuc<sup>a</sup>, Tena Matek<sup>a</sup>, Lorna Stemberger Marić<sup>b</sup>

<sup>a</sup> School of Medicine, University of Zagreb, Zagreb, Croatia

<sup>b</sup> Department for Paediatric Infectious Diseases, University Hospital for Infectious Diseases "Dr. Fran Mihaljević", Zagreb, Croatia

DOI: <https://doi.org/10.26800/LV-145-supl2-CR12>

 Barbara Mikuc 0000-0001-9357-6495, Tena Matek 0000-0001-6464-8154, Lorna Stemberger Marić 0000-0001-5523-0426

**KEYWORDS:** barbiturate coma; encephalitis; Epstein-Barr virus; status epilepticus

**INTRODUCTION/OBJECTIVES:** Epstein-Barr virus usually causes mild and self-limiting infections in children and adolescents. Infectious mononucleosis is the most common clinical manifestation but neurologic complications, such as encephalitis, occur in up to 8% of patients.

**CASE PRESENTATION:** A 10-year-old girl was admitted with fever persisting for 6 days, GAS negative acute tonsillopharyngitis and decreased level of consciousness. Shortly after admission, she suffered a tonic seizure that progressed to refractory status epilepticus. To control the seizure, she was treated with levetiracetam and had to be placed in a barbiturate coma. Laboratory results suggested acute mononucleosis and serology confirmed a primary EBV infection with positive IgM VCA (viral capsid antigen) and EA (early antigen) antibodies. Cerebrospinal fluid analysis revealed mild lymphocyte pleocytosis (25 cells/μl) but negative EBV antibodies. EBV DNA was detected in the blood using PCR (56 000 EBV copies/ml). Her EEG was abnormal with diffuse slowing and irregular wave patterns, while brain MRI showed cortical oedema and subcortical hyperintensities in the T2 sequence characteristic of acute encephalitis. Other common bacterial and viral causes of encephalitis were excluded. She was treated with intravenous acyclovir for EBV infection, received intravenous immunoglobulins, and started on methylprednisolone. Her neurologic status, motor, and cognitive functions improved, and she was discharged with only discrete neurocognitive impairments.

**CONCLUSION:** EBV can cause a variety of neurologic complications. Our patient had a rare form of severe encephalitis during primary EBV infection presenting with refractory status epilepticus. These neurologic complications may also be immunologically mediated or occur during reactivations of the virus.




### CR13 AN UNCOMMON CLINICAL PRESENTATION OF DIROFILARIASIS IN A CHILD – A CASE REPORT

Viktoria Knežević<sup>a</sup>, Ivan Petračić<sup>b</sup>, Anto Pajić<sup>b</sup>, Andro Gliha<sup>b</sup>, Stjepan Višnjić<sup>b</sup>

<sup>a</sup> School of Medicine, University of Zagreb, Zagreb, Croatia

<sup>b</sup> Department of Surgery, Children's Hospital Zagreb, Zagreb, Croatia

DOI: <https://doi.org/10.26800/LV-145-supl2-CR13>

 Viktoria Knežević 0009-0004-7237-7242, Ivan Petračić 0000-0002-3793-8620, Anto Pajić 0009-0002-8819-6468, Andro Gliha 0000-0002-7948-3126, Stjepan Višnjić 0000-0001-5442-0180

KEYWORDS: Child; Dirofilariasis; Epididymitis

**INTRODUCTION/OBJECTIVES:** Dirofilariasis is a zoonotic infection caused by filarial nematodes of the genus *Dirofilaria*, with *D. repens* as the most common one. Definitive hosts are usually dogs and other carnivores, while humans are accidentally included into the epizootic chain. It usually manifests as subcutaneous or ocular localization and here we present an unusual case of scrotal dirofilariasis.

**CASE PRESENTATION:** A 9-year-old boy presented to the emergency department with sudden onset of right-sided testicular pain that radiated to the right abdomen. There was no fever, nausea or vomiting. Physical examination showed no scrotal redness or swelling. Palpation revealed a slightly painful upper part of the right testicle. Abdomen was soft, non-tender without distention. Laboratory tests of blood and urine were within normal limits. Upon ultrasound examination of the right testicle, sharply delineated heterogeneous mass with a size of 10mm and minimal vascularity was visualized. Ultrasound finding followed by anamnesis of relapses of epididymitis were indication for exploration and surgical removal of the mass. Histological microscopic examination of the lesion showed cross-sections of nematode belonging to *Dirofilaria* spp. The postoperative period was uneventful and no other localization of dirofilariasis was found.

**CONCLUSION:** This report shows a young patient without travel history to the endemic areas, therefore the pathway of infection remains unclear. Even though Dirofilariasis or any parasitic infection is an extremely rare cause of testicular mass, it is necessary to consider them in differential diagnosis, especially when it is often misdiagnosed as a malignancy.


### CR14 An unusual case of anemia and intestinal obstruction caused by a benign duodenal tumor

Klara Brekalo<sup>a</sup>, Ivan Borlinić<sup>a</sup>, Maja Cvitanović<sup>a</sup>, Tajana Filipec Kanižaj<sup>b</sup>

<sup>a</sup> School of Medicine, University of Zagreb, Zagreb, Croatia

<sup>b</sup> Gastroenterology and hepatology department, Clinical Hospital Merkur, Zagreb, Croatia

DOI: <https://doi.org/10.26800/LV-145-supl2-CR14>

 Klara Brekalo 0009-0008-3636-008X, Ivan Borlinić 0009-0005-7571-3712, Maja Cvitanović 0009-0002-7421-9964, Tajana Filipec Kanižaj 0000-0002-7025-0932

KEYWORDS: Anaemia; duodenal neoplasms; gastrointestinal hemorrhage; intestinal obstruction; pancreaticoduodenectomy

**INTRODUCTION/OBJECTIVES:** The duodenum is rarely affected by neoplasms with less than 5% of gastrointestinal tumors being found in the small intestine. Nevertheless, they can be of great clinical significance. Usual symptoms include abdominal pain, acid reflux, constipation, and melena. While upper gastrointestinal bleeding is relatively frequent and occurs in around 100 per 100,000 adults per year, duodenal tumors are one of its rarest causes. The most common benign duodenal tumors are adenomas, followed by lipomas, haemangiomas, and leiomyomas.

**CASE PRESENTATION:** A 60-year-old woman presented with severe symptomatic normocytic anemia (Hgb 58 g/L) and melena lasting three days. She received three doses of packed red cells to which she responded well, with Hgb rising to 90 g/L. An urgent esophagogastroduodenoscopy was performed and a large obstructive polypous mass was found in the distal segment of the duodenum. Pathohistological analysis of the mass was inconclusive, but a leiomyoma or inflammatory fibroblastic tumor was suspected. An expansive intraluminal mass, 5 cm in diameter, in the distal segment of the duodenum was verified via MSCT. Since it could not be removed endoscopically, a pancreatoduodenectomy, more commonly known as Whipple's procedure, was successfully performed.

**CONCLUSION:** Duodenal tumors are rare and not often considered when a patient presents with upper gastrointestinal bleeding. Other symptoms include abdominal pain, acid reflux, constipation, and weight loss. They can be diagnosed and treated endoscopically, but they may require surgical treatment if endoscopic removal is not possible.


### CR15 Approach to Buschke-Löwenstein tumor associated with malignant transformation

Patricia Barić<sup>a</sup>, Drago Baković<sup>a</sup>, Antonia Alfirević<sup>a</sup>, Suzana Ljubojević Hadžavdić<sup>a,b</sup>

<sup>a</sup> School of Medicine, University of Zagreb, Zagreb, Croatia

<sup>b</sup> Department of Dermatology and Venereology, University Hospital Centre Zagreb, Zagreb, Croatia

DOI: <https://doi.org/10.26800/LV-145-supl2-CR15>

 Patricia Barić 0000-0002-7507-4149, Drago Baković 0000-0001-6674-6735, Antonia Alfirević 0000-0003-1339-5294, Suzana Ljubojević Hadžavdić 0000-0002-3640-9567

**KEYWORDS:** Buschke-Löwenstein tumor; Condylomata acuminata; Squamous cell carcinoma

**INTRODUCTION/OBJECTIVES:** Buschke-Löwenstein tumor (BLT) or giant condyloma is a verrucous infiltrating lesion, due to a sexually transmitted human papilloma virus. It appears benign histologically. Excision surgery with a broad incision is the preferred treatment. The aim of this paper is to report on a possibility of malignant transformation and treatment in such case.

**CASE PRESENTATION:** We present a 49-year-old man who had several verrucous condylomata acuminata on his penis shaft and a big verrucous growth in his right inguinal region that was clinically and histologically consistent with a Buschke-Löwenstein tumor, HPV type 6 and 8 positive. The diagnosis was made sixteen years ago and the patient had no history of any internal disease or medication that suppresses the immune system. He received electrocauterization treatment for genital warts on the penis shaft before being referred to a surgeon for additional care. The patient elected to disregard the growing mass, which then persisted for an additional decade. A deep biopsy was performed which was consistent with a diagnosis of verrucous squamous cell carcinoma. A computed tomography scan of the abdomen and pelvis revealed no local invasion, and there was no sign of inguinal lymphadenopathy. A wide local excision of the tumor mass was performed. As of now the patient had no recurrence.

**CONCLUSION:** BLT must be characterized as a condyloma acuminata-derived low grade in situ epithelial carcinoma. Since recurrences and potential recurring malignant transformation are a possibility, surgery is now the recommended course of action, with a focus on regular follow-ups.


### CR16 Arthritis as a presentation of paraneoplastic syndrome: A case report

Matea Lukić<sup>a</sup>, Ivan Prigl<sup>a</sup>, Dora Uršić<sup>b</sup>, Ana Marija Masle<sup>b</sup>

<sup>a</sup> Faculty of Medicine, Josip Juraj Strossmayer University of Osijek, Osijek, Croatia

<sup>b</sup> Department of Rheumatology, Clinical Immunology and Allergology, University Hospital Osijek, Osijek, Croatia

DOI: <https://doi.org/10.26800/LV-145-supl2-CR16>

 Matea Lukić 0000-0002-3530-8123, Ivan Prigl 0000-0002-8524-5407, Dora Uršić 0000-0002-9063-1433, Ana Marija Masle 0000-0001-6687-8500

**KEYWORDS:** adenocarcinoma; arthritis; paraneoplastic syndrome

**INTRODUCTION/OBJECTIVES:** Paraneoplastic syndrome includes symptoms that occur far from the primary tumor, and despite unclear pathogenesis, these conditions are thought to be caused by substances secreted by the neoplasm or by the effect of antibodies directed at the tumor, which cross-react with other tissues.

**CASE PRESENTATION:** We present a 70-year-old patient who was referred to the Emergency department by a dermatologist for skin changes and additional examination. For the past three months, she has had papules, papulopustules and ulcerations that itch, especially at night, and are visible on both lower legs, arms and torso; swelling of both ankles was also present. She complains of musculoskeletal pain in the whole body for the past year and says she noticed 10 kilograms weight loss in the last few months. Patient wasn't febrile, denied nausea, vomiting and abdominal pain. Vasculitis was suspected and the patient was admitted to the Department of rheumatology, clinical immunology and allergology. At the time of admission, laboratory findings verified microcytic anemia with elevated inflammatory parameters (erythrocytes 3.62[x10<sup>12</sup>/L], hemoglobin 80[g/L], MCV 76.2[fL], CRP(s) 18.8[mg/L]), because of which the patient received two doses of erythrocyte concentrate. Due to microcytic anemia, gastroscopy was indicated, during which an infiltrating process suspicious for a neoplasm was seen in the cardia, which extends to the gastroesophageal junction. A biopsy was performed and the pathohistological results showed adenocarcinoma.

**CONCLUSION:** Malignant diseases can have unusual clinical presentation. In elderly patients without a family history of rheumatological diseases, with new-onset arthritis and symptoms suggestive of malignancy, additional treatment should be performed.


## CR17 Beyond the Ear: Complications Following Otitis Media

Tian Košar<sup>a</sup>, Ana Klobučar<sup>a</sup>, Andro Košec<sup>a,b</sup>

<sup>a</sup> School of Medicine, University of Zagreb, Zagreb, Croatia

<sup>b</sup> Department of Otorhinolaryngology and Head and Neck Surgery, University Hospital Center Sestre milosrdnice, Zagreb, Croatia

DOI: <https://doi.org/10.26800/LV-145-supl2-CR17>

 Tian Košar 0009-0006-6158-251X, Ana Klobučar 0009-0001-9059-1064, Andro Košec 0000-0001-7864-2060

**KEYWORDS:** cholesteatoma; mastoidectomy; mastoiditis; otitis media

**INTRODUCTION/OBJECTIVES:** Chronic otitis media (COM) is a prevalent condition typically characterized by recurrent ear infections and inflammation. It can result in a variety of serious complications, such as cholesteatoma, mastoiditis, meningitis, and brain abscess. Left untreated, the cholesteatoma can erode the surrounding bone and lead to irreversible hearing loss, balance problems, and facial nerve paralysis. Mastoiditis, an inflammation of the mastoid bone, causes severe pain, fever, and swelling, and can lead to a life-threatening infection of the surrounding tissues. Brain abscess can cause headaches, fever, and seizures, and might result in permanent neurological damage or death.

**CASE PRESENTATION:** A 64-year-old male patient was admitted to the ENT department for right COM complicated by mastoiditis. Three months prior, the patient was treated for right OM causing brain abscess in the right temporal lobe. During that period, he developed Enterococcus sepsis and acute respiratory distress syndrome caused by SARS-CoV-2. Following these events, he was transferred to University Hospital for Infectious Diseases, a right temporal craniotomy was performed, and a brain abscess was evacuated. Despite the treatment, mastoiditis persisted and radical tympanomastoidectomy with retroauricular approach was performed. From the middle ear, accumulated detritus and cholesteatoma were evacuated. The remaining bone defects were filled with Bonalive granules. The procedure was successful and postoperative recovery was uneventful.

**CONCLUSION:** This case report emphasizes the importance of early recognition and starting treatment of COM to prevent potential complications and improve outcomes for patients. Maintaining a high index of suspicion is essential for prompt diagnosis of complications following COM.


## CR18 Carcinoma of the parathyroid gland: a case report

Matea Kostić<sup>a</sup>, Andrea Kostić<sup>a</sup>, Maja Baretić<sup>a,b</sup>

<sup>a</sup> School of Medicine, University of Zagreb, Zagreb, Croatia

<sup>b</sup> Division of Endocrinology, Department of Internal Medicine, University Hospital Centre Zagreb, Zagreb, Croatia

DOI: <https://doi.org/10.26800/LV-145-supl2-CR18>

 Matea Kostić 0000-0002-1546-7485, Andrea Kostić 0000-0003-0686-2616, Maja Baretić 0000-0002-7242-8407

**KEYWORDS:** Hypercalcemia; Hyperparathyroidism; Parathyroid Neoplasms

**INTRODUCTION/OBJECTIVES:** Carcinoma of the parathyroid gland causes 0.005% of all malignancies. Although the etiology remains unknown, possible contributing factors include neck radiation, chronic secondary hyperparathyroidism due to kidney failure, and vitamin D deficiencies. It occurs in syndromes such as hyperparathyroidism-jaw tumor syndrome, multiple endocrine neoplasia types 1 and 2A, and familial isolated hyperparathyroidism.

**CASE PRESENTATION:** The patient is a 63-year-old woman who has had hypercalcemia for three years, followed by nephrolithiasis, hypertension, and osteoporosis. She underwent radiotherapy and chemotherapy for sarcoma of the femur. Laboratory results showed that the level of calcium was 3.85 mmol/l, ionized calcium was 1.98 mmol/L, phosphorus was 0.56 mmol/L, and parathyroid hormone was greater than 150 pmol/L. Her bone x-ray showed typical features of osteitis fibrosa cystica. An ultrasound of the neck showed a 4-centimeter-large lower parathyroid gland. The patient underwent a left-side thyroid lobectomy and parathyroidectomy. Pathohistological results showed capsular invasion, extension to the connective tissue, and angioinvasion. After the surgery, the patient suffered severe hypocalcemia and was treated with calcium, calcitriol, and hydrochlorothiazide. Vitamin D and calcium supplements were long-term treatments. Follow-up was made throughout the year after surgery, and ultrasound and PET CT showed no signs of local recurrence of the disease.

**CONCLUSION:** Parathyroid gland carcinoma is a rare malignant disease. In this case, the patient had a history of long-standing hypercalcemia, followed by nephrolithiasis, osteitis fibrosis cystica, and hypertension. Carcinoma of the parathyroid gland should be considered in patients with such metabolic traits as marked hypercalcemia and hyperparathyroidism. The treatment is surgical.




## CR19 Functioning pituitary gonadotroph microadenoma responding to GnRH antagonist therapy: a case report

Petra Potreblica<sup>a</sup>, Velimir Altabas<sup>b</sup>

<sup>a</sup> School of Medicine, University of Zagreb, Zagreb, Croatia

<sup>b</sup> Institute of Endocrinology, Diabetes and Metabolic Diseases, University Hospital Center "Sestre milosrdnice", Zagreb, Croatia

DOI: <https://doi.org/10.26800/LV-145-supl2-CR19>

 Petra Potreblica 0000-0001-9232-8537, Velimir Altabas 0000-0002-9076-9870

**KEYWORDS:** degarelix; Pituitary Adenoma; Trisomy 22

**INTRODUCTION/OBJECTIVES:** Functioning pituitary gonadotropinomas are rarely described and comprise only a small portion of pituitary adenomas. Most of them are macroadenomas and cause endocrine dysfunctions usually presenting as either ovarian hyperstimulation, testicular enlargement or precocious puberty. Transsphenoidal resection is currently regarded as the treatment of choice, while other treatment options are considered ineffective and are rarely used.

**CASE PRESENTATION:** A 20-year old male patient with partial chromosome 22 trisomy was referred to the department of endocrinology for endocrine workup. Laboratory tests done revealed elevated serum levels of testosterone (34,6 nmol/L), LH (28,4 IU/L) and FSH (106,0 IU/L). Following these results, the patient underwent a pituitary MRI which showed a pituitary microadenoma measuring 3-4mm in diameter. Since the patient was suffering from multiple comorbidities due to partial trisomy of chromosome 22, adenomectomy was not an option due to increased perioperative risks. The patient was treated with degarelix (a GnRH antagonist) subcutaneously (80 mg sc. every 3 months). Consecutively, a significant decrease in serum testosterone levels (0,8 nmol/L), as well as in levels of LH (0,9 IU/L) and FSH (2,3 IU/L) was noticed. Repeated MRI scan showed no sign of the previously described microadenoma after one year of therapy.

**CONCLUSION:** Degarelix showed its effectiveness in reducing the size of the adenoma and subsequently lowering hormone levels, thus making GnRH antagonists a possible treatment option in similar cases.


## CR20 Intermittent claudications of the hand after supracondylar humeral fracture in a 2-year old boy

Nora Knez<sup>a</sup>, Karmen Jeričević<sup>a</sup>, Luka Kelčec<sup>a</sup>, Tomislav Vlahek<sup>b</sup>, Dino Papeš<sup>b</sup>

<sup>a</sup> School of Medicine, University of Zagreb, Zagreb, Croatia

<sup>b</sup> Department of Pediatric Surgery, University Hospital Center Zagreb, Zagreb, Croatia

DOI: <https://doi.org/10.26800/LV-145-supl2-CR20>


 Nora Knez 0000-0002-4933-4947, Karmen Jeričević 0000-0001-9296-4748, Luka Kelčec 0000-0002-6177-6692, Tomislav Vlahek 0000-0003-3805-1682, Dino Papeš 0000-0001-7241-9693


**KEYWORDS:** brachial artery; children; neurovascular injuries; supracondylar humeral fracture

**INTRODUCTION/OBJECTIVES:** Supracondylar humeral fractures (SHF) are the most common fractures associated with concomitant neurovascular injuries in children. Pink pulseless hand (PPH) labels SHF presenting without a pulse in a well-perfused hand. Management of PPH after successful SHF reduction remains controversial. Some advocate „watchful waiting”, whereas others favor early exploration. We present a case of a 2-year-old boy with PPH and intermittent claudications 6 weeks after successful SHF reduction.

**CASE PRESENTATION:** A boy sustained a completely dislocated SHF after a fall. Examination revealed partial loss of median nerve innervation and PPH, which persisted after closed reduction and percutaneous pinning. Postoperative radial artery Doppler showed biphasic arterial waveform and lower flow velocities. Six weeks after the injury, the hand was cold and pale during minimal straining, and the patient avoided using his hand. CT angiography showed a thrombosed segment of the brachial artery in the cubital fossa. Surgical exploration revealed thrombosis of the brachial artery and the median entrapped in the fracture. The thrombosed segment was resected, and the defect was reconstructed with a reversed cephalic vein graft. The nerve was freed, and the partial defect was reconstructed with direct sutures. The postoperative course was uneventful, with full recovery of hand function, elbow movement, innervation, and palpable radial pulses six months following the injury.

**CONCLUSION:** Although children with PPH after SHF do not require immediate brachial artery exploration, the absence of radial artery pulse several weeks after SHF requires careful follow-up and re-evaluation to avoid complications and ensure appropriate growth and function of the affected extremity.




**CR21 Juvenile idiopathic arthritis-associated uveitis**Matej Krišto<sup>a</sup>, Sandro Kukić<sup>a</sup>, Sanja Perić<sup>a,b</sup><sup>a</sup> School of Medicine, University of Zagreb, Zagreb, Croatia<sup>b</sup> Department of Ophthalmology, University Hospital Centre Zagreb, Zagreb, CroatiaDOI: <https://doi.org/10.26800/LV-145-supl2-CR21> Matej Krišto 0009-0005-1534-0416, Sandro Kukić 0000-0001-6425-1624, Sanja Perić 0000-0001-7965-6261

KEYWORDS: arthritis; synechia; uveitis

**INTRODUCTION/OBJECTIVES:** Juvenile idiopathic arthritis (JIA) is a rheumatic disease of unknown etiology that clinically presents by affecting one or more joints over a 6-week period. Uveitis is the most common extra-articular manifestation in children suffering from JIA. It is usually asymptomatic during the initial stages, and therefore screening for JIA-associated uveitis is crucial.

**CASE PRESENTATION:** A four-year-old girl was hospitalized in 2010, and examination revealed reduced visual acuity and posterior synechia of the right eye. The diagnosis of anterior uveitis was made, and first-line treatment with topical glucocorticoids and mydriatics was started. A month later, the patient had swelling in both knees and difficulty walking. She was diagnosed with JIA, which was cured with methotrexate and glucocorticoids. In July 2011, the patient had a relapse of arthritis and uveitis, which required immunomodulatory therapy with etanercept. From 2012 to 2013, she had two uveitis exacerbations that required use of the topical corticosteroids, resulting in secondary glaucoma and a cataract of the right eye. In 2014, a patient had uveitis exacerbation, and new immunomodulatory therapy with adalimumab was introduced. Swelling and pain in both knees occurred again in January 2018, and accordingly, the dose of adalimumab was increased until March 2020. She didn't have a relapse of uveitis from 2015 to 2022.

**CONCLUSION:** JIA-associated uveitis usually remains asymptomatic, and a delayed diagnosis can lead to extremely poor eyesight with no possibility of recovery. The interdisciplinary approach of pediatric rheumatologists and ophthalmologists is crucial for early diagnosis, achieving a successful therapy result, and maintaining visual acuity.

**CR22 Nature's Bandage: Exploring the Benefits of Amniotic Membrane Therapy**Lea Hasnaš<sup>a</sup>, Lovro Mikulić<sup>a</sup>, Tomislav Sečan<sup>b</sup><sup>a</sup> School of Medicine, University of Zagreb, Zagreb, Croatia<sup>b</sup> Department of Surgery, University Hospital Centre Zagreb, Zagreb, CroatiaDOI: <https://doi.org/10.26800/LV-145-supl2-CR22> Lea Hasnaš 0009-0004-4456-0605, Lovro Mikulić 0009-0004-4784-8399, Tomislav Sečan 0000-0001-5627-800X

KEYWORDS: Amnion; Biological Dressings; Wound Healing

**INTRODUCTION/OBJECTIVES:** The amniotic membrane is the innermost layer of the placenta. It consists of stem cells with reduced immunogenicity that secrete cytokines and growth factors, which have anti-inflammatory and antifibrotic effects and promote epithelialization. Membranes are obtained from women who are undergoing elective cesarean delivery. These allografts are typically used in ophthalmology for ocular surface reconstruction but have the potential for other applications, such as wound healing.

**CASE PRESENTATION:** A 72-year-old male was admitted to the ER with an elbow joint fracture and a large hematoma (size 20x10cm) of the anterolateral segment of the lower left leg caused by a fall from the stairs. The fracture was successfully treated, and the hematoma was evacuated and drained, followed by bandaging. Despite treatment, the wound didn't heal properly, resulting in skin necrosis and later ulcer formation, probably due to the patient's history of diabetes mellitus, the use of warfarin anticoagulant therapy, and corticosteroid therapy. Therefore, it was decided to promote the wound healing process with an amniotic membrane allograft. The wound was prepared with debridement and then covered with an amniotic allograft and a chronic wound dressing. After three days, new granulation tissue was observed. On follow-up office examination three months later, progressive epithelialization of the wound was noted, and there was a significant reduction in size.

**CONCLUSION:** Amniotic membrane allograft has proved beneficial in chronic wound healing. Overall, the biological properties and availability of amniotic membranes make a good foundation for expanding the treatment options for wounds in patients with comorbidities.


### CR23 Refractory ventricular fibrillation in a patient with ST-elevation myocardial infarction (STEMI)

Petra Relota<sup>a</sup>, Martina Periša<sup>a</sup>, Lorena Remenar<sup>a</sup>, Karla Schwarz<sup>a</sup>, Tomislav Letilović<sup>a,b</sup>

<sup>a</sup> School of Medicine, University of Zagreb, Zagreb, Croatia

<sup>b</sup> Department of Cardiology, Clinical Hospital Merkur, Zagreb, Croatia

DOI: <https://doi.org/10.26800/LV-145-supl2-CR23>

 Petra Relota 0000-0001-8660-6043, Martina Periša 0000-0001-6854-5080, Lorena Remenar 0000-0003-4560-015X, Karla Schwarz 0000-0001-9278-660X, Tomislav Letilović 0000-0003-1229-7983

**KEYWORDS:** Hypokalemia; Myocardial infarction; Ventricular fibrillation

**INTRODUCTION/OBJECTIVES:** Ventricular fibrillation (VF) is a life-threatening arrhythmia that can lead to sudden cardiac death by compromising cardiac output. It is a common complication of acute myocardial infarction (MI) due to the electrical instability of the myocardium. Refractory VF is defined as sustained VF that persists despite appropriate interventions. **CASE PRESENTATION:** A 52-year-old male with a history of arterial hypertension and smoking presented with symptoms of acute coronary syndrome (ACS) and was diagnosed with inferolateral ST-elevation myocardial infarction (STEMI). During the initial examination, the patient suffered cardiac arrest with ECG findings of VF and was promptly resuscitated and defibrillated multiple times. Percutaneous coronary intervention (PCI) was performed on the right coronary artery (RCA) with the insertion of two stents. During the two-hour procedure, the patient experienced recurrent and sustained VF, requiring multiple defibrillations. Laboratory results indicated the presence of hypokalemia despite acidosis and multiple defibrillations, both of which elevate potassium levels. This finding, along with a good response to the magnesium infusion treatment, suggests the possibility of torsades de pointes. Post-procedure, the patient's condition stabilized and he was admitted to the coronary intensive care unit. **CONCLUSION:** Hypokalemia can induce arrhythmias such as torsades de pointes, which can convert to VF. Acidosis is a common finding in post defibrillation time, but it is not usually linked to hypokalemia. The question remains if hypokalemia is the main reason for development of VF, but in all probability VF is caused by multiple factors including electrical instability of myocardium post MI.


### CR24 Renal artery stenting in a patient with renovascular hypertension

Lucija Čolaković<sup>a</sup>, Bruno Bumči<sup>a</sup>, Mia Edl<sup>a</sup>, Antonio Kovačević<sup>a</sup>, Tajana Turk<sup>a,b</sup>

<sup>a</sup> Faculty of Medicine, Josip Juraj Strossmayer University of Osijek, Osijek, Croatia

<sup>b</sup> Department of Diagnostic and Interventional Radiology, Clinical Hospital Center Osijek, Osijek, Croatia

DOI: <https://doi.org/10.26800/LV-145-supl2-CR24>

 Lucija Čolaković 0000-0002-0212-3843, Bruno Bumči 0009-0004-8981-1113, Mia Edl 0000-0002-7818-5741, Antonio Kovačević 0000-0003-2314-0279, Tajana Turk 0000-0003-1535-1359

**KEYWORDS:** endovascular procedure; renal artery stenosis; renovascular hypertension

**INTRODUCTION/OBJECTIVES:** Renal artery stenosis can be caused by fibromuscular dysplasia or, more often, atherosclerotic disease. It can result in hypertension, recurrent heart failure, pulmonary edema, acute coronary syndrome or progressive renal failure. Renal artery stenting is an interventional radiology procedure, which is performed in cases resistant to conservative treatment.

**CASE PRESENTATION:** A 38-year-old female patient was evaluated for resistant arterial hypertension, hypertensive pulmonary edema and renal insufficiency, resulting in frequent hospitalizations. Computed tomography (CT) angiography and color doppler imaging showed left main renal artery (anatomical variation with two left renal arteries) and right renal artery subocclusion. Dynamic renal scintigraphy revealed afunctional right kidney. Left renal artery endovascular stenting was proposed. The procedure was performed via right common femoral artery access under local anesthesia. Catheterization of left renal artery was performed, the subocclusion was crossed with the atraumatic wire and balloon expandable stent was placed across stenotic part. The postinterventional angiogram showed good arterial lumen with no residual stenosis. The patient was stable and discharged the following day with dual antiaggregation therapy in first 3 months, then acetylsalicylic acid lifelong. On the follow-up visit she no longer complained on any symptoms and was not hospitalized since.

**CONCLUSION:** Renal artery stenosis can cause secondary hypertension which can be resistant to conservative treatment, therefore stenting procedure is a potential alternative. Renal artery stenting is minimally invasive procedure which can result in improved renal status as well as hypertension management.




## CR25 Simultaneous Occurrence of Acute Myeloid Leukemia and Chronic Lymphocytic Leukemia: A Case Report

Stjepan Galić<sup>a</sup>, Ozren Jakšić<sup>a,b</sup>

<sup>a</sup> School of Medicine, University of Zagreb, Zagreb, Croatia

<sup>b</sup> Department of Hematology, University Hospital Dubrava, Zagreb, Croatia

DOI: <https://doi.org/10.26800/LV-145-supl2-CR25>

 Stjepan Galić 0000-0002-9150-7370, Ozren Jakšić 0000-0003-4026-285X

**KEYWORDS:** acute myeloid leukemia; chronic lymphocytic leukemia; hematology

**INTRODUCTION/OBJECTIVES:** Concurrent development of acute myeloid leukemia (AML) and chronic lymphocytic leukemia (CLL) is very rare. We present a case of simultaneous CLL and AML in a patient with no prior exposure to cytotoxic agents or irradiation.

**CASE PRESENTATION:** A 78-year-old female patient was admitted to the hospital with complaints of chest tightness and a dry cough. The physical exam revealed a systolic murmur, late inspiratory crackles in the left lung, discrete pretibial edema, and no organomegaly. The patient was subfebrile. Past medical history included diabetes type 2, hypertension, and osteoporosis. The chest X-ray revealed infiltrates and pleural effusion, suggesting pneumonia. The complete blood count revealed leukopenia ( $2 \times 10^9/L$ ), macrocytic anemia (hemoglobin of 87 g/L, MCV 102 fL), neutropenia ( $0.2 \times 10^9/L$ ), and a platelet count of  $332 \times 10^9/L$ . Bone marrow aspiration and biopsy revealed 36% of myeloblasts, which confirmed the diagnosis of AML. An additional leukemic population of cells was detected by immunophenotyping consistent with the diagnosis of CLL. MSCT scan revealed a minor pericardial effusion and no signs of lymphadenopathy or organomegaly. Venetoclax and azacitidine were started for the treatment of AML. Venetoclax, a bcl-2 antagonist, is effective for the treatment of both AML and CLL. The patient achieved remission of both AML and CLL and has been receiving continuous treatment for the past five years.

**CONCLUSION:** In conclusion, this case shows that targeting an important antiapoptotic pathway may lead to remission of both (unrelated) leukemias, i.e. hitting two targets with one arrow.

## CR26 Spontaneous pneumomediastinum and pneumopericardium in a young female: a case report


Mihovil Santini<sup>a</sup>, Lana Nikše<sup>b</sup>, Pavao Mioč<sup>b</sup>, Jakov Santini<sup>c</sup>, Iva Tokić<sup>a</sup>, Ivan Zeljković<sup>b</sup>

<sup>a</sup> Institute of emergency medicine of Krapina-Zagorje County, Krapina, Croatia

<sup>b</sup> Department of Cardiology, Sestre milosrdnice University Hospital Centre, Zagreb, Croatia

<sup>c</sup> School of Medicine, University of Zagreb, Zagreb, Croatia

DOI: <https://doi.org/10.26800/LV-145-supl2-CR26>

 Mihovil Santini 0000-0002-1428-4484, Lana Nikše 0000-0001-5755-1805, Pavao Mioč 0000-0001-5755-1805, Jakov Santini 0009-0003-1376-0957, Iva Tokić 0000-0002-7947-3577, Ivan Zeljković 0000-0002-4550-4056

**KEYWORDS:** Dyspnea; spontaneous; pneumomediastinum; pneumopericardium

**INTRODUCTION/OBJECTIVES:** Spontaneous pneumomediastinum (SPM) is a rare condition in young adults, usually affecting young healthy males with underlying pulmonary disease, which can be extremely rarely complicated with pneumopericardium (SPP).

**CASE PRESENTATION:** A 22-year-old female was admitted to the emergency department (ED) with an acute onset of dyspnea and severe pain in the left side of the neck, chest and left arm, especially when leaning forward. On admission, she was afebrile and physical examination revealed symmetric, clear breath sounds and almost inaudible heart beats without Hamman's sign. An arterial blood gas analysis revealed mild hypocapnia. An X-ray showed pneumomediastinum, and subsequent chest CT (computerized tomography) scan confirmed extensive pneumomediastinum with pneumopericardium up to 5 mm in thickness. She did not have any pre-existing pulmonary disease or other predisposing risk factors (heavy lifting, exercise, trauma). A chest CT scan showed no signs of pulmonary bullae, or any structural abnormalities in the bronchi or the esophagus. Echocardiography was done using subxiphoid projection, which was the only one revealing the heart, and showed no pathology and no hemodynamic repercussions from the SPP. The therapy was absolute bed rest, peroral analgesia and oxygen supply (4 L/min). During hospitalization, she was afebrile and no antibiotics were prescribed. The follow-up chest X-ray showed a complete resolution of pneumomediastinum and pneumopericardium and she was symptom free.

**CONCLUSION:** When evaluating a young adult who presents with dyspnea, it is important for emergency physicians to interpret the x-rays carefully in order to look for pathology like SPM if there is reasonable clinical doubt.


## CR27 Sub-inner limiting membrane haemorrhage successfully treated with pars plana vitrectomy – case report

Mislav Mokos<sup>a</sup>, Lorena Karla Rudež<sup>b</sup>, Tomislav Jukić<sup>a,b</sup>

<sup>a</sup> School of Medicine, University of Zagreb, Zagreb, Croatia

<sup>b</sup> Department of Ophthalmology, University Hospital Centre Zagreb, Zagreb, Croatia

DOI: <https://doi.org/10.26800/LV-145-supl2-CR27>

 Mislav Mokos 0000-0001-9319-9255, Lorena Karla Rudež 0000-0003-4332-3769, Tomislav Jukić

**KEYWORDS:** bevacizumab; perflutren; hemorrhage; vitrectomy

**INTRODUCTION/OBJECTIVES:** Preretinal haemorrhages typically occur at the boundary between the posterior hyaloid and inner limiting membrane (ILM). Sub-ILM haemorrhages have been observed in various clinical contexts and are likely to cause significant visual impairment due to their tendency to occur in the macular region. **CASE PRESENTATION:** A 73-year-old female patient presented to the emergency ophthalmological department with a curtain-like vision loss in her left eye lasting for five days. She used long-term warfarin therapy due to a previous pulmonary embolism. The dilated fundus exam of her left eye showed sclerotic vessels and a large macular haemorrhage. Fundoscopy of her right eye revealed sclerotic retinal vessels, cotton wool spots in the temporal region, and small hard drusen in the mediotretina. The ultrasound exam of her left eye showed an oval-shaped, solid elevation on the posterior pole of the retina with a base width of 5.4 mm and a height of 1.9 mm with the sclera, homogenous internal reflectivity, and collapsed vitreous body. Optical coherence tomography (OCT) was compatible with sub-ILM haemorrhage. Central vitrectomy was performed along with the application of triamcinolone. The ILM was detached, which was followed by the application of perfluoropropane and bevacizumab. Significant improvement has been observed 14 days after the treatment. **CONCLUSION:** Sub-ILM hemorrhage is an ophthalmologic emergency that is difficult to clinically differentiate from subhyaloid hemorrhage since the diagnosis is usually confirmed during the surgery. Sub-ILM hemorrhage is commonly treated by pars plana vitrectomy, which has been successfully used in our patient.


## CR28 Takotsubo cardiomyopathy (broken heart syndrome)

Doroteja Đekić<sup>a</sup>, Anja Ćuk<sup>a</sup>, Boško Skorić<sup>a,b</sup>

<sup>a</sup> School of Medicine, University of Zagreb, Zagreb, Croatia

<sup>b</sup> Department of Cardiovascular Diseases, University Hospital Centre Zagreb, Zagreb, Croatia

DOI: <https://doi.org/10.26800/LV-145-supl2-CR28>

 Doroteja Đekić 0000-0002-2811-4398, Anja Ćuk 0000-0002-5992-8327, Boško Skorić 0000-0001-5979-2346

**KEYWORDS:** chest pain; stress cardiomyopathy; Takotsubo cardiomyopathy; ventricular dysfunction

**INTRODUCTION/OBJECTIVES:** Takotsubo cardiomyopathy (TC), also known as stress cardiomyopathy is an uncommon disease characterized by acute left ventricle (LV) failure that mimics acute coronary syndrome (ACS) but lacking evidence of obstructive coronary artery disease. It is usually precipitated by severe emotional or physical stress although its pathophysiology is not yet fully known. Most patients are women past the age of 50. In-hospital mortality is 3-4%. **CASE PRESENTATION:** We present a case of a 70-year-old woman with a history of hypertension, stable angina pectoris and hyperlipoproteinemia. A day after Babcock-Cockett surgery for varicose veins was performed, she presented with sudden precordial pain and blood pressure of 190/130 mmHg. ECG showed ST-segment elevation in the precordial leads and negative T-waves in II, III and aVF. The patient was given a loading dose of aspirin and nitroglycerine. Urgent coronary angiography showed nonsignificant atherosclerotic lesions, while left ventriculogram demonstrated a systolic apical ballooning and hyperkinesis of the basal segments typical for TC. Global LV systolic function was severely reduced (EF 30%). Both serum troponin and NT-proBNP were increased. She was treated with aspirin, atorvastatin, fondaparinux and ramipril. The patient recovered and heart ultrasound 8 days later showed normalized global systolic LV function (EF 50%) with a small apical zone of hypocontractility. In her last heart ultrasound, 8 years later, LV function was still preserved. **CONCLUSION:** Although TC mimics the dramatic clinical presentation of ACS, it's characterized by transient regional LV dysfunction, the absence of significant coronary artery disease and is generally well managed with supportive therapy.


## CR29 Uncovering the Connection Between Stress and Cancer: A Case Report

Klara Dorešić<sup>a</sup>, Maja Grubeša<sup>a</sup>, Lara Fotez<sup>a</sup>, Lucija Galiot<sup>a</sup>, Jasmina Marić Brozić<sup>a,b</sup>

<sup>a</sup> School of Medicine, University of Zagreb, Zagreb, Croatia

<sup>b</sup> Department of Oncology and Nuclear medicine, Sestre milosrdnice University Hospital Centre, Zagreb, Croatia

DOI: <https://doi.org/10.26800/LV-145-supl2-CR29>

 Klara Dorešić 0000-0002-5043-6908, Maja Grubeša 0000-0001-7479-4569, Lara Fotez 0000-0002-4612-4274, Lucija Galiot 0000-0002-9613-7399, Jasmina Marić Brozić 0000-0002-5978-5960

**KEYWORDS:** Immunotherapy; lymphatic metastasis; melanoma

**INTRODUCTION/OBJECTIVES:** Many research studies show the connection between a previous stressful event and an increase in health problems. These usually include heart disease, diabetes, and hypertension. However, whether this could affect the immune system and be a trigger for developing carcinoma remains open for discussion.

**CASE PRESENTATION:** A 68-year-old male was admitted to the hospital in July 2018 due to a persistent fever without any additional symptoms. Two years ago, he was exposed to the traumatic event of his daughter dying in a car accident. A biopsy of the enlarged axillar lymph node was performed. The pathohistological finding discovered melanoma metastases. A dermatologic exam revealed one nodular tumorous growth on the right upper arm, that according to the patient had started to grow about two years ago. Excision was performed and a pathohistological work-out pointed to the metastatic lesion as well. The Positron Emission Tomography (PET CT) scan revealed lesions in lymphatic nodes of the neck, lungs, liver, and lumbar spine. Since the patient complained of pain in the lumbar spine, palliative bone radiotherapy was performed. After a multidisciplinary melanoma team meeting, immunotherapy with pembrolizumab was initiated. After 2 years of immunotherapy, complete resolution of signs and symptoms of the disease occurred and therefore the treatment was stopped, and the patient is alive now for 5 years.

**CONCLUSION:** In conclusion, the case report highlights the potential link between previous traumatic events and the development of health problems, including cancer. Further research is needed to fully understand the relationship between traumatic events and cancer development.


## CR30 Delayed Onset Of Acute Abdomen Revealing Foreign Body Ingestion

Ozana Miličević<sup>a</sup>, Tomislav Knotek<sup>a</sup>, Leo Matijašević<sup>a</sup>, Iva Barišić<sup>b</sup>

<sup>a</sup> Department of Emergency Medicine, University Hospital Centre Zagreb, Zagreb, Croatia

<sup>b</sup> Department of Emergency Medicine, General Hospital Zabok, Zabok, Croatia

DOI: <https://doi.org/10.26800/LV-145-supl2-CR30>

 Ozana Miličević 0000-0003-0289-3386, Tomislav Knotek 0009-0009-3113-8102, Leo Matijašević 0000-0002-7010-9111, Iva Barišić 0000-0003-2964-0901

**KEYWORDS:** Acute abdomen; Fistula; Foreign body

**INTRODUCTION/OBJECTIVES:** Foreign body ingestion is a common issue in the daily practice of dentistry and can lead to life-threatening complications such as intestinal obstruction, perforation, fistulas, peritonitis and sepsis. In the majority of cases, the foreign object will pass through the gastrointestinal tract without any complications, 10% of cases will require endoscopic treatment and in 1% of cases surgical removal is necessary.

**CASE PRESENTATION:** A 57-year-old female patient presented to the emergency department with right-sided abdominal pain radiating to her back, accompanied by nausea and a fever of 38°C. The patient's medical history included appendectomy and cesarean section. During the physical examination, palpation of the right hemiabdomen was painful with a positive Murphy sign and showed no signs of peritoneal irritation. Laboratory findings revealed leukocytosis and high levels of C-reactive protein. Cholecystitis was initially suspected but ruled out by a subsequent CT scan of the abdomen which revealed a duodenocolic fistula caused by a foreign body perforating through the intestinal wall. Further investigation revealed that the patient had undergone dental impressions taking 6 weeks ago, during which ingestion may have occurred. The emergent surgical procedure was planned and included duodenocolic fistula resection, right hemicolectomy and ileotransversal anastomosis. The patient was discharged from the hospital after 5 days in good clinical condition.

**CONCLUSION:** This case presents a rare example of dental material impression ingestion with initial symptoms appearing 6 weeks after ingestion. This highlights the importance of high caution, follow-up after foreign body ingestion and early recognition in the emergency department to prevent fatal outcomes.




### CR31 Diabetes Mellitus and diabetic ketoacidosis associated with pembrolizumab

Karla Lauš<sup>a</sup>, Hrvoje Centner<sup>a</sup>, Ema Schönberger<sup>b</sup>,  
Silvija Canecki-Varžić<sup>a,b</sup>

<sup>a</sup> Faculty of Medicine, Josip Juraj Strossmayer  
University of Osijek, Osijek

<sup>b</sup> Division of Endocrinology, Department of Internal  
Medicine, University Hospital Center Osijek, Osijek,  
Croatia

DOI: <https://doi.org/10.26800/LV-145-supl2-CR31>

 Karla Lauš 0009-0007-0511-1948, Hrvoje Centner  
0009-0005-9846-8780, Ema Schönberger 0000-0001-  
7605-7095, Silvija Canecki-Varžić 0000-0001-9535-  
7915

**KEYWORDS:** diabetes mellitus; diabetic ketoacidosis;  
pembrolizumab

**INTRODUCTION/OBJECTIVES:** Diabetic ketoacidosis (DKA) is an acute, life-threatening complication of diabetes mellitus (DM) and is characterized by hyperglycemia, hyperketonemia and metabolic acidosis. With the increasing use of immune checkpoint inhibitors (ICIs), such as pembrolizumab in cancer therapy, it's important to understand immune-related adverse events that comes with it.

**CASE PRESENTATION:** A 63-year-old female patient with no previous history of diabetes was admitted to endocrinology department due to new-onset DM representing with DKA. She presented with nausea and vomiting, while she started to experience polyuria and polydipsia, along with some suprapubic abdominal pain two weeks prior to admission. In June 2021 she was diagnosed with a sigmoid colon adenocarcinoma which was treated surgically. In February 2022 PET CT revealed liver metastases and metastasectomy was performed. Patient relapsed and in December 2022, a month before admission, she started treatment with FOLFIRI in combination with pembrolizumab. On the day of admission laboratory findings showed blood glucose level 56.8 mmol/L, urine positive for ketones, proteins, glucose and blood, and arterial blood pH of 7.125 and bicarbonates 7.4 mmol/L. Immediately after admission, intravenous fluids and insulin administration were started, along with potassium replacement, pantoprazole and metoclopramide. After DKA was resolved, subcutaneous insulin therapy was introduced and patient underwent education on diabetes management.


**CONCLUSION:** Development of DM and DKA, as well as difficulty achieving good glycemic control can be associated with current pembrolizumab therapy. Regular blood glucose monitoring during ICIs treatment has the potential of preventing development of acute diabetic complications.

### CR32 Dressler syndrome after myocardial infarction: a case report

Maja Alaber<sup>a</sup>, Tina Stanković<sup>a</sup>, Maša Sorić<sup>a</sup>

<sup>a</sup> Emergency Department, University Hospital Dubrava,  
Zagreb, Croatia

DOI: <https://doi.org/10.26800/LV-145-supl2-CR32>

 Maja Alaber 0009-0000-2090-1306, Tina Stanković  
0009-0004-5549-3292, Maša Sorić 0000-0002-5002-  
9800

**KEYWORDS:** Dressler syndrome, myocardial  
infarction, pericarditis

**INTRODUCTION/OBJECTIVES:** Dressler syndrome is a rare type of secondary pericarditis that occurs after the injury of the heart by a myocardial infarction (MI), chest trauma, or heart surgery. The symptoms of Dressler syndrome usually present one to six weeks after the myocardial infarction with pleuritic chest pain, fever, dyspnoea, and ECG changes. It is estimated that only 0,1% of patients who have had acute myocardial infarction develop Dressler syndrome.

**CASE PRESENTATION:** An 82-year-old male presented to the emergency department with moderate retrosternal chest pain, dyspnoea, fatigue and fever. Three weeks prior to the admission, the patient had undergone a percutaneous coronary intervention with implantation of two drug-eluting stents in the occluded LAD artery due to anteroseptal myocardial infarction. On the day of the admission, he was subfebrile (37,7°C). Physical examination showed no abnormalities. Laboratory test indicated slight leucocytosis (9,8x10<sup>9</sup>), neutrophilia (8,77x10<sup>9</sup>) and increased CRP (48,4 mg/L). Serial high-sensitive troponin levels were elevated (100,1 and 92,2) with no significant dynamic. ECG demonstrated persistent ST elevation that was present at discharge with new inverted T waves in precordial leads. Chest X ray was normal. Transthoracic echocardiogram revealed pericardial effusion of 5 mm in diameter around the right atrium and right ventricle with fibrin deposits. Diagnosis of post-myocardial infarction pericarditis, also known as Dressler syndrome, was made. The patient was discharged with peroral colchicine therapy.

**CONCLUSION:** This case report shows that, although very rare, Dressler syndrome should be considered as a possible cause in every post-MI patient presenting with chest pain, fatigue, and signs of inflammation.


### CR33 Drug - drug interaction in a patient with epilepsy and newly diagnosed paroxysmal atrial fibrillation

Klara Bardač<sup>a</sup>, Lucija Dafne Blažević<sup>a</sup>, Lucija Nevena Barišić<sup>a</sup>, Iveta Merćep<sup>b</sup>

<sup>a</sup> School of Medicine, University of Zagreb, Zagreb, Croatia

<sup>b</sup> Unit for Clinical Pharmacology, Department of Internal Medicine, University Hospital Centre Zagreb, Zagreb, Croatia

DOI: <https://doi.org/10.26800/LV-145-supl2-CR33>

 Klara Bardač 0000-0002-9231-5805, Lucija Dafne Blažević 0000-0001-6101-1326, Lucija Nevena Barišić 0000-0002-0645-5650, Iveta Merćep 0000-0003-2824-9222

**KEYWORDS:** anticoagulants; carbamazepine; cytochromes; phenobarbital

**INTRODUCTION/OBJECTIVES:** Cytochrome P450 isoenzymes have a major role in the metabolism of xenobiotics. They are mostly found in hepatocytes and oxidize majority of drugs, thus shifting them into their inactive form. Some of them can influence cytochromes' activity while getting oxidized, simultaneously inducing or inhibiting them. This way, drug activity can be altered and their benefit in the management of the disease limited.

**CASE PRESENTATION:** Female patient, age 73, had the diagnosis of epilepsy which had been well controlled with phenobarbital and carbamazepine for the last 40 years. In May 2022, she complained of palpitations and occasional perimaleolar edema of the left leg. A 24-hour-ECG showed paroxysmal atrial fibrillation and she was prescribed flecainide for rhythm control. Because of high CHAD-VASc score (4), edoxaban was initiated, but shortly after she was referred to a clinical pharmacologist for optimization of anticoagulation therapy which wouldn't interact with her antiepileptics. She was advised to change the antiepileptic therapy, what she refused, scared that her seizures wouldn't be under control anymore. Hence, the decision was to discontinue edoxaban therapy and initiate warfarin, but in doses 30 to 60 % higher than usual.

**CONCLUSION:** Phenobarbital and carbamazepine are strong inducers of CYP3A4 enzymes, which leads to more rapid metabolism and therefore reduced efficacy of NOACs and warfarin, both the substrates of that cytochrome. Even though warfarin is the better treatment option because of the possibility of monitoring its effectiveness through prothrombin time and calculation of INR, it still does not completely ensure the patient from systemic embolism and stroke.


### CR34 DYNAMIC LEFT INTRAVENTRICULAR OBSTRUCTION IN TAKOTSUBO CARDIOMYOPATHY IN A 62-YEAR-OLD WOMAN: A CASE REPORT

Stella Guštek<sup>a</sup>, Petra Nežić<sup>a</sup>, Mario Udovičić<sup>b</sup>

<sup>a</sup> School of Medicine, University of Zagreb, Zagreb, Croatia

<sup>b</sup> Department of Cardiology, University Hospital Dubrava, Zagreb, Croatia

DOI: <https://doi.org/10.26800/LV-145-supl2-CR34>


 Stella Guštek 0009-0002-5334-8206, Petra Nežić 0009-0003-5430-0666, Mario Udovičić 0000-0001-9912-2179

**KEYWORDS:** Broken Heart Syndrome; Left Ventricular Outflow Tract Obstruction; Stress Cardiomyopathy, Takotsubo Cardiomyopathy; Ventricular Dysfunction

**INTRODUCTION/OBJECTIVES:** Takotsubo cardiomyopathy (TTC), also known as the broken heart syndrome and stress cardiomyopathy, is a condition which results in left ventricular systolic dysfunction. It is mainly triggered by extreme emotional stress. Onset of LV outflow tract obstruction (LVOTO) during the acute phase of TTC is a rare but challenging complication that can lead to syncope.

**CASE PRESENTATION:** We report a case of a 62-year-old woman who was admitted to emergency department due to syncope after exposure to intense stress associated with work. ECG on presentation showed ST-segment elevation in precordial leads and elevated troponin values. She was admitted to coronary care unit. Transthoracic echocardiography (TTE) showed reduced left ventricular ejection fraction (LVEF) of 36% and apical ballooning of the left ventricle along with an intraventricular peak gradient of 68 mmHg detected by Doppler echocardiography. Coronary angiography excluded significant coronary heart disease, while ventriculography showed apical ballooning. The patient remained hemodynamically stable and asymptomatic. A week later, TTE was performed again and showed improved LVEF of 60% with a resolution of LVOTO and she was discharged from the hospital. Six months later patient remains well and asymptomatic.

**CONCLUSION:** Since symptoms of TTC mimic those of acute coronary syndrome, it is very challenging for physicians to diagnose this condition. Transitory LVOTO during the acute phase of TTC can complicate the clinical course of TTC patients, resulting in a syncope or even hemodynamic instability.


**CR35 Effectiveness of electroconvulsive therapy**Bruno Bumči<sup>a</sup>, Hanna Pašić<sup>b</sup>, Mia Edl<sup>a</sup>, Lucija Čolaković<sup>a</sup>, Antun Botica<sup>c</sup><sup>a</sup> Faculty of Medicine, Josip Juraj Strossmayer University of Osijek, Osijek, Croatia<sup>b</sup> Sestre milosrdnice University Hospital Centre, Zagreb, Croatia<sup>c</sup> School of Medicine, University of Zagreb, Zagreb, CroatiaDOI: <https://doi.org/10.26800/LV-145-supl2-CR35> Bruno Bumči 0009-0004-8981-1113, Hanna Pašić 0000-0001-9942-0838, Mia Edl 0000-0002-7818-5741, Lucija Čolaković 0000-0002-0212-3843, Antun Botica 0000-0003-0085-4973

KEYWORDS: electroconvulsive therapy; hypochondriacal neurosis; major depressive disorder

INTRODUCTION/OBJECTIVES: Electroconvulsive therapy (ECT) is a medical treatment in which the patient's brain is briefly electrically stimulated under anesthesia to induce a brief seizure. ECT is usually used when other treatments haven't worked. Although it is primarily used to treat patients with major depression, patients with other disorders may also benefit.

CASE PRESENTATION: The patient had been under psychiatric treatment since the 1990s with a diagnosis of hypochondriacal disorder and recurrent depressive disorder. The patient has been hospitalised at our clinic several times. This hospitalization, the patient was admitted to the department for intensive psychiatric treatment, where he was continuously observed and treated psychopharmacotherapeutically with titration of drug doses. After stabilization of the psychophysical condition, the patient was transferred to the department of Biological Psychiatry and Psychopharmacology, where he is included in psychosocial dynamic treatment programs. After diagnostic procedure according to the ECT protocol, signed informed consent and approval of the ethics committee, bilateral ECT with the "Thymatron System IV" was applied under general anesthesia on eight occasions. Ultrashort pulse stimuli were used. The power required to reach the neuromodulatory threshold was 15-40%. During each ECT application, spike-wave complexes of 5 to 80 seconds in duration were recorded by EEG. The patient was discharged home in a compensated psychophysical state, continuing regular psychopharmacotherapy.

CONCLUSION: This case demonstrates that ECT can be highly effective in treating episodes of severe mental illness, but that it does not prevent recurrence in the future. Therefore, most people treated with ECT need to receive some type of maintenance therapy.

**CR36 Electroconvulsive treatment of patients with treatment-resistant schizophrenia and empty sella syndrome: two case reports**Zrinka Vuksan-Ćusa<sup>a</sup>, Iva Radoš<sup>b</sup>, Eleonora Goluža<sup>a,c</sup>, Marina Šagud<sup>a,b</sup><sup>a</sup> School of Medicine, University of Zagreb, Zagreb, Croatia<sup>b</sup> Department for Psychiatry and Psychological Medicine, University Hospital Centre Zagreb, Zagreb, Croatia<sup>c</sup> Department of Anesthesiology, Reanimatology, and Intensive Medicine, University Hospital Centre Zagreb, Zagreb, CroatiaDOI: <https://doi.org/10.26800/LV-145-supl2-CR36> Zrinka Vuksan-Ćusa 0000-0002-4192-1485, Iva Radoš 0009-0003-6392-8973, Eleonora Goluža 0000-0001-6220-8614, Marina Šagud 0000-0001-9620-2181

KEYWORDS: electroconvulsive therapy; empty sella syndrome; treatment-resistant schizophrenia

INTRODUCTION/OBJECTIVES: Empty sella is the neuroradiological or pathological finding of an empty sella turcica containing no pituitary tissue. Even though empty sella syndrome (ESS) and schizophrenia are both relatively common in the general population, to the best of our knowledge, there is only one similar case report regarding the co-occurrence of those two conditions.

CASE PRESENTATION: We present two patients with empty sella findings on brain magnetic resonance imaging and with the diagnosis of treatment-resistant schizophrenia (TRS). A 50-year-old female who has had schizophrenia for 37 years was treated with olanzapine 20 mg, carbamazepine 800 mg and clozapine 500 mg daily, while a 33-year-old male with schizophrenia for 12 years was taking olanzapine 25 mg, promazine 300 mg, diazepam 30 mg, fluphenazine 4,5 mg and carbamazepine 600 mg daily. They both had severe psychopathology, including physical aggression, grossly disorganized behavior, hostility, overwhelming delusions and hallucinations, which required constant supervision. While all treatment options were ineffective for many months, electroconvulsive therapy (ECT) was indicated and the patients' symptoms subsided significantly after 12 treatments of ECT.

CONCLUSION: The relationship between TRS and ESS is completely unknown, given scarce literature reports so far. Our cases showed that the presence of empty sella was associated with the lack of response, but with unusually good tolerance to many antipsychotics in very high doses. This is also the second report on the use of ECT in those patients. According to this, ECT might be a safe and effective option in patients with TRS who have radiological findings of ESS.




### CR37 Emphysematous cystitis: a non-specific presentation

Ivan Borlinić<sup>a</sup>, Klara Brekalo<sup>a</sup>, Lucija Dafne Blažević<sup>a</sup>, Anna Braniša<sup>a</sup>, Delfa Radić-Krišto<sup>a,b</sup>

<sup>a</sup> School of Medicine, University of Zagreb, Zagreb, Croatia

<sup>b</sup> Division for Hematology, Department of Internal medicine, Clinical Hospital Merkur, Zagreb, Croatia

DOI: <https://doi.org/10.26800/LV-145-supl2-CR37>

 Ivan Borlinić 0009-0005-7571-3712, Klara Brekalo 0009-0008-3636-008X, Lucija Dafne Blažević 0000-0001-6101-1326, Anna Braniša 0009-0000-5568-2502, Delfa Radić-Krišto 0000-0002-2827-7808

KEYWORDS: Cystitis; sepsis; urinary tract infection

**INTRODUCTION/OBJECTIVES:** Emphysematous cystitis is a rare but serious urinary tract infection characterized by the presence of gas in the bladder wall and lumen, caused by gas-forming bacteria. This condition can lead to damage to the bladder wall, with possible rupture, sepsis, and death if left untreated. It is most commonly seen in older female patients and diabetics with multiple comorbidities.

**CASE PRESENTATION:** A 71-year-old woman presented to the ER with generalized weakness, dizziness, loss of appetite, vomiting and was afebrile with no dysuria at the time. She was a type II diabetic with heart failure and arterial hypertension and was hospitalized the previous month for investigation of a retrosternal mass, found to be a hematoma caused by the protrusion of a sternal cerclage wire following a triple CABG procedure. Upon admittance, MSCT showed pneumoperitoneum and pneumomediastinum, as well as emphysematous cystitis, and she was initially treated with ceftriaxone. In the following days, her kidney function deteriorated, progressing to anuria with metabolic acidosis within seven days, with septic shock as the probable cause. She also developed pneumonia with respiratory insufficiency, so dialysis and mechanical ventilation were initiated. Unfortunately, these steps were insufficient, and the patient died.

**CONCLUSION:** Emphysematous cystitis is an urgent and possibly life-threatening condition. Unfortunately, it often presents with symptoms atypical of a urinary tract infection, making it difficult to diagnose. For this reason, it is often found too late and as an accidental diagnosis during the investigation of other possible conditions.


### CR38 Endobronchial ultrasound-guided transbronchial fine needle aspiration (EBUS-TBNA): Solitary fibrous tumor of the mediastinum

Robert Gečević<sup>a</sup>, Darjan Ranilović<sup>b</sup>, Ivan Marasović<sup>b</sup>, Damir Vukoja<sup>b</sup>, Đivo Ljubičić<sup>b</sup>

<sup>a</sup> School of Medicine, University of Zagreb, Zagreb, Croatia

<sup>b</sup> Division of Pulmonology, Department of Internal Medicine, Clinical Hospital Dubrava, Zagreb, Croatia

DOI: <https://doi.org/10.26800/LV-145-supl2-CR38>

 Robert Gečević 0000-0002-8533-9788, Darjan Ranilović 0000-0003-3906-8646, Ivan Marasović 0000-0001-5332-0532, Damir Vukoja 0000-0002-7634-6644, Đivo Ljubičić 0000-0001-7071-9078

KEYWORDS: endoscopic ultrasound-guided fine needle aspiration; lymphoma, non-Hodgkin; mediastinal neoplasms; solitary fibrous tumors

**INTRODUCTION/OBJECTIVES:** A solitary fibrous tumor is a rare type of mesenchymal neoplasm with a described incidence of 1 new case in a million people a year. It is a slow-growing tumor that can arise almost anywhere in the body, usually with benign characteristics with little or no symptoms, until it grows big enough to cause symptoms of compression. In this case report we presented a patient with a rare case of a mediastinal solitary fibrous tumor.

**CASE PRESENTATION:** A 64-year-old male patient previously diagnosed with non-Hodgkin lymphoma was examined due to mediastinal lymphadenopathy of unknown origin, discovered after he had noticed a pressure in the left upper region of his chest accompanied with dyspnoea and severe cough. Initial MSCT investigations showed signs of bilateral hilar mediastinal lymphadenopathy which needed additional diagnostic evaluation. Accordingly, an endobronchial ultrasound-guided transbronchial needle aspiration (EBUS-TBNA) was performed. The results of the cytological analysis of 3 samples obtained from right hilar formation showed a suspected neoplastic finding. The patient underwent a thoracotomy in which the neoplasm was completely removed. Later histopathological evaluation described the specimen as a solitary fibrous tumor. A neoplastic formation which was on several occasions wrongly interpreted as non-Hodgkin lymphoma and primitive neuroectodermal tumor (PNET) was finally named correctly and treated successfully.

**CONCLUSION:** Solitary fibrous tumors are a rare group of histologically similar tumors that rarely form metastases. A multidisciplinary approach, accurate diagnosis, and treatment are essential to these patients, as solitary fibrous tumors can easily be misdiagnosed for other more common diseases and consequently treated inadequately.


### CR39 Endoscopic treatment of mediastinal pancreatic pseudocyst using lumen apposing metal stents - Case report

Sandro Kukić<sup>a</sup>, Dominik Kralj<sup>b</sup>, Tajana Pavić<sup>b</sup>

<sup>a</sup> School of Medicine, University of Zagreb, Zagreb, Croatia

<sup>b</sup> Department of Gastroenterology and Hepatology, Sestre milosrdnice University Hospital Centre, Zagreb, Croatia

DOI: <https://doi.org/10.26800/LV-145-supl2-CR39>

 Sandro Kukić 0000-0001-6425-1624, Dominik Kralj 0000-0001-6503-6870, Tajana Pavić 0000-0002-0370-5001

**KEYWORDS:** Alcoholic pancreatitis; Endoscopic ultrasonography; Pancreatic pseudocyst

**INTRODUCTION/OBJECTIVES:** Mediastinal pancreatic pseudocyst (PP) is a rare complication of acute alcoholic pancreatitis. Endoscopic drainage has become widely used in the management of PPs and novel lumen apposing metal stents (LAMS) could provide more effective treatment.

**CASE PRESENTATION:** We present a case of a 61-year-old male with a history of chronic alcoholic pancreatitis who was admitted to the hospital for dysphagia and excessive vomiting. Physical examination revealed no abnormalities and laboratory results showed moderately elevated inflammatory parameters. Esophagogastroduodenoscopy (EGD) was performed revealing a functional spasm of the esophagus, GERD, and chronic gastroduodenitis. Computed tomography (CT) scan revealed a polylobulated PP emerging from the pancreas and spreading through the esophageal hiatus into the mediastinum with a compressive effect on the ventrolateral part of the esophagus. Following endoscopic ultrasound (EUS) guided puncture of the PP with fine needle aspiration of cyst content for microbiological sampling, cystogastrostomy was performed using LAMS placement enabling drainage. Antibioqram-guided treatment was initiated for *Streptococcus viridans* which was isolated from the punctate. Follow-up imaging showed complete regression of the pseudocyst, along with a drop in inflammatory parameters and improvement of the general condition. LAMS was extracted one week after the procedure without significant complications.

**CONCLUSION:** To our knowledge, this is the first transgastric LAMS drainage of a mediastinal PP. Only two cases have been described in the literature so far and both used the transoesophageal approach. This shows LAMS drainage is feasible in various clinical scenarios.


### CR40 Exceptionally large juvenile xanthogranuloma – a case report

Luka Bulić<sup>a</sup>, Eva Brenner<sup>a</sup>, Suzana Ožanić Bulić<sup>b</sup>

<sup>a</sup> School of Medicine, University of Zagreb, Zagreb, Croatia

<sup>b</sup> Department of Pediatric Dermatology, Children's Hospital Zagreb, Zagreb, Croatia

DOI: <https://doi.org/10.26800/LV-145-supl2-CR40>

 Luka Bulić 0000-0001-6522-891X, Eva Brenner 0000-0002-6638-2967, Suzana Ožanić Bulić 0000-0002-1871-826X

**KEYWORDS:** child; juvenile xanthogranuloma; scalp

**INTRODUCTION/OBJECTIVES:** Juvenile xanthogranuloma (JXG) is a rare, benign skin lesion pathologically classified as a non-Langerhans cell histiocytosis. The lesions appear within the first year of life in 75% of patients, predominantly on the head or neck, growing up to 5mm in size. While the etiology is mostly infectious, it can also be caused by genetic variants. In most patients, the condition has an easy course and resolution. Histopathological features include a histiocytic invasion of the superficial dermis, with additional eosinophils, lymphocytes and plasma cells. The lesion typically stains with anti-CD4, anti-XIIIa and CD68 markers.

**CASE PRESENTATION:** A 1-year-old female patient was examined for a large, solitary scalp lesion with features of JXG. The lesion started as a yellow erythematous plaque, measuring 17x13mm in size. Histopathological analysis showed histiocytes and occasional foam cells, lymphocytes, macrophages and multinuclear giant cells in the dermis. Immunodiagnostic tests returned positive for CD68 and negative for S100 and CD1a, confirming JXG. The patient attended three follow-up appointments, at which substantial growth of the lesion was observed. At the last examination, it measured 40mm in diameter. Topical corticosteroids were applied but didn't affect the progression.

**CONCLUSION:** This case of JXG is set apart by the size of the lesion, which is eight times larger than in the average patient. Since the patient had no prior infection or serious illness, it is worth raising the question of a genetic variant being the cause of the lesion, and how such a variant might have impacted its size.


## CR41 From Azoospermia to Fertility: A Successful Case of mTESE Treatment

Lara Fotez<sup>a</sup>, Martin Bobek<sup>a</sup>, Klara Dorešić<sup>a</sup>, Lucija Fotez<sup>a</sup>, Dinko Hauptman<sup>b</sup>

<sup>a</sup> School of Medicine, University of Zagreb, Zagreb, Croatia

<sup>b</sup> Department of Urology, University Hospital Centre Zagreb, Zagreb, Croatia

DOI: <https://doi.org/10.26800/LV-145-supl2-CR41>

 Lara Fotez 0000-0002-4612-4274, Martin Bobek 0009-0003-1582-4184, Klara Dorešić 0000-0002-5043-6908, Lucija Fotez 0000-0002-5185-0684, Dinko Hauptman 0000-0001-7151-6512

**KEYWORDS:** andrology; azoospermia; hypospermatogenesis; male infertility; microdissection

**INTRODUCTION/OBJECTIVES:** Infertility is diagnosed clinically in heterosexual couples who cannot achieve pregnancy after a year of having intercourse without using birth control. Statistically, every sixth couple in Croatia is infertile and 50% of infertility cases are male-originated.

**CASE PRESENTATION:** A 30-year-old healthy male patient presented with a two-year failed conception with a reproductively healthy partner. He had no history of mumps infection or sexually transmitted diseases and denied any testicular trauma. Spermogram demonstrated no vital sperm in the ejaculate, corresponding to azoospermia. His FSH (54 mIU/mL) and LH (14 mIU/mL) levels were very high, and his testosterone level was optimal (9.53 nmol/L). In search for the cause, Color Doppler Ultrasonography of testicles ruled out tumors, and genetic testing verified a normal 46 XY karyogram with no Y-chromosome microdeletion. Therefore, the patient was diagnosed with idiopathic non-obstructive azoospermia. Biopsy results of the right testicle showed mixed atrophy and significant tubular fibrosis. In the left testicle, rare foci of hypospermatogenesis with mature sperm and spermatids were present. For treatment, he underwent Microdissection Testicular Sperm Extraction (mTESE), intending to isolate vital sperm sufficient for in vitro fertilization by intracytoplasmic sperm injection (IVF/ICSI). Morphologically and functionally healthy sperms were extracted and cryopreserved in the sperm bank in five cryotubes which supply five IVF/ICSI attempts.

**CONCLUSION:** mTESE-extracted sperms are used in combined procedures with IVF/ICSI in collaboration with a gynecologist to achieve offspring. Therefore, mTESE is the most effective method for treating severe male infertility known as non-obstructive azoospermia, which is a growing public health problem in Croatia.


## CR42 FROM PITIRIASIS LICHENOIDES CHRONICA TO SYPHILIS AND HIV – A DETECTIVE'S APPROACH

Lorena Dolački<sup>a</sup>, Josip Prnjak<sup>a</sup>, Liborija Lugović-Mihić<sup>b</sup>

<sup>a</sup> School of Medicine, University of Zagreb, Zagreb, Croatia

<sup>b</sup> Department of Dermatovenereology, Sestre milosrdnice University Hospital Zagreb, Zagreb, Croatia

DOI: <https://doi.org/10.26800/LV-145-supl2-CR42>

 Lorena Dolački 0000-0001-6233-2391, Josip Prnjak 0000-0001-8100-6890, Liborija Lugović-Mihić 0000-0001-7494-5742

**KEYWORDS:** HIV; Pityriasis Lichenoides; Syphilis

**INTRODUCTION/OBJECTIVES:** Pityriasis lichenoides chronica (PLC) is a rare, non-infective dermatosis of unknown etiology characterized by reddish-brown papules with potential overlying mica-like scales, which sometimes progress to cutaneous T-cell lymphoma. Lesions mimicking PLC can (rarely) occur as a presentation of an underlying infectious disease or as a paraneoplastic syndrome.

**CASE PRESENTATION:** A 54-year old male, otherwise healthy and with no specific risk/trigger factors in his medical history, presented with a rash (disseminated, indurated, livid papules, covered with adherent scales on the trunk and extremities) and concomitant itch that appeared 2 months prior to admission. He was examined by a dermatologist, who diagnosed PLC based on clinical features but also referred him to a tertiary center. Initially, the patient was treated with antihistamines and oral and topical corticosteroids. Despite the histological confirmation of PLC, the dermatologist at the tertiary center ordered additional tests. Results showed some changes in the blood findings (anemia, lymphopenia, thrombocytopenia, high gamma globulin levels) and cervical lymphadenopathy (ultrasound), raising the question of lymphoma. Serology tests for syphilis (RPR, TPHA, FTA-ABS IgG and IgM) were positive; thus, anti-syphilis therapy was administered. A serology test for HIV was also positive, so the patient was referred to an infectologist for treatment.

**CONCLUSION:** Atypical skin manifestations of secondary syphilis have been identified in patients with concomitant HIV infection, and both diseases are known to mimic other skin disorders. Consequently, clinicians should be aware that clinical features can be diverse and that every diagnosis, even when confirmed by histological examination, should be questioned.




### CR43 From Polyuria to Pathological Fracture: A Challenging Case of Multiple Myeloma

Lucija Galiot<sup>a</sup>, Zdravko Mitrović<sup>a,b</sup>

<sup>a</sup> School of Medicine, University of Zagreb, Zagreb, Croatia

<sup>b</sup> Division of Hematology, Clinical Hospital Dubrava, Zagreb, Croatia

DOI: <https://doi.org/10.26800/LV-145-sup12-CR43>

 Lucija Galiot 0000-0002-9613-7399, Zdravko Mitrović 0000-0002-9896-1234

**KEYWORDS:** femoral fracture; multiple myeloma; prostate

**INTRODUCTION/OBJECTIVES:** Multiple myeloma is a proliferation of neoplastic plasma cells producing a monoclonal protein (M-protein). Multiple myeloma can present in various ways with anemia, renal failure, hypercalcemia, and bone fractures as the most common signs.

**CASE PRESENTATION:** An otherwise healthy 66-year-old male was referred to the urology clinic due to polyuria and nocturia associated with a weak stream. He also complained of night sweats and low-grade fever. Ultrasound imaging showed an abnormal mass in the prostate. Further laboratory testing showed anemia with a hemoglobin level of (100 g/L), elevated levels of creatinine (399 umol/L), and prostate-specific antigen (0.54 ug/L). Computed tomography (CT) of the abdomen and pelvis revealed a solid tumor mass of the prostate and seminal vesicles. A transrectal biopsy was performed. After the procedure, he sustained a fracture of the left femur diaphysis while getting out of bed. An X-ray showed altered bone structure at the fracture site, indicating a pathological fracture. Osteosynthesis was performed using a single locking plate and a sample of the pathologically changed bone was taken for analysis. Both biopsies were consistent with the diagnosis of multiple myeloma. Eventually, M-protein was detected in the serum protein electrophoresis and bone marrow aspiration from the sternum revealed massive infiltration by neoplastic plasma cells.

**CONCLUSION:** The reported case is an example of the various clinical presentations of multiple myeloma. In patients with anemia, elevated creatinine, and a neoplasm affecting bones, serum protein electrophoresis may be useful to raise suspicion of multiple myeloma.


### CR44 Fungus Balls in the Ureter of a Patient with Generalized Candida Mycosis

Antonia Bukovac<sup>a</sup>, Gabrijela Buljan<sup>a</sup>, Ingrid Prkačin<sup>b</sup>

<sup>a</sup> School of Medicine, University of Zagreb, Zagreb, Croatia

<sup>b</sup> Emergency internal medicine department, Clinical hospital Merkur, Zagreb, Croatia

DOI: <https://doi.org/10.26800/LV-145-sup12-CR44>

 Antonia Bukovac 0000-0002-0412-433X, Gabrijela Buljan 0000-0003-4060-9497, Ingrid Prkačin 0000-0002-5830-7131

**KEYWORDS:** candida albicans; mycoses; opportunistic infections

**INTRODUCTION/OBJECTIVES:** The morbidity and mortality associated with opportunistic fungal infections is continually rising which has been attributed to an increase of at-risk patients. Risk factors include recent surgery, broad-spectrum antibacterial therapy, corticosteroid or cytotoxic drug therapy, compromised physical barriers and underlying diseases such as diabetes mellitus, renal failure or neoplasia.

**CASE PRESENTATION:** A 40-year-old man presented with a history of decreased mentation, abdominal and lumbar pain, fever and numerous urinary complaints during a period of 8 weeks. He reported experiencing cloudy urine, difficulties voiding, stranguria, nocturia and the passage of small white fragments from his urethra. The patient had a history of insulin dependent diabetes mellitus, congestive heart failure and acute renal failure. A urine culture and blood culture resulted in the growth of *Candida albicans*. An ultrasound and an excretory urography were performed showing both enlarged edematous kidneys and hypofunction of the right kidney. There were also described to be ball-like "membranes" within both the ureters causing a stenosis of the right ureter. The patient was admitted with a diagnosis of acute pyelonephritis, his condition deteriorating rapidly. He was treated with insulin and intravenous antifungal therapy followed by ureterolysis with a "T" prosthesis. He slowly improved with antifungal therapy, but renal failure persisted.

**CONCLUSION:** Opportunistic fungal infections present a significant health concern to at-risk patients leading to a difficult clinical course complicated by their specific medical status. It must be taken into consideration when presented with a patient with risk factors that are becoming more and more common.


### CR45 Hereditary neuropathy with liability to pressure palsies as a possible predisposing factor to the development of Chronic inflammatory demyelinating polyneuropathy

Marija Bukvić<sup>a</sup>, Marija Ćorić<sup>a</sup>, Rafael Toni Kovač<sup>a</sup>, Krunoslav Budimir<sup>a</sup>, Hrvoje Bilić<sup>b</sup>

<sup>a</sup> School of Medicine, University of Zagreb, Zagreb, Croatia

<sup>b</sup> Department of Neurology, University Hospital Centre Zagreb, Zagreb, Croatia

DOI: <https://doi.org/10.26800/LV-145-supl2-CR45>

 Marija Bukvić 0009-0005-6327-9509, Marija Ćorić 0009-0001-8153-5052, Rafael Toni Kovač 0009-0009-2242-8220, Krunoslav Budimir 0000-0002-7738-0326, Hrvoje Bilić

**KEYWORDS:** CIDP; PMP22 protein, human; Tomaculous neuropathy

**INTRODUCTION/OBJECTIVES:** Chronic inflammatory demyelinating polyneuropathy (CIDP) is a symmetric distal muscle weakness and sensory deficit accompanied with diminished or absent deep tendon reflexes. Hereditary neuropathy with liability to pressure palsies (HNPP) is a hereditary neuropathy presenting with transient muscle weakness and sensory symptoms after exposure to pressure or prolonged use in the affected area.

**CASE PRESENTATION:** A twenty-one-year-old male presented with relapsing-remitting muscle weakness lasting for five years. Symptoms started after exercise and spontaneously regressed after a couple weeks. Physical exam findings included neurological symptoms - paresis of foot dorsiflexion, loss of vibration and hypesthesia, and bilateral m. quadriceps femoris reflex clonus. The patient had a history of essential tremor. Diagnostic tests showed albuminocytological dissociation in the CSF and positive antiganglioside antibodies in the sera. An MR of the L-S spine showed no signs of demyelination. EMG and NCS showed signs of a demyelinating sensory and motor polyneuropathy affecting upper and lower extremities. Genetic testing found a heterozygous deletion of the PMP22 gene, typical for HNPP. The patient was diagnosed with HNPP with superimposed CIDP. Intravenous immunoglobulins were administered at 2 g/kg which improved motor and sensory symptoms. 2 years from the hospital stay, after getting a computer job, the patient reports tingling and weakness in the hands after work, partially regressing during the night.

**CONCLUSION:** CIDP associated with HNPP has seldom been reported and described in literature. These rare cases outline the possible connection of hereditary neuropathies predisposing to an immune mediated acquired neuropathy.


### CR46 Herlyn-Werner-Wunderlich syndrome in a adolescent girl

Vita Jugovac<sup>a</sup>, Nika Baldani<sup>a</sup>, Marko Gavrančić<sup>a</sup>, Iva Mažić<sup>a</sup>, Dinka Pavičić Baldani<sup>a,b</sup>

<sup>a</sup> School of Medicine, University of Zagreb, Zagreb, Croatia

<sup>b</sup> Division for Reproductive Medicine and Gynaecological Endocrinology, Department of Obstetric and Gynecology, Clinical Hospital Centre Zagreb, Zagreb, Croatia

DOI: <https://doi.org/10.26800/LV-145-supl2-CR46>

 Vita Jugovac 0000-0003-1989-6276, Nika Baldani 0000-0002-8412-3598, Marko Gavrančić 0000-0002-5262-956X, Iva Mažić 0000-0001-9014-0864, Dinka Pavičić Baldani

**KEYWORDS:** Hysterectomy; Laparoscopy; Menstrual Cycle; Renal Adysplasia; Uterine Anomalies

**INTRODUCTION/OBJECTIVES:** Herlyn-Werner-Wunderlich syndrome (HWWS) is a rare congenital genitourinary anomaly with uterine anomalies, unilateral cervicovaginal obstruction, and ipsilateral renal anomalies resulting from the embryological arrest of Müllerian and mesonephric ducts. The onset of nonspecific symptoms occurs after menarche. Having two normal uteri and obstructed cervix or hemivagina, the patient will have regular menses through the non-obstructed vaginal side, coinciding with cyclic pelvic pain from the encumbered blood in the obstructed side. The diagnosis is often delayed until acute complications develop.

**CASE PRESENTATION:** A 12-year-old girl presented to the emergency department with LLQ pain that started on the third day of her menstrual cycle. She had menarche a year ago and has no history of dysmenorrhoea. Vital signs, laboratory parameters, abdominal ultrasound, and RTG were unremarkable. On the fifth day of the menstrual cycle, with symptoms of persistent, now RLQ pain, elevated body temperature, and peritoneal defense, the patient was diagnosed with acute appendicitis. Intraoperative examination revealed an innocent appendix, bloody secretion in the pelvis, and an oedematous left fallopian tube. HWWS diagnosis was established after an emergency consultation with a gynecologist during the operation. MRI provided more detailed information for surgical strategies, which confirmed the diagnosis: uterus didelphys with left cervical atresia enlarged left uterine horn, left hematosalpinx, possible hemivagina, and left kidney agenesis. Laparoscopic left-side hysterectomy and salpingectomy were performed.

**CONCLUSION:** HWWS should be suspected in cases with cyclic pelvic pain and renal malformations. This case highlights the importance of knowing developmental anomalies to include them in the differential diagnosis.

### CR47 Innovative Genome Joint Analysis for identification of novel deep-intronic de novo pathogenic variants in KMT2A gene - Wiedemann-Steiner Syndrome


Matea Bagarić<sup>a</sup>, Nives Živković<sup>b</sup>, Mario Ćuk<sup>a,b,c</sup>

<sup>a</sup> School of Medicine, University of Zagreb, Zagreb, Croatia

<sup>b</sup> Department of Pediatrics, University Hospital Centre Zagreb, Zagreb, Croatia

<sup>c</sup> "Mila za Sve" Foundation and CroSeq-GenomeBank Research Project, Rijeka/Zagreb, Croatia

DOI: <https://doi.org/10.26800/LV-145-supl2-CR47>

 Matea Bagarić 0000-0001-7887-2229, Nives Živković 0009-0007-9889-3212, Mario Ćuk 0000-0002-7119-133X

**KEYWORDS:** Hypertrichosis cubiti; KMT2A protein, human; Rare Disease; Whole Genome Sequencing

**INTRODUCTION/OBJECTIVES:** Heterozygous mutations in KMT2A gene are known to cause Wiedemann-Steiner Syndrome (WDSTS), a rare, autosomal dominant disease characterized by facial dysmorphism, intellectual disability, hypertrichosis cubiti, and psychomotor developmental delay. Whole genome sequencing (WGS) is a promising method to both identify pathogenic gene variants and facilitate personalized medical management.

**CASE PRESENTATION:** We present an 8-year-old boy with WDSTS caused by four de novo mutations in KMT2A gene, encoding a transcriptional coactivator that plays an essential role in regulating gene expression during early development. Born at term with birth weight 2460 g, Apgar 6/8, pregnancy was associated with intra-uterine growth retardation. Growth and psychomotor development were delayed during the first 4.5 years of life. Dysmorphic facial features include hypertelorism, antimongoloid eyes and epicanthus. Hypertrichosis, growth hormone deficit, chronic tonsil inflammation, gastroesophageal reflux, convergent strabismus, allergic diathesis, ADHD, and hypovitaminosis D3 with hypercalcemia are present. Intelligence is below average. He is obese (BMI 24.1 kg/m<sup>2</sup>). Bender-Gestalt Test demonstrated difficulties in visuomotor coordination and visuomotor perception. Under the "CroSeq-GenomeBank" project, an analysis of the child's entire genome was performed and four de novo pathogenic variants in the KMT2A gene on 11q23 in the heterozygous composition were identified.

**CONCLUSION:** A patient with four de novo pathogenic variants in the KMT2A gene not previously reported in the literature was described. A multidisciplinary approach with an emphasis on neurodevelopment and diet therapy is key to the treatment of WDSTS. "CroSeq-GenomeBank" Project has brought the opportunity for personalized approach to a rare disease, keeping Croatia in step with highly developed countries.

### CR48 Innovative Whole Genome Joint Analysis – case report of early diagnosis and preventive approach to HFE Hemochromatosis


Marjan Kulaš<sup>a</sup>, Dina Gržan<sup>a</sup>, Sandro Kukić<sup>a</sup>, Luka Lovrenčić<sup>b,c</sup>, Mario Ćuk<sup>a,b,c</sup>

<sup>a</sup> School of Medicine, University of Zagreb, Zagreb, Croatia

<sup>b</sup> Department of Pediatrics, University Hospital Centre Zagreb, Zagreb, Croatia

<sup>c</sup> "Mila za Sve" Foundation and CroSeq-GenomeBank Research Project, Rijeka/Zagreb, Croatia

DOI: <https://doi.org/10.26800/LV-145-supl2-CR48>

 Marjan Kulaš 0000-0001-5140-8514, Dina Gržan 0000-0002-3312-5569, Sandro Kukić 0000-0001-6425-1624, Luka Lovrenčić 0000-0002-3132-6930, Mario Ćuk 0000-0002-7119-133X

**KEYWORDS:** Genetic Variations; Primary Hemochromatosis; Whole Genome Sequencing


**INTRODUCTION/OBJECTIVES:** Whole Genome Joint Analysis is an innovative method to elucidate the full spectrum of genome complexities and alterations in the family members, comprehensively and unbiasedly. Once identified in the preclinical phase of the disease, causative variants can anticipate a personalized preventive approach and medical treatment.

**CASE PRESENTATION:** We present a patient who is the mother of our index child whom we evaluated for a rare disease. Therefore, the mother was a „healthy“ participant in this research. The biallelic variants of the HFE gene have been identified: p.Cys282Tyr and p.His63Asp which makes the patient compound heterozygous for the HFE gene, therefore having hemochromatosis type 1b. Often the first signs are arthropathy, an increase in skin pigmentation, cardiomyopathy, hepatomegaly, and common nonspecific symptoms. Women are affected less frequently than men. However, our patient is female and has a low to moderate genotype but has developed symptoms at the age of 40. Screening using transferrin saturation, noninvasive liver, and quantitative cardiac MRI may be considered to support the diagnosis. Periodic phlebotomy is a simple and effective treatment. Results of the deferasirox (Exjade®) trial suggest that the oral iron chelator is effective at reducing iron burdens within an acceptable safety profile.

**CONCLUSION:** The "CroSeq-GenomeBank" project which enabled us to diagnose our patient with primary hemochromatosis, acts as an innovative and precise basis for personalized medicine using artificial intelligence. It is an expensive and insufficiently accessible approach that would mean a lot to us as a society if we were to maintain our profession at the highest level.



**CR49 Insulinoma as a rare cause of hypoglycemia - a case report**Lucija Fotez<sup>a</sup>, Lara Fotez<sup>a</sup>, Alen Gabrić<sup>a</sup>, Maja Baretić<sup>b</sup><sup>a</sup> School of Medicine, University of Zagreb, Zagreb, Croatia<sup>b</sup> Department of Endocrinology and Diabetes, University Hospital Centre Zagreb, Zagreb, CroatiaDOI: <https://doi.org/10.26800/LV-145-supl2-CR49>

 Lucija Fotez 0000-0002-5185-0684, Lara Fotez 0000-0002-4612-4274, Alen Gabrić 0000-0002-1136-194X, Maja Baretić 0000-0002-7242-8407


**KEYWORDS:** hypoglycemia; insulinoma; neuroendocrine tumor

**INTRODUCTION/OBJECTIVES:** Insulinoma is a rare neuroendocrine tumor originating from pancreatic  $\beta$ - cells. Hypoglycemia is seen in patients with diabetes treated with insulin and sulfonyleureas, alcohol abuse, and starvation. Severe spontaneous hypoglycemia is uncommon and can be caused by this rare tumor.

**CASE PRESENTATION:** A 28-year-old female patient presents with dizziness, weakness, and frequent loss of awareness for three months. The neurological exam was normal, but low glucose levels (1.6-1.7 mmol/L) were detected. In the hospital, the 72h-fasting test stopped at 48h with a glucose level of 1.8mmol/L and insulin of 9.8 mU/L, indicating inadequate physiological suppression of the endogenous insulin. Based on hypoglycemia and endogenous hyperinsulinemia, insulinoma was suspected. Endoscopic ultrasound showed normal echostructure of the pancreas. MRI scan revealed a round-shaped focal lesion measuring 1.5x1 cm at the distal part of the pancreatic head, within the parenchyma that was inconclusive for the tumor or physiological feature of the pancreas. Therefore, a selective intra-arterial stimulation with calcium gluconate, alongside hepatic venous sampling was conducted. Standard pancreatic arteriography followed by selective catheterization of the gastroduodenal, splenic, and superior mesenteric arteries were performed. Peak insulin level obtained from the gastroduodenal artery established the precise tumor location for complete surgical excision. The pathological finding confirmed the diagnosis of insulinoma.

**CONCLUSION:** Early diagnosis and precise localization of insulinoma are crucial to minimize the risk of unsuccessful surgical resection and to prevent long-term complications associated with hypoglycemia. This case highlights the importance of considering insulinoma as a potential cause of hypoglycemia and utilizing appropriate diagnostic tools for tumor localization.

**CR50 Intraocular tuberculosis – case report**Petra Galić<sup>a</sup>, Lucija Maticić<sup>b</sup>, Lea Arambašić<sup>a</sup>, Zara Miočić<sup>a</sup>, Suzana Maticić<sup>a,b,c</sup><sup>a</sup> Faculty of Medicine, Josip Juraj Strossmayer University of Osijek, Osijek, Croatia<sup>b</sup> Faculty of Dental Medicine And Health, Josip Juraj Strossmayer University of Osijek, Osijek, Croatia<sup>c</sup> Department of Ophthalmology, Osijek University Hospital Centre, Osijek, CroatiaDOI: <https://doi.org/10.26800/LV-145-supl2-CR50>

 Petra Galić 0009-0000-6534-2616, Lucija Maticić 0009-0004-3354-2700, Lea Arambašić 0009-0000-6975-9240, Zara Miočić 0009-0000-7128-0079

**KEYWORDS:** eye evisceration; ocular tuberculosis; uveitis

**INTRODUCTION/OBJECTIVES:** Tuberculosis (TB) is a chronic granulomatous infection caused by Mycobacterium tuberculosis. If the affected organ is the eye, the clinical picture is pleomorphic, but it is most often presented with endophthalmitis, iridocyclitis, chorioretinitis, and periphlebitis of the retina.

**CASE PRESENTATION:** We present a 44 years old cachectic man, with a history of pulmonary TB. He was admitted to the hospital due to left-sided endophthalmitis. Upon arrival, the patient had left eye amaurosis, with elevated eye pressure, mixed conjunctival injection, numerous precipitates on the corneal endothelium, hypopyon, and pupillary seclusion. An extensive work-up was performed in order to confirm the etiology of uveitis. Local and general antimicrobial and corticosteroid therapy and systemic antifungals were introduced without response. A computerized tomography scan of the left orbit showed an enlarged eyeball, with inflammatory thickening of all eye membranes, and the tumor process was ruled out. Ultrasound of the left eye confirmed exudative inflammation, chorioretinal thickening, and suspected shallow retinal detachment. Anaerobic, aerobic, and fungal blood cultures were negative. Due to worsening the condition, evisceration of the left eyeball was performed. Pathohistological findings confirmed the reactivation of pulmonary TB and its dissemination in the eye.

**CONCLUSION:** Ocular tuberculosis is an infrequent cause of uveitis. But tuberculosis should also be included as a possible cause in the differential diagnosis of uveitis. This applies mainly to patients with a positive history of active or relapsing pulmonary tuberculosis who have no improvement in clinical findings with antimicrobial and steroid therapy.


### CR51 The effect of art therapy on the degree of depression and the outcomes of Parkinson's disease treatment

Lorena Loje<sup>a</sup>, Tea Kržak<sup>a</sup>, Srđana Telarović<sup>a,b</sup>

<sup>a</sup> School of Medicine, University of Zagreb, Zagreb, Croatia

<sup>b</sup> Department of neurodegenerative diseases, Department of Neurology, University Hospital Centre Zagreb, Zagreb, Croatia

DOI: <https://doi.org/10.26800/LV-145-supl2-CR51>

 Lorena Loje 0009-0004-5081-3090, Tea Kržak 0000-0001-8897-5838, Srđana Telarović 0000-0002-1287-6144

**KEYWORDS:** art therapy; depression; multimodal approach; Parkinson's disease

**INTRODUCTION/OBJECTIVES:** According to various studies, depression occurs in a large percentage of patients diagnosed with Parkinson's disease (PD). In some cases, it appears as the first symptom and significantly impairs the patient's quality of life.

**CASE PRESENTATION:** A 55-year-old patient presents for the first time to the Outpatient Clinic for Extrapyrimal Diseases with clumsiness and tremors of the right limbs, along with a change in handwriting and motorical ineptness. Upon the diagnosis of PD, the patient is assessed as having 2.5 degrees of severity on the Hoehn&Yahr (H-Y) scale and scored a result of 34 on the Beck Depression Inventory (BDI) II scale which suggests a severe depressive state. The treatment for depression was started with maprotiline chloride, and PD treatment with ropinirole, amantadine, and selegiline, and in the later course with the addition of levodopa/benserazide, alongside a recommendation for art therapy. In the same year, the patient begins painting daily. The patient attended her control examinations regularly. Five years later, subjective and objective improvement is noted - 10 points on the BDI II scale and 2 with H-Y which confirms significant improvement in her mental and neurological state. The patient continued with art therapy, which further developed into work and occupational therapy, and there is no longer need for pharmacological therapy for depression.

**CONCLUSION:** Art therapy has proven to be a significant complementary tool in the treatment of depression in patients with PD, and as part of a multimodal approach enables comprehensive care.


### CR52 Left ventricular pseudoaneurysm of the inferior wall with thrombus: diagnosis and management

Laura Carla Kraljević<sup>a</sup>, Matija Marković<sup>b</sup>

<sup>a</sup> School of Medicine, University of Zagreb, Zagreb, Croatia

<sup>b</sup> Department of Cardiology, University Clinical Hospital Merkur, Zagreb, Croatia

DOI: <https://doi.org/10.26800/LV-145-supl2-CR52>

 Laura Carla Kraljević 0009-0002-9049-0236, Matija Marković 0000-0002-2852-3730

**KEYWORDS:** diagnosis; heart aneurysm; thrombus

**INTRODUCTION/OBJECTIVES:** Left ventricular pseudoaneurysm is rare and life-threatening condition which can happen after untreated myocardial infarction, cardiac surgery, infection or trauma. It is formed when cardiac wall rupture is contained by adherent pericardium, scar tissue or thrombus and is prone to rapid enlargement and rupture. The diagnosis is difficult and it carries a high mortality rate.

**CASE PRESENTATION:** A 82-year-old woman with hypertension came to the emergency care and presented with a two week history of difficulty breathing, orthopnea and stenocardia a week before symptoms started. The electrocardiogram (ECG) showed sinus rhythm, ST-elevation and Q-wave in inferior leads. The patient presented with a regular pulse rate of 91 bpm and blood pressure of 130/90 mmHg. The transthoracic echocardiography showed dilated right heart with severe pulmonary hypertension and left ventricular pseudoaneurysm of the inferior wall with thrombus. Multi-slice chest computed tomography (MSCT) excluded pulmonary embolism but confirmed signs of pulmonary hypertension. The patient was hospitalized for heart failure and left ventricular pseudoaneurysm treatment. She was treated with diuretic, ACEi, beta-blocker, low-molecular-weight heparin with a gradual introduction of warfarin. With this treatment, her clinical condition improved, and she was stable, both hemodynamically and respiratory. She refused surgical treatment of pseudoaneurysm.

**CONCLUSION:** Left ventricular pseudoaneurysm is rare condition nowadays in the era of good treatment of myocardial infarctions, but it shouldn't be overlooked. Prompt diagnosis, prevention of complication and heart team evaluation is crucial. Surgical treatment bears high mortality rate, and in rare cases even conservative approach is possible after shared decision making with the patient.


### CR53 Management of Cushing's disease when surgery is a tricky option – a case report

Lucija Vusić<sup>a</sup>, Vedrana Verić<sup>a</sup>, Matea Živko<sup>a</sup>, Velimir Altabas<sup>a,b</sup>

<sup>a</sup> School of Medicine, University of Zagreb, Zagreb, Croatia

<sup>b</sup> Department of Endocrinology, Diabetes and Metabolic Diseases, Sestre milosrdnice University Hospital Center, Zagreb, Croatia

DOI: <https://doi.org/10.26800/LV-145-supl2-CR53>

 Lucija Vusić 0000-0001-9367-8651, Vedrana Verić 0000-0002-2595-8464, Matea Živko 0000-0001-5033-3506, Velimir Altabas 0000-0002-9076-9870

**KEYWORDS:** adrenocorticotrophic hormone; cortisol; Cushing's disease

**INTRODUCTION/OBJECTIVES:** Cushing's disease, a form of Cushing's syndrome, is caused by excess ACTH production, a hormone that regulates cortisol production, by a benign tumor in the pituitary gland. As a result, cortisol levels are elevated, while ACTH levels are not suppressed due to autonomous secretion. The primary treatment option is surgery. Other therapeutic modalities include drug therapy, radiation, and bilateral adrenalectomy in selected cases.

**CASE PRESENTATION:** In 2019, in a 65-year-old female patient with bilateral cortical adenoma, hypercortisolemia was detected. Further testing revealed elevated late-night salivary cortisol and insufficient cortisol suppression in Liddle's test. ACTH was not suppressed. Initially, no pituitary tumor was detected on NMR scans. Fluconazole was used as her initial treatment to inhibit steroidogenesis, but without a proper response. Then the patient has been prescribed metyrapone. Three months after starting metyrapone, the patient began to experience side effects, including stomach pain and irregular blood pressure. After re-running pituitary tests, a microadenoma was found too small for surgery. Gamma knife radiosurgery was conducted, but one month postoperatively, cortisol levels remained high and cabergoline treatment was introduced without adequate response over time. In 2022, low-dose pasireotide eventually replaced cabergoline. The patient's cortisol level is currently normal with clinical improvement and is being regularly checked.

**CONCLUSION:** Cushing's disease is a serious condition with systematic deteriorating effects. Treatment is still challenging, and there is still enough space for new treatment options that may benefit the patient.


### CR54 Management of metabolic crisis in three-day-old newborn

Tea Kržak<sup>a</sup>, Lorena Loje<sup>a</sup>, Ivo Barić<sup>b</sup>, Dorotea Ninković<sup>b</sup>

<sup>a</sup> School of Medicine, University of Zagreb, Zagreb, Croatia

<sup>b</sup> Department of Pediatrics, University Hospital Centre Zagreb, Zagreb, Croatia

DOI: <https://doi.org/10.26800/LV-145-supl2-CR54>

 Tea Kržak 0000-0001-8897-5838, Lorena Loje 0009-0004-5081-3090, Ivo Barić 0000-0002-5119-9174, Dorotea Ninković 0000-0002-4239-519X

**KEYWORDS:** hyperammonemia; ornithine transcarbamylase deficiency disease; urea cycle disorder

**INTRODUCTION/OBJECTIVES:** Urea cycle disorders are a group of metabolic disorders, caused by deficiency of one of the enzymes in the urea cycle, presenting with hyperammonemia triggered by catabolism or protein overload. Newborns with severe mutations in the urea cycle, unless treated, rapidly develop cerebral edema, coma and death.

**CASE PRESENTATION:** We present a 3-day-old male newborn born from the first pregnancy of a 36-year-old mother, complicated with mother's convulsion during birth. During the second day of life neonate presented with hyperventilation and weak sucking, later sepsis was suspected and antibiotics were introduced, but the neonate developed agonal breathing, altered consciousness, generalized hypertonus and lack of pupil response. Ammonia concentration in the serum, at the age of 60 hours, was altered (270 μmol/L). The patient was transferred to our unit ten hours later. At the admission ammonia concentration was 2062 μmol/L. The administration of amino acids was terminated, catabolism stopped with glucose infusion, nitrogen scavengers (intravenous sodium benzoate and arginine hydrochloride) were introduced, and hemodialysis was started. Laboratory results showed high plasma alanine and glutamine and low citrulline concentrations and increased orotic acid excretion suggesting urea cycle disorder, more specifically ornithine transcarbamylase deficiency, which was proved by gene analysis. The patient was discharged at the age of 6 weeks. He is now two years old and has acceptable neurocognitive development but is still at high risk of hyperammonemic crisis.

**CONCLUSION:** Timely recognition of urea cycle disorders enables quick intervention and lowering of harmful ammonia concentrations. Additional education of neonatologists is necessary to accomplish that goal.




## CR55 Mechanical Thrombectomy as an Effective Treatment for Pulmonary Embolism in Intermediate-high risk patients

Alen Gabrić<sup>a</sup>, Lucija Fotez<sup>a</sup>, Lucija Ercegovac<sup>a</sup>, Luka Novosel<sup>b</sup>

<sup>a</sup> School of Medicine, University of Zagreb, Zagreb, Croatia

<sup>b</sup> Department of Interventional and Diagnostic Radiology, Sestre Milosrdnice University Hospital, Zagreb, Croatia

DOI: <https://doi.org/10.26800/LV-145-supl2-CR55>

 Alen Gabrić 0000-0002-1136-194X, Lucija Fotez 0000-0002-5185-0684, Lucija Ercegovac 0000-0001-8368-8602, Luka Novosel 0000-0001-7515-9110

**KEYWORDS:** Interventional Radiology; Pulmonary Embolism; Thrombectomy

**INTRODUCTION/OBJECTIVES:** Pulmonary embolism (PE) is a significant cause of hospitalization and death worldwide. Therapy controversies arise in intermediate high-risk patients without signs of hemodynamic instability but with clinical characteristics of more severe PE. This case report demonstrates a successful resolution of PE with endovascular mechanical thrombectomy.

**CASE PRESENTATION:** A 75-year-old presented with right hemiparesis due to acute ischemic stroke. Brain CT showed no apparent signs of acute ischemia or hemorrhage and the patient was started on intravenous thrombolysis. MRI revealed a subacute ischemic lesion with hemorrhagic transformation during the diagnostic workup. A week later, the patient became dyspneic, hypoxic, and tachycardic. Pulmonary CT angiography showed acute pulmonary embolism of both pulmonary arteries with propagation in all lobar branches and right ventricular strain. Since the patient had recent intracranial bleeding, she had a contraindication for thrombolysis. The patient was referred to radiology and underwent an endovascular mechanical thrombectomy. Emboli were successfully aspirated using the 24 French Flowtriever aspiration system. Pulmonary artery pressures dropped from 50/30 to 30/15 mmHg, O<sub>2</sub> saturation increased from 80 to 96% and heart rate returned to normal. The patient recovered successfully.

**CONCLUSION:** This case illustrates that mechanical thrombectomy may be the optimal therapy in intermediate high-risk PE patients and cases when there is a contraindication for thrombolysis. It is a valuable minimally invasive alternative to surgical thrombectomy. Future research is needed to demonstrate the safety and superiority of this treatment modality over others in different PE patients.


## CR56 Metastatic thyroid cancer after thyroidectomy in patient with MEN2A syndrome: a case report

Ana Čala<sup>a</sup>, Tina Dušek<sup>a,b</sup>

<sup>a</sup> School of Medicine, University of Zagreb, Zagreb, Croatia

<sup>b</sup> Department of Endocrinology, University Hospital Centre Zagreb, Zagreb, Croatia

DOI: <https://doi.org/10.26800/LV-145-supl2-CR56>

 Ana Čala 0009-0001-0606-5986, Tina Dušek 0000-0002-1266-3501

**KEYWORDS:** MEN-2A Syndrome; medullary thyroid carcinoma; metastasis; thyroidectomy

**INTRODUCTION/OBJECTIVES:** Multiple Endocrine Neoplasia Type 2 (MEN 2) is a complex hereditary disorder with a genetic predisposition toward the development of endocrine tumors. MEN2a complex is the most common variant which comprises medullary thyroid carcinoma (MTC), pheochromocytoma and multiglandular parathyroid hyperplasia. MTC is usually the initial presenting feature of this complex and a specific RET codon mutation can help predict the disease and how it will behave.

**CASE PRESENTATION:** We present a 44-year-old female patient with MEN-2 Syndrome with past medical history of medullary thyroid carcinoma and total thyroidectomy. Postsurgical assessment for recurrent disease was done regularly including the measurement of serum calcitonin, calcium and urine metanephrines and normetanephrines. Surprisingly, 27 years later patient had elevated serum calcitonin. PET-CT showed pulmonary and infracarinal lymph node metastatic disease. Lymph nodes were surgically removed and pathohistology confirmed metastatic medullary thyroid carcinoma. The patient was treated with 131I-MIBG. Unfortunately, the disease progressed and in spite of treatment the patient had died. As her son was a carrier of MEN2a mutation 634, prophylactic thyroidectomy was performed at the age of 8 and he continued with regular follow up.

**CONCLUSION:** MEN2a is a serious genetic condition with possible unfavorable outcome. In our case, MTC relapsed even 27 years after thyroidectomy. Therefore, close follow up and prophylactic thyroidectomy is crucial in patients with confirmed mutation.

### CR57 Mild carnitine uptake defect due to a novel homozygous mutation in the SLC22A5 gene detected by newborn screening

Lea Klepač<sup>a</sup>, Klara Miljanić<sup>a</sup>, Danijela Petković Ramadža<sup>a,b</sup>, Ivo Barić<sup>a,b</sup>, Tamara Žigman<sup>a,b</sup>

<sup>a</sup> School of Medicine, University of Zagreb, Zagreb, Croatia

<sup>b</sup> Department of Pediatrics, University Hospital Centre Zagreb, Zagreb, Croatia

DOI: <https://doi.org/10.26800/LV-145-supl2-CR57>

 Lea Klepač (0000-0002-6801-9715, Klara Miljanić 0000-0002-5049-6783, Danijela Petković Ramadža 0000-0002-8562-153X, Ivo Barić 0000-0002-5119-9174, Tamara Žigman 0000-0003-1184-8798

**KEYWORDS:** carnitine uptake defect; systemic carnitine deficiency; newborn screening; SLC22A5 protein

**INTRODUCTION/OBJECTIVES:** Carnitine uptake defect (CUD) is a rare autosomal recessive disorder caused by pathogenic variants in the SLC22A5 gene, resulting in primary carnitine transporter (OCTN2) deficiency and disturbed fatty acid oxidation. Patients may present in infancy with hypoketotic hypoglycemia, metabolic crisis, muscle weakness, cardiomyopathy, or sudden death, while some may remain asymptomatic even if not treated. We present a patient detected by newborn screening (NBS) who harbored a previously unreported homozygous variant in the SLC22A5 gene. OCTN2 activity testing showed mild deficiency.

**CASE PRESENTATION:** Third child of healthy and unrelated parents was screened positive for CUD by NBS (free carnitine 4.5 μmol/L (cut-off 8.8)). Follow-up testing showed low free carnitine in plasma and normal carnitine in maternal blood. The patient was supplemented with L- carnitine and the parents were advised about the feeding plan and crisis management. Genetic analysis identified a homozygous variant c.820\_821delTGinsGA (p.Trp274Glu) in the SLC22A5 gene, predicted to be damaging but unreported earlier, thus classified as a variant of unknown significance. OCTN2 activity in fibroblasts was 25% of the control value. The treatment and patient monitoring plan were adjusted accordingly.

**CONCLUSION:** CUD can cause serious medical complications if not treated. Patients diagnosed presymptomatically by NBS have an excellent prognosis. Phenotypic variability poses challenges for individualized treatment and patient management plans, especially in patients with novel variants. Confirmation of significant residual activity by functional testing in the presented patient assured tailored treatment and patient management plan, and reduced disease burden.


### CR58 ModuLife™- a novel dietary approach in management of a patient with moderate Crohn's disease

Alisa Fejzić<sup>a</sup>, Hana Franić<sup>a</sup>, Ana Barišić<sup>b</sup>, Irena Karas<sup>b</sup>

<sup>a</sup> School of Medicine, University of Zagreb, Zagreb, Croatia

<sup>b</sup> Clinical Unit of Clinical Nutrition, Department for Internal Medicine, University Hospital Centre Zagreb, Zagreb, Croatia

DOI: <https://doi.org/10.26800/LV-145-supl2-CR58>

 Alisa Fejzić 0009-0007-7442-8877, Hana Franić 0009-0003-7196-4261, Ana Barišić 0000-0003-1419-6967, Irena Karas 0000-0002-7979-2711

**KEYWORDS:** Crohn's disease; Crohn's disease exclusion diet; dietary therapy

**INTRODUCTION/OBJECTIVES:** microbiota, host barrier function, innate immunity, and the Crohn's disease (CD) is a chronic inflammatory bowel disease of unknown aetiology. Evidence demonstrate that a person's diet could be implicated in the pathogenesis of CD. Therefore, there is a growing interest in the use of diet as treatment or adjuvant therapy for CD. ModuLife is a dietary approach based on the Crohn's Disease Exclusion Diet (CDED) combined with a specific Partial Enteral Nutrition (PEN) formula, that aims to reduce exposure to dietary components hypothesized to negatively affect the microbiome, innate immunity and intestinal barrier.

**CASE PRESENTATION:** We present a case of a 34-year-male patient who was diagnosed with CD at the age of 31, after resection of 40 cm of jejunum and jejuno-jejunal anastomosis was performed due to small bowel stenoses. At that time, the patient was severely malnourished (BMI 17,4 kg/m<sup>2</sup>). After stabilization, he started with the second phase of Modulife diet in which 75% of his daily caloric and nutritional needs were met from specific foods and the other 25% from a specific PEN formula. During 6 months of ModuLife diet, patient nutritional status improved significantly (BMI 21.5 kg/m<sup>2</sup>) and he achieved clinical and biochemical remission. Currently, he is in deep remission and is still on the ModuLife diet, PEN intake is also reduced.

**CONCLUSION:** Modulife is a promising dietary approach for inducing and maintaining remission in mild to moderate CD. Due to the restrictive nature of this diet, it is important to work with a qualified health professional to ensure that the diet meets patients nutritional and caloric needs.


### CR59 Myocardial bridge stenting complicated by coronary artery perforation and midLAD right ventricle fistula formation in NSTEMI patient

Jelena Bošnjak<sup>a</sup>, Stela Marković<sup>a</sup>, Matias Trbušić<sup>b</sup>

<sup>a</sup> School of Medicine, University of Zagreb, Zagreb, Croatia

<sup>b</sup> Department of Cardiovascular Diseases, University Hospital Centre Sestre Milosrdnice, Zagreb, Croatia

DOI: <https://doi.org/10.26800/LV-145-supl2-CR59>

 Jelena Bošnjak (0000-0002-9598-8642, Stela Marković 0000-0003-2149-2422, Matias Trbušić 0000-0001-9428-454X

**KEYWORDS:** drug-eluting stents; myocardial bridging; percutaneous coronary intervention

**INTRODUCTION/OBJECTIVES:** Myocardial bridging (MB) is defined as a coronary artery that tunnels through the myocardium, under the overlying muscle bridge. It almost exclusively affects the left anterior descending artery (LAD), especially the middle part (midLAD).

**CASE PRESENTATION:** A 62-year-old male presented to the emergency department of University Hospital Centre Sestre Milosrdnice with acute myocardial infarction without ST-segment elevation. Before the event, the patient suffered from arterial hypertension and hyperlipidemia and was treated with bisoprolol, perindopril/amlodipine, and atorvastatin. Preprocedural echocardiography showed no wall motion disturbances. Coronary angiography was performed and a 15-mm-long MB of LAD was described with a fixed 80% stenosis (dynamic stenosis 90%). The patient was already taking optimal medical therapy, so percutaneous intervention was chosen as a treatment option. After predilatation, a drug-eluted stent was implanted. Soon after the stent placement, a large arterial perforation with a fistula to the right ventricle was observed. Because of the left-right shunt, the patient remained asymptomatic. Due to the progression of the contrast extravasation during the next few minutes and the inability to rule out the stent fracture, the stent graft was implanted. Contrast extravasation resolved completely. During the remaining hospital stay, the patient was free of symptoms and is doing well at follow-ups, without any ischemic symptoms.


**CONCLUSION:** Patients with MB can experience ischemic symptoms and the initial treatment approach should be medical. Patients who remain symptomatic despite medical therapy should be considered for surgical or interventional treatment. Stenting MB can lead to arterial perforation which can be treated successfully with covered stents.

### CR60 Myocardial Bridging: A cause for concern?

Marin Boban<sup>a</sup>, Antun Zvonimir Kovač<sup>a</sup>, Mladen Jukić<sup>a</sup>, Petar Medaković<sup>a</sup>

<sup>a</sup> Special hospital Agram, Zagreb, Croatia

DOI: <https://doi.org/10.26800/LV-145-supl2-CR60>

 Marin Boban 0000-0002-5552-0295, Antun Zvonimir Kovač 0000-0001-6276-4450, Mladen Jukić 0000-0002-3927-3888, Petar Medaković 0000-0002-7173-8286

**KEYWORDS:** Cardiovascular disease; Computed tomography; coronarography

**INTRODUCTION/OBJECTIVES:** Myocardial bridging (MB) is a condition where a segment of a coronary artery, which normally runs on the surface of the heart muscle, instead dives into the heart muscle and then re-emerges to continue its normal path. In MB, a segment of the coronary artery dives into the heart muscle during systole and re-emerges during diastole. This can lead to compression of the artery, reducing blood flow to the heart muscle during systole and causing symptoms such as chest pain or shortness of breath.

**CASE PRESENTATION:** The patient has been treating arterial hypertension for the past year and has recently been taking statin therapy, and a few days before coming to our clinic, he was treated in a hospital for anginal complaints that lasted for 20 minutes. Acute coronary syndrome was ruled out, ergometry was normal, ultrasound of the heart showed normal findings. Objectively, when he arrived at the clinic, he had no complaints, but he noticed shortness of breath during exertion. Does not smoke, occasionally consumes alcohol, positive family history of cardiovascular diseases. Considering the clinical signs and risk factors, indication for MSCT coronary angiography was made. There were no evident atherosclerotic plaques and/or narrowing on the coronary arteries, but a significant myocardial bridging was observed on the middle segment of the LAD at a distance of 25 mm.

**CONCLUSION:** MB is a relatively common condition, occurring in about 5-10% of the population. It can be diagnosed through tests such as coronary angiography, CT angiography, or cardiac MRI. In most cases, myocardial bridging is asymptomatic and does not require treatment. However, in cases where it causes symptoms, treatment options may include medications to manage symptoms or in rare cases, surgery to bypass or remove the affected segment of the artery.




## CR61 Obstipation as a manifestation of bilateral hydronephrosis

Marina Andrešić<sup>a</sup>, Nikolina Novak<sup>a</sup>, Josipa Živko<sup>a</sup>, Maša Sorić<sup>a</sup>

<sup>a</sup> Emergency Medicine Department, University Hospital Dubrava, Zagreb, Croatia

DOI: <https://doi.org/10.26800/LV-145-supl2-CR61>

 Marina Andrešić 0000-0002-3753-778X, Nikolina Novak 0000-0001-7416-7805, Josipa Živko 0000-0001-7297-5366, Maša Sorić 0000-0002-5002-9800

**KEYWORDS:** Hydronephrosis; Ultrasound; Intestinal Obstruction

**INTRODUCTION/OBJECTIVES:** Hydronephrosis is a progressive dilatation of the renal calyces due to obstruction of urine outflow. If left untreated, the disease progresses to kidney failure and death.

**CASE PRESENTATION:** A 59-year-old man presented to the emergency department with a 5-day history of obstipation and bloating. He had a permanent urinary catheter and had no complaints regarding it. Vital signs were normal. Physical examination revealed abdominal distension and diffuse abdominal tenderness without peritoneal guarding. Laboratory tests revealed elevated C-reactive protein (208.6mg/L), high creatinine (639µg/L), urea (30.5mmol/L), high white blood cell count (37.8x10<sup>9</sup>/L) with normal urinalysis. Immediately, point-of-care ultrasound was performed which revealed bilateral hydronephrosis (grade IV) and dilated small bowel loops with wall thickening, keyboard sign, and “to-and-fro” peristalsis, indicating small bowel obstruction. Abdominal computed tomography (CT) without contrast confirmed nephrolithiasis and bilateral ureterolithiasis without ileus due to a widespread prostatic neoplasm. A urologist was consulted and a bilateral percutaneous nephrostomy was performed and the patient was admitted for further treatment.

**CONCLUSION:** The purpose of this case report is to accentuate the importance of considering wide differential diagnoses in patients with abdominal symptoms and the benefit of point-of-care ultrasound in making the diagnoses, especially in patients not fit for contrast CT imaging.

## CR62 Personalized approach to patients with statin intolerance based on pharmacogenomics (function of OATP1B1 protein)


Anja Ćuk<sup>a</sup>, Doroteja Đekić<sup>a</sup>, Dunja Leskovar<sup>b</sup>, Livija Šimičević<sup>c</sup>

<sup>a</sup> School of Medicine, University of Zagreb, Zagreb, Croatia

<sup>b</sup> Division for Metabolic Diseases, Department of Internal Medicine, University Hospital Centre Zagreb, Zagreb, Croatia

<sup>c</sup> Division for Pharmacogenomics and Therapy Individualization, Department of Laboratory Diagnostics, University Hospital Centre Zagreb, Zagreb, Croatia

DOI: <https://doi.org/10.26800/LV-145-supl2-CR62>

 Anja Ćuk 0000-0002-5992-8327, Doroteja Đekić 0000-0002-2811-4398, Dunja Leskovar 0000-0002-2342-4450, Livija Šimičević 0000-0002-2491-1920

**KEYWORDS:** dyslipidemia; hmg coa statins; OATP1B1 protein, human; pharmacogenomics

**INTRODUCTION/OBJECTIVES:** Statins, HMG CoA reductase inhibitors, are effective at lowering blood cholesterol levels and protecting against cardiovascular incidents. Their uptake into hepatocytes depends on the activity of the SLCO1B1 gene which codes for the OATP1B1 transporter protein. Pharmacogenomic testing provides us information about the activity level of a certain protein. Lowered activity level of OATP1B1 protein can prolong the bioavailability of some drugs, such as statins. This greater systemic exposure to statins carries a higher risk of intolerance symptoms when compared to normal function of the OATP1B1 protein.

**CASE PRESENTATION:** We present two patients with dyslipidemia and statin intolerance symptoms. Female, 58, with history of multiple cardiovascular incidents presented with elevated liver function tests (GGT 1048, ALP 167, AST 219, ALT 93) while on atorvastatin therapy. After removal of the statin, her LFTs improved (GGT 419, ALP 122, AST 80, ALT 98) which indicated statin-induced liver lesion. Male, 55, also with history of cardiovascular incidents, came with muscle cramping in rest and high creatine-kinase (236 U/L) while on rosuvastatin therapy. In these cases, pharmacogenomic testing was indicated and in both patients the function of SLCO1B1\*5(c.521T>C) was lowered (\*1/\*5). Due to high cardiovascular risk and detected statin intolerance, both were candidates for PCSK9-inhibitors, monoclonal antibodies that lower cholesterol.

**CONCLUSION:** The example of these two patients shows us how pharmacogenomic testing can help in choosing the right therapy based on individuals' genetics.


### CR63 Pneumonitis as a side effect of breast cancer treatment: T-DXd and/or SBRT?

Džana Bjelić<sup>a</sup>, Sara Bogнар<sup>a</sup>, Jelena Benčić<sup>a</sup>, Manuela Bajan<sup>a</sup>, Natalija Dedić Plavetić<sup>b</sup>

<sup>a</sup> School of Medicine, University of Zagreb, Zagreb, Croatia

<sup>b</sup> Division of Medical Oncology, Department of Oncology, University Hospital Center Zagreb, Zagreb, Croatia

DOI: <https://doi.org/10.26800/LV-145-supl2-CR63>

 Džana Bjelić 0009-0002-2804-3777, Sara Bogнар 0009-0006-3830-9726, Jelena Benčić 0000-0002-2936-5201, Manuela Bajan 0000-0002-8859-4928, Natalija Dedić Plavetić 0000-0003-0505-4756

**KEYWORDS:** breast cancer; metastasis; pneumonitis; trastuzumab deruxtecan

**INTRODUCTION/OBJECTIVES:** Breast cancer that overexpresses the human epidermal growth factor receptor 2 (HER2) is considered to be HER2-positive. The novel HER2-directed antibody drug conjugate, trastuzumab deruxtecan (T-DXd), is formed by covalently joining the monoclonal antibody trastuzumab with the topoisomerase I inhibitor deruxtecan. It exhibits significant anti-tumor activity in previously overtreated patients.

**CASE PRESENTATION:** In January 2023, a 59-year-old woman with a history of HER2-positive metastatic breast cancer presented to the emergency room (ER) with shallow, fast breathing, dry cough, chest tightness, and intolerance to physical activity that had persisted for two days prior to admission. Additionally, she had a fever of up to 38.5 °C a week before, which was managed with acetaminophen. In 2016, she was diagnosed with early breast cancer and underwent a left mastectomy, adjuvant chemotherapy and anti-HER2 monoclonal antibody trastuzumab. Unfortunately, the patient developed lung metastases in 2017. Since then, she was treated with multiple lines of therapy for HER2 positive metastatic disease and stereotactic body radiation therapy (SBRT) for progressing lung mets. In August 2022, T-DXd therapy began. In January 2023, the day before admission to the ER, a CT scan revealed fresh lung consolidation with pneumonitis as a diagnosis. Prednisone, antitussive, and azithromycin were given. The patient was discharged, and symptoms resolved in a few days.

**CONCLUSION:** Interstitial lung disease/pneumonitis is a serious, and potentially life-threatening adverse event that is associated with T-DXd. Also, the use of SBRT to treat the lung metastases may have potentially exacerbated or perhaps completely caused the pneumonitis.


### CR64 Posaconazole-induced Glucocorticoid Deficiency in a Patient with Myelodysplastic syndrome.

Antonia Precali<sup>a</sup>, Ivana Kraljević<sup>a,b</sup>

<sup>a</sup> School of Medicine, University of Zagreb, Zagreb, Croatia

<sup>b</sup> Department of Endocrinology, University Hospital Centre Zagreb, Zagreb, Croatia

DOI: <https://doi.org/10.26800/LV-145-supl2-CR64>

 Antonia Precali 0000-0002-4206-0234, Ivana Kraljević 0000-0002-4379-2250

**KEYWORDS:** endocrinology; glucocorticoid deficiency; posaconazole

**INTRODUCTION/OBJECTIVES:** Primary adrenal insufficiency (Addison's disease) is a condition that is characterized by a lack of adrenal hormones - cortisol and aldosterone. The most common symptoms are fatigue and lack of energy, weakness, loss of appetite, and increased thirst. Additionally, darkening of the skin can occur. In most cases, Addison's disease has an autoimmune etiology, but in some cases, it can be caused by infections, adrenal hemorrhage, and medications that disrupt the steroidogenesis pathway.

**CASE PRESENTATION:** A 35-year-old female hematologic patient was admitted to an Endocrinology Outpatient Clinic due to fatigue, low levels of cortisol (52 nmol/L), and high levels of ACTH (34.1 pmol/L). In 2017 a patient was diagnosed with myelodysplastic syndrome with excess blasts, and in 2018 she received allogeneic hematopoietic stem cell transplantation with minor ABO incompatibility. Since then, she has taken antibiotics and antifungal prophylaxis, including posaconazole. Diagnosis of primary glucocorticoid insufficiency was made, most likely due to the intake of posaconazole. Normal potassium and sodium levels with normal aldosterone and renin levels and normal blood pressure suggested intact mineralocorticoid adrenal function. Substitution therapy with hydrocortisone was initiated, and subsequent check-ups showed normal findings with improved symptoms.

**CONCLUSION:** Posaconazole is an azole medication that is used in the treatment and prophylaxis of many fungal infections. However, some studies show that antifungals such as ketoconazole and posaconazole disrupt the steroid biosynthesis pathway and possibly can lead to adrenal disorders. The presented case shows a correlation between posaconazole usage and glucocorticoid deficiency, emphasizing the need to carefully monitor patients on posaconazole therapy.

## CR65 Pulmonary embolism as a cause of cardiac arrest in a patient after a stroke


Ena Parać<sup>a</sup>, Stjepan Herceg<sup>a</sup>, Marin Boban<sup>b</sup>, Paola Negovetić<sup>c</sup>, Nikolina Borščak Tolić<sup>a</sup>

<sup>a</sup> Clinical Hospital Sveti Duh, Zagreb, Croatia

<sup>b</sup> Department of Emergency Medicine Zagreb County, Croatia

<sup>c</sup> Health Center Zagreb Zapad, Zagreb, Croatia

DOI: <https://doi.org/10.26800/LV-145-supl2-CR65>

 Ena Parać 0000-0002-6759-8364, Stjepan Herceg 0000-0001-9543-4482, Marin Boban 0000-0002-5552-0295, Paola Negovetić 0000-0002-2658-5938, Nikolina Borščak Tolić 0009-0004-2987-231X

**KEYWORDS:** cardiopulmonary resuscitation; pulmonary embolism; stroke; thrombolysis

**INTRODUCTION/OBJECTIVES:** Stroke is a medical condition in which the blood supply to the brain is interrupted or reduced. Early in-hospital complications following a stroke are not only pneumonia, increased intracranial pressure and intracerebral bleeding, but also pulmonary embolism (PE). The main cause of PE is venous thromboembolism developed in a paralyzed lower extremity after a stroke.

**CASE PRESENTATION:** A 53-year-old male patient presented to our neurological emergency room with a clinical presentation of left-sided hemiparesis which was consistent with a cerebrovascular accident. Therefore, the patient was treated with thrombolysis using 70 mg of alteplase. Standard multi-slice computer tomography (MSCT) angiography revealed an embolus in the basilar artery, so surgical thrombectomy of the occluded artery was performed and the patient was subsequently stable. After 7 days, the patient suffered respiratory arrest, followed by cardiac arrest. Following a successful cardiopulmonary resuscitation with 8 mg of adrenaline administered, the patient underwent MSCT pulmonary angiography which unveiled a massive pulmonary embolism. Consequently, a bolus of 5000 IU of heparin was administered and the patient was transferred to an intensive care unit with blood pressure values of 120/80 mmHg and a heart rate of 100/min. The patient was stable and after 7 days was released home with anticoagulant therapy.

**CONCLUSION:** Even though the incidence of pulmonary embolism in a patient after a stroke is estimated to be around 1%, it has been accounted for over 50% of early deaths following a stroke. Therefore, the importance of thromboprophylaxis after a stroke is one of the quality measures in many stroke units around the world.


## CR66 Rare complications of Sjögren's syndrome in a female patient

Tin Rosan<sup>a</sup>, Jana Jelenić<sup>a</sup>, Marija Bakula<sup>a,b</sup>

<sup>a</sup> School of Medicine, University of Zagreb, Zagreb, Croatia

<sup>b</sup> Division of Clinical Immunology and Rheumatology, Department of Internal Medicine, University Hospital Centre Zagreb, Zagreb, Croatia

DOI: <https://doi.org/10.26800/LV-145-supl2-CR66>

 Tin Rosan 0000-0002-7585-5770, Jana Jelenić 0000-0002-1550-5111, Marija Bakula 0000-0002-0176-362X


**KEYWORDS:** central nervous system; congenital heart block; Sjögren's syndrome; SSA-antibodies

**INTRODUCTION/OBJECTIVES:** Sjögren's syndrome (SjS) is a systemic autoimmune disease, most common in middle-aged women, characterized by chronic inflammation of exocrine glands. It can present by itself or alongside other autoimmune diseases. Main symptoms are dry eyes and mouth, but the disease can affect joints, lungs, kidneys, peripheral nervous system (PNS), and rarely central nervous system (CNS). SS-A antibodies in SjS can pass the fetoplacental barrier and cause congenital heart block. Patients with SjS are at higher risk of developing lymphoma.

**CASE PRESENTATION:** We present a case of a 40-year-old woman who was diagnosed with SjS in 2009, presenting with dry eyes and mouth, arthritis, alongside vasculitis i.e. purpura of the shins. She was treated with prednisone and chloroquine. In 2008 she gave birth to a child with complete atrioventricular block. Recently she complained of foot numbness without motor weakness. Now she was hospitalized due to symptoms of meningoencephalitis. Cerebrospinal fluid (CSF) analysis was positive for oligoclonal bands. CSF, urine, and blood cultures were sterile. MRI showed pathomorphological findings in cauda equina. Neuropathy of thin sensory and motor fibers was found on electromyoneurography. The patient was treated with antibiotics, methylprednisolone, intravenous immunoglobulins, and supportive measures. She recovered completely and azathioprine was introduced for maintaining remission.

**CONCLUSION:** Overall nervous system manifestations are described in 20% of patients with primary SjS, but CNS manifestations are described rarely. Congenital heart block is described in 2% of the pregnancies in mothers with SS-A antibodies. With timely introduction of immunosuppressants the conditions are treatable and preventable.




**CR67 Recurrent acute pancreatitis**Hana Franić<sup>a</sup>, Alisa Fejzić<sup>a</sup>, Nedo Marčinković<sup>b</sup><sup>a</sup> School of Medicine, University of Zagreb, Zagreb, Croatia<sup>b</sup> Division for Pediatric Gastroenterology, Department of Pediatrics; University Hospital Centre Zagreb, Zagreb, CroatiaDOI: <https://doi.org/10.26800/LV-145-supl2-CR67> Hana Franić 0009-0003-7196-4261, Alisa Fejzić 0009-0007-7442-8877, Nedo Marčinković 0009-0007-7442-8877**KEYWORDS:** CBD stenosis; pancreatitis; pancreatobiliary anomalies

**INTRODUCTION/OBJECTIVES:** Acute pancreatitis is an inflammation of the pancreas that is clinically characterized by severe abdominal pain, nausea and vomiting, combined with elevated serum digestive enzymes. The etiology of pancreatitis in children differs from adult patients with predominance of abdominal trauma (23%) and pancreatobiliary anomalies (15%) while in almost 25% of cases, the etiology remains unknown.

**CASE PRESENTATION:** We present a patient, now a 15-year-old girl who first presented at the age of 4 with abdominal pain, vomiting and laboratory findings of elevated aspartate transaminase (AST) and alanine transaminase (ALT). Ultrasound showed dilated intrahepatic and extrahepatic bile ducts. Endoscopic retrograde cholangiopancreatography (ERCP) revealed complete obstruction of common bile duct (CBD) and as a therapeutic measure a stent was inserted. The patient recovered completely, and the stent was removed three months later. This patient presented again with symptoms of pancreatitis at the age of 8 which resulted with insertion of 2 stents, one into the pancreatic duct and one into the CBD, followed by a complete recovery. After a year both stents were removed, and since then the girl didn't have new episodes, she is in good health without a strict diet. After several diagnostic procedures (magnetic resonance cholangiopancreatography, ERCP, liver biopsy) a diagnosis of congenital anomaly of pancreaticoduodenal junction was made.

**CONCLUSION:** Given the frequency of anomalies in pediatric patients with recurrent pancreatitis, developmental anomalies should be suspected. In this specific case, as the child developed, so did the bile ducts, and the stenting was just a method of temporarily relief. Now this anomaly is not interfering with normal bile outflow.


**CR68 Senile purpura, disseminated intravascular coagulation or a crime scene?**Kristijan Harak<sup>a</sup>, Lidija Ister<sup>a</sup>, Marta Grgat<sup>b</sup>, Lana Ivanišević<sup>c</sup><sup>a</sup> Health Centre of Zagreb County, Croatia<sup>b</sup> Special Hospital for Chronic Childhood Diseases, Gornja Bistra, Croatia<sup>c</sup> County Hospital Čakovec, CroatiaDOI: <https://doi.org/10.26800/LV-145-supl2-CR68> Kristijan Harak 0000-0002-1501-1955, Lidija Ister 0009-0002-1206-2340, Marta Grgat 0000-0003-4701-4082, Lana Ivanišević 0009-0007-0280-428X**KEYWORDS:** pneumonia; purpura; warfarin

**INTRODUCTION/OBJECTIVES:** In the background of seemingly harmless bacterial pneumonia, unresolved family problems are potentially the cause of a fatal outcome.

**CASE PRESENTATION:** We discuss the case of a 82-year-old female patient who came to the general practice complaining of fever, skin lesions and fatigue. The patient began experiencing symptoms ten days prior to admission. Past medical history showed arterial hypertension, permanent atrial fibrillation and COPD. She was taking ACE inhibitor, calcium-channel blocker, coumarin anticoagulant, anticholinergic agent and was on continuous oxygen therapy (1 L/min). She was presented with tachycardia (104/min) and low spot oxygen saturation (SpO<sub>2</sub> 82% without O<sub>2</sub> and 88% with O<sub>2</sub>). Other vital signs were stable. Physical examination showed fine lung crackles at bases and tiny petechiae on both of her lower legs. ECG showed no gross abnormalities. Blood taken for the laboratory tests showed mild erythrocytosis, neutrophilia and elevated CRP. Her INR was around 3,4. She insisted to be treated with antibiotic and refused to be admitted to the hospital. Although blood tests taken four days after the doctor's visit showed improvement in differential blood count and CRP, she was admitted to the hospital because of INR > 6 and deteriorated general condition. It was later discovered that her husband was giving her twice the daily dose of warfarin in the last seven days which could have been the cause of purpura on the lower legs and intracranial bleeding later on.

**CONCLUSION:** In addition to a detailed auto- and heteroanamnesis, it is advisable to be familiar with the family situation so as not to overlook less probable causes of the disease.

**CR69 Spinal shock after a ground-level fall**Leo Matijašević<sup>a</sup>, Ines Trkulja<sup>b</sup>, Andrija Matijević<sup>a</sup>, Danijel Mikulić<sup>c</sup>, Filip Miočinović<sup>d</sup>, Iva Barišić<sup>e</sup><sup>a</sup> Department of Emergency Medicine, University Hospital Centre Zagreb, Zagreb, Croatia<sup>b</sup> Institute of Emergency Medicine of Sisak-Moslavina County, Croatia<sup>c</sup> Sestre milosrdnice University Hospital Center, Zagreb, Croatia<sup>d</sup> University hospital "Sveti Duh", Zagreb, Croatia<sup>e</sup> General Hospital Zabok, Zabok, CroatiaDOI: <https://doi.org/10.26800/LV-145-supl2-CR69>

 Leo Matijašević 0000-0002-7010-9111, Ines Trkulja 0000-0002-3482-8733, Andrija Matijević 0000-0002-0483-1392, Danijel Mikulić 0000-0001-9176-2091, Filip Miočinović 0009-0004-5709-6370, Iva Barišić 0000-0003-2964-0901


**KEYWORDS:** Acute Disease; Decompression; Spinal Cord Injuries; Quadriplegia

**INTRODUCTION/OBJECTIVES:** Falls are the most common cause of spinal cord injuries (SCIs) in patients older than 65. The worldwide annual incidence of SCIs is reported to be around 15 – 40/ 1000000.

**CASE PRESENTATION:** A 66-year-old male was admitted after a ground-level fall while heading to work. The patient was experiencing retrograde amnesia. He presented with a bleeding forehead wound, pain in the right arm, tachycardia 137/min and hypotension 90/50 mmHg. Motor and sensory function was preserved in arms, but completely lost in lower extremities. Loss of sensation below Th4 was detected. Bowel and bladder control was absent. Eye movements were preserved with GCS 15. Computed tomography (CT) scan showed no signs of intracranial hemorrhage or acute ischemia. CT angiography ruled out aortic dissection and bleeding. Magnetic Resonance Imaging (MRI) showed medullary edema from C3/C4 to C5/C6 with severe stenosis of the spinal canal and an obliterated liquor space. The abnormal dorsal position of C5 and traumatic tear of the C5/C6 intervertebral disc were described. Quadriplegia was present at the time the patient underwent an urgent C5/C6 disc ablation spinal decompression, and an anterior spondylodesis of C5 and C6. Amiodarone was administered due to 140/min tachycardia in the intensive care unit (ICU). During the fourth day in the ICU the patient was awake, moved his arms, regained sensation to the sternal level and moved his legs with difficulty.

**CONCLUSION:** This case shows that ground-level falls can lead to severe injuries and a potentially lethal outcome. A well-coordinated multidisciplinary approach was crucial for this patient's recovery.

**CR70 Spontaneous renal artery dissection possibly associated with antiphospholipid syndrome**Gabrijela Buljan<sup>a</sup>, Antonia Bukovac<sup>a</sup>, Ingrid Prkačin<sup>b</sup><sup>a</sup> School of Medicine, University of Zagreb, Zagreb, Croatia<sup>b</sup> Emergency internal medicine department, Clinical hospital Merkur, Zagreb, CroatiaDOI: <https://doi.org/10.26800/LV-145-supl2-CR70>

 Gabrijela Buljan 0000-0003-4060-9497, Antonia Bukovac 0000-0002-0412-433X, Ingrid Prkačin 0000-0002-5830-7131

**KEYWORDS:** abdominal pain; antiphospholipid syndrome; artery dissection

**INTRODUCTION/OBJECTIVES:** Spontaneous renal artery dissection (SRAD) is a rare clinical event which most commonly presents with nonspecific symptoms such as acute flank pain, hypertension, fever, hematuria. It rarely occurs as an isolated, non-traumatic event and in those cases the underlying causes include atherosclerosis, fibromuscular dysplasia, collagen vascular disease and severe exertion. Only a few case reports suggest a possible connection between SRAD and antiphospholipid syndrome (APS).

**CASE PRESENTATION:** A 54-year-old female presented to the ER with acute left-sided abdominal pain. The patient was formerly healthy aside from previously verified but undefined coagulation disorder. The physical examination was completely unremarkable as well as the abdominal ultrasound. The patient was referred to do MSCT of the abdomen during which she became hypotensive and collapsed. She was urgently transported to the operating room and a retroperitoneal hematoma was found, whose cause was a left renal artery dissection. As it was not possible to perform revascularisation, the patient successfully underwent left nephrectomy and splenectomy. She was then put on symptomatic and antihypertensive therapy and remained long-term stabilized. During the following testing she was diagnosed with primary APS which is considered to be the probable cause of SRAD in this case, as other possible common causes were excluded.

**CONCLUSION:** There are some reports of arterial dissections in different sites of the body all associated with APS which is why it is suspected that APS may be a potential cause of vasculopathy and arterial dissection. Further research is required to explore and explain this potential association.


## CR71 The Importance of a Watchful Eye: Multiple Infections in Immunocompromised Patient

Ana Klobučar<sup>a</sup>, Tian Košar<sup>a</sup>, Nadira Duraković<sup>a,b</sup>

<sup>a</sup> School of Medicine, University of Zagreb, Zagreb, Croatia

<sup>b</sup> Division of Hematology, University Hospital Centre Zagreb, Zagreb, Croatia

DOI: <https://doi.org/10.26800/LV-145-supl2-CR71>

 Ana Klobučar 0009-0001-9059-1064, Tian Košar 0009-0006-6158-251X, Nadira Duraković 0000-0001-5842-0911

**KEYWORDS:** immunocompromised host; non-Hodgkin's lymphoma; *Pneumocystis pneumonia*

**INTRODUCTION/OBJECTIVES:** Immunocompromised patients are a unique subset of the population that require special attention and care. These individuals are susceptible to a wide range of infections and illnesses, and even minor symptoms can be indicative of a more serious underlying condition. Unfortunately, due to the immunocompromised state, symptoms can often be less severe or easily overlooked, leading to delayed diagnosis and treatment.

**CASE PRESENTATION:** A 77-year-old female patient presents to the ER complaining of breathing difficulties, productive cough, and fever. 11 days earlier, she reported catarrhal symptoms. The patient is being treated for marginal zone non-Hodgkin B-cell lymphoma and is currently receiving R-CVP chemotherapy protocol and corticosteroids. Both her condition and treatment make her immunocompromised, so she was prescribed levofloxacin which she did not take. From the ER, the patient was admitted to the hematology department and further work-up was done. CRP was unremarkably elevated, but chest X-ray showed perihilar destruction of the right lung. Bronchoalveolar lavage came back positive for CMV, EBV, *Klebsiella pneumoniae*, *Enterococcus raffinosus*, and *Pneumocystis jirovecii*.

**CONCLUSION:** This case report highlights the importance of recognizing and addressing even minor symptoms in immunocompromised patients and the importance of vigilant monitoring and prompt intervention in this vulnerable population to prevent the development of more serious conditions. It also highlights the need for clinicians to maintain a high index of suspicion and promptly investigate any changes in the patient's condition, no matter how minor they may seem.


## CR72 The importance of CT-guided adrenal biopsy in an oncological patient: a case report

Ante Listeš<sup>a</sup>, Tajana Turk<sup>b</sup>

<sup>a</sup> Faculty of Medicine, Josip Juraj Strossmayer University of Osijek, Osijek, Croatia

<sup>b</sup> Department of Diagnostic and Interventional Radiology, University Hospital Center Osijek, Osijek, Croatia

DOI: <https://doi.org/10.26800/LV-145-supl2-CR72>

 Ante Listeš 0000-0002-7314-3905, Tajana Turk 0000-0003-1535-1359

**KEYWORDS:** adrenal glands; biopsy; computed tomography; metastases

**INTRODUCTION/OBJECTIVES:** Image-guided percutaneous biopsy is a common and safe interventional radiology procedure with the purpose of tissue sampling for pathological evaluation. It is usually performed under ultrasound or computed tomography (CT) guidance for easily reachable, as well as difficult to reach, tumors in order to avoid surgical open biopsy.

**CASE PRESENTATION:** We present a 67-year-old male patient with a history of bilateral nephrectomy due to right kidney renal carcinoma (RCC) and left kidney high-grade transitional cell carcinoma (TCC). Two years following the second nephrectomy, bilateral adrenal metastases were detected on CT and MRI imaging. Since the treatment differs whether metastases are from TCC or RCC, the patient was scheduled for a bilateral percutaneous biopsy. The material was sent for pathohistology where the results showed that the metastases were from RCC. The patient was well after the procedure but became hypotensive in the evening. Emergency CT showed left-sided hemothorax and large left-sided retroperitoneal hematoma extending to the small pelvis. Emergency laparotomy was performed for the evacuation of the hematoma and the adrenal gland, as well as a drainage procedure of the left pleural space. Subsequent pathohistology showed that the metastases were from RCC and the patient received appropriate chemotherapy.

**CONCLUSION:** Image-guided percutaneous biopsy is an accurate and safe alternative to surgical biopsy, but can also lead to potentially life-threatening complications. In our patient, this procedure was mandatory before choosing the appropriate medical treatment.




### CR73 Transcatheter Pulmonary Valve-in-Valve Implantation due to Severe Valve Stenosis Following Bioprosthetic Pulmonary Valve Replacement Degeneration

Helena Ljulj<sup>a</sup>, Sara Komljenović<sup>a</sup>, Antonia Lovrenčić<sup>a</sup>, Mario Udovičić<sup>b</sup>

<sup>a</sup> School of Medicine, University of Zagreb, Zagreb, Croatia

<sup>b</sup> Department of Cardiology, University Hospital Dubrava, Zagreb, Croatia

DOI: <https://doi.org/10.26800/LV-145-supl2-CR73>

 Helena Ljulj 0000-0002-1851-4419, Sara Komljenović 0000-0002-0323-078X, Antonia Lovrenčić 0000-0002-5576-0360, Mario Udovičić 0000-0001-9912-2179

**KEYWORDS:** Case Report; Foreign Body; Heart; Heart Valve Prosthesis Implantation

**INTRODUCTION/OBJECTIVES:** Transcatheter pulmonary valve-in-valve implantation (TPVI) is a rare procedure consisting of the implantation of a new valve inside the degenerated old pulmonary valve (PV). We present a distinctive case of a patient undergoing the procedure, following degeneration of a previously implanted bioprosthetic PV replacement.

**CASE PRESENTATION:** A 59-year-old male was admitted to the emergency department due to presyncope and dyspnea and signs of right heart failure. Ten years prior to the hospitalization he had undergone several hospitalizations due to sepsis, caused by a sewing needle localized in the right ventricular outflow tract (RVOT) which was a consequence of apparent self-mutilation. The patient had initially refused a surgical removal which resulted in deterioration of clinical state and development of pulmonary valve (PV) endocarditis, requiring cardiac surgery, consisting of needle removal, bioprosthetic PV replacement, and tricuspid valvuloplasty with ring insertion. Following the procedure until this hospitalization, the patient was asymptomatic. Current echocardiography showed advanced degenerative changes of the bioprosthetic PV, with consequent severe pulmonary stenosis and regurgitation (pulmonic valve peak velocity 3,97 m/s, pulmonic valve peak gradient 63 mmHg, mean pressure gradient 35 mmHg). After discussion by the Heart Team, the patient underwent a successful valve-in-valve TPVI, which resulted in clinical improvement.

**CONCLUSION:** Transcatheter pulmonary valve-in-valve implantation may be a viable option for patients with pulmonary stenosis due to degenerative changes of bioprosthetic pulmonary valve.


### CR74 Treatment of enterocutaneous fistula with total parenteral nutrition in combination with octreotide: a case report

Antonia Alfirević<sup>a</sup>, Dina Ljubas Kelečić<sup>b</sup>, Patricia Barić<sup>a</sup>, Ana Barišić<sup>a,b</sup>

<sup>a</sup> School of Medicine, University of Zagreb, Zagreb, Croatia

<sup>b</sup> Clinical Unit of Clinical Nutrition, Department of Internal Medicine, University Hospital Zagreb, Zagreb, Croatia

DOI: <https://doi.org/10.26800/LV-145-supl2-CR74>

 Antonia Alfirević 0000-0003-1339-5294, Dina Ljubas Kelečić 0000-0003-4310-7580, Patricia Barić 0000-0002-7507-4149, Ana Barišić 0000-0003-1419-6967

**KEYWORDS:** enterocutaneous fistula; octreotide; total parenteral nutrition

**INTRODUCTION/OBJECTIVES:** Octreotide is an analog of the polypeptide hormone somatostatin, which can reduce gastrointestinal, biliary and pancreas secretion, as well as decrease gastrointestinal motility. Octreotide in combination with total parenteral nutrition (TPN) has proven to be effective therapy in patients with high-output enterocutaneous fistula (EF).

**CASE PRESENTATION:** We report a case of a 29-year-old female patient with Peutz-Jeghers syndrome who underwent resection of 80 cm of jejunum with formation of jejuno-jejunal anastomosis due to intestinal intussusception. Postoperatively, patient developed suppurative intraabdominal collection and high output EF. Oral intake was restricted, and TPN was introduced in addition to broad-spectrum antibiotics and wound care. In addition, 3x50 µg/day octreotide subcutaneously and proton pump inhibitor was started. After three days, dose of octreotide was increased (3x100 µg/day). These resulted in dramatic reduction of the fistula drainage seven days after therapy was started. 20th day of octreotide therapy, drainage stopped completely, therefore we started a peroral nutrition which led to recurrence of fistula secretion. Abdominal MSCT showed remaining EF, therefore we decreased oral intake and continued octreotide therapy, along with TPN. 40 days after intravenous therapy with octreotide, fistula closure occurred. Long-acting release (LAR) octreotide administered intramuscularly at a dose 20 mg monthly was introduced for the next three months. Octreotide administration was well tolerated and led to complete fistula closure.

**CONCLUSION:** Although TPN is a cornerstone of conservative management of postoperative EF, octreotide administration could be considered in order to shorten the time to fistula closure, the requirement of PN and hospital stay.


## CR75 Unrecognized psychosis leads to severe hyponatremia, a case report

Frano Šušak<sup>a</sup>, Luka Bielen<sup>a,b</sup>

<sup>a</sup> School of Medicine, University of Zagreb, Zagreb, Croatia

<sup>b</sup> Division for Intensive Care Medicine, Department of Internal Medicine, University Hospital Centre Zagreb, Zagreb, Croatia

DOI: <https://doi.org/10.26800/LV-145-supl2-CR75>

 Frano Šušak 0000-0002-3866-2814, Luka Bielen 0000-0001-5782-4367

**KEYWORDS:** Hyponatremia; Psychogenic Polydipsia; Psychotic Disorders; Seizures

**INTRODUCTION/OBJECTIVES:** Hyponatremia is the most common electrolyte disorder and psychogenic polydipsia (PPD) is one of the many possible causes. We present a case of severe hyponatremia in a patient with unrecognized psychosis. **CASE PRESENTATION:** A 39-year-old male with past medical history of surgically removed pelvic chondrosarcoma presented to the emergency department confused and disoriented. During the examination, he developed a generalized tonic-clonic seizure that was terminated by diazepam. Laboratory workup demonstrated severe hyponatremia (106 mmol/l) and hypokalemia (1,7 mmol/l). After the administration of 3% saline, he was admitted to the intensive care unit where he received normal saline and potassium chloride. During the eight hours, he had a urine output of 7100 ml which led to a rapid rise of sodium to 135 mmol/L. Therefore, the risk of osmotic demyelination syndrome (ODS) was recognized and the serum sodium was re-lowered with desmopressin and 5% glucose. The next day, patient's level of consciousness normalized and he stated that he recently started a new alternative diet with significantly increased water intake to get rid of "micrometastases" which he believed were still present. He described having coughed and defecated some of the "micrometastases". The patient was diagnosed with psychosis and was given an antipsychotic. He had a complete recovery with no signs of ODS. On an outpatient control, he was taking fluphenazine and diazepam, and both sodium and potassium were normal.

**CONCLUSION:** PPD can cause severe life-threatening hyponatremia and its treatment can be complicated by overcorrection of serum sodium due to hypoosmolality-induced suppression of antidiuretic hormone secretion.


## CR76 100 BLOOD TRANSFUSIONS IN 10 MONTHS DUE TO HEYDE SYNDROME

Iva Barišić<sup>a</sup>, Ozana Miličević<sup>b</sup>, Leo Matijašević<sup>b</sup>, Luka Blažević<sup>a</sup>

<sup>a</sup> General Hospital Zabok, Zabok, Croatia

<sup>b</sup> Department of emergency medicine, University Hospital Centre Zagreb, Zagreb, Croatia

DOI: <https://doi.org/10.26800/LV-145-supl2-CR76>

 Iva Barišić 0000-0003-2964-0901, Ozana Miličević 0000-0003-0289-3386, Leo Matijašević 0000-0002-7010-9111, Luka Blažević 0000-0001-9451-531X

**KEYWORDS:** aortic stenosis; blood transfusion; Heyde syndrome

**INTRODUCTION/OBJECTIVES:** Heyde syndrome is a multisystem disorder characterized by an association between gastrointestinal bleeding and aortic stenosis. High shear stress on stenotic valves leads to acquired coagulopathy due to proteolysis of von Willebrand factor and thus leads to bleeding from angiodysplasias of the digestive system.

**CASE PRESENTATION:** We present a case of a 72-year-old female patient who reported to the emergency department due to verified anemia in lab findings. At the age of 54 she had a mechanical aortic valve implanted. The clinical examination revealed black stool, pallor of the skin, systolic ejection murmur with expansion into the right carotid artery, as well as the click of a mechanical valve. After severe microcytic anemia was discovered, the workup revealed restenosis of the implanted aortic valve, as well as the multiple angiodysplasias of the gastric mucosa. Despite two attempts to stop intestinal bleeding with argon plasma coagulation, the bleeding persisted aggravated by anticoagulant therapy. In the beginning, the periods between repeated transfusions were about 15 days, but soon after her condition required three doses of erythrocyte concentrate every 3 to 4 days. Hemoglobin values, despite repeated transfusions, hovered around 50 g/L. In total, the patient received more than 100 doses of erythrocyte concentrate in less than 10 months.

**CONCLUSION:** This case shows extraordinary tolerance of frequent transfusions without a single new complication. Here, blood transfusions are shown to be a method of immediate treatment of the severe consequences of Heyde syndrome until a definitive solution is found.


## CR77 Vertebrobasilar insufficiency due to subclavian-vertebral artery steal

Marina Nađ<sup>a</sup>, Mladen Pospišil<sup>b</sup>, Eva Pleško<sup>b</sup>

<sup>a</sup> School of Medicine, University of Zagreb, Zagreb, Croatia

<sup>b</sup> Krapina-Zagorje County Community Health Center, Gornja Stubica, Croatia

DOI: <https://doi.org/10.26800/LV-145-supl2-CR77>

 Marina Nađ 0000-0003-1356-7551, Mladen Pospišil 0000-0002-9462-2593, Eva Pleško 0000-0003-2925-359

**KEYWORDS:** angiography, brainstem, subclavian steal

**INTRODUCTION/OBJECTIVES:** Subclavian-vertebral artery steal is an occurrence of a retrograde blood flow in the ipsilateral vertebral artery when an occlusion or hemodynamically significant stenosis of the subclavian artery proximal to the origination of the vertebral artery impair normal blood flow to the arm and the brainstem.

**CASE PRESENTATION:** We report a 68-year-old male patient who was admitted to the neurology emergency room with the transient vertigo, vomiting, ataxia, dysarthria and diplopia that worsen during manual labor. Patient's history revealed stroke risk factors like hypertension, hyperlipidemia and smoking. The initial CTA of the vertebrobasilar system showed no signs of occlusion or stenosis but a Doppler ultrasound displayed a retrograde flow in the right vertebral artery therefore CT angiography of the branches of the aortic arch was carried out. It confirmed right subclavian artery occlusion proximal to the origin of the vertebral artery. Contraindications for the carotid-subclavian bypass surgery were excluded with preoperative preparations and the operation was conducted under general anesthesia. The occlusion of the subclavian artery was bypassed with a straight collagen coated 7-mm in diameter vascular graft. The surgery proceeded without complications and on the third postoperative day the patient was discharged in a good general condition without neurological symptoms. Take-home recommendations included smoking cessation, hypertension and hyperlipidemia control and physical activity.


**CONCLUSION:** Subclavian-vertebral artery steal is predominantly asymptomatic and does not warrant invasive evaluation or treatment but in some rare cases when quality of life is being impaired a carotid-subclavian bypass surgery is the treatment of choice.

## CR78 Virchow's node as the first manifestation of disseminated prostatic cancer

Tina Stanković<sup>a</sup>, Maja Alaber<sup>a</sup>, Maša Sorić<sup>a</sup>

<sup>a</sup> Emergency Department, University Hospital Dubrava, Zagreb, Croatia

DOI: <https://doi.org/10.26800/LV-145-supl2-CR78>

 Tina Stanković 0009-0004-5549-3292, Maja Alaber 0009-0000-2090-1306, Maša Sorić 0000-0002-5002-9800

**KEYWORDS:** Lymphadenopathy; Neoplasm Metastasis; Prostate cancer

**INTRODUCTION/OBJECTIVES:** Prostate cancer is the second most common malignant tumour in men. It usually presents with lower urinary tract symptoms and spreads to the regional lymph nodes. Metastasis to Virchow's node (left supraclavicular lymphadenopathy) is rare and often associated with other types of cancer, such as gastric, lung and breast cancer. We present the case of a patient with enlarged left supraclavicular nodes as the first manifestation of disseminated adenocarcinoma of the prostate.

**CASE PRESENTATION:** An 80-year-old male patient presented to the emergency department because of a painless swelling on the left side of his neck. Physical examination showed firm, painless lump in the left supraclavicular region. An emergency ultrasound of the neck and a fine needle aspiration cytology of the node verified the diagnosis of metastasis of a poorly differentiated carcinoma. Furthermore, the MSCT of the thorax and abdomen displayed enlarged lymph nodes in the mediastinum, left axillary area, left supraclavicular region, retroperitoneally, paraaortically, and bilaterally next to large blood vessels. The MSCT also showed enlarged prostate and grade 3/4 hydronephrosis on the left side. Patient was further referred to a urologist. The PSA levels were significantly elevated, which indicated a prostate biopsy. The histopathological finding revealed acinar adenocarcinoma of the prostate, grade 4 (Gleason 4+4). The chosen method of treatment included surgical castration followed by androgen suppression therapy.

**CONCLUSION:** This case report demonstrates the importance of considering prostate cancer as a rare but possible differential diagnosis of men presenting with enlarged Virchow's node.



## CR79 Whole Genome Joint Analysis for identification of rare non-coding causative variants - case report of a child with mitochondrial disease

Dina Gržan<sup>a</sup>, Marjan Kulaš<sup>a</sup>, Lea Jukić<sup>a</sup>, Petra Sulić<sup>b,c</sup>, Mario Ćuk<sup>a,c,d</sup>


<sup>a</sup> School of Medicine, University of Zagreb, Zagreb, Croatia

<sup>b</sup> General Hospital "Dr. Ivo Pedišić"–Sisak, Sisak, Croatia

<sup>c</sup> "Mila za Sve" Foundation and CroSeq-Genome Bank Research Project, Rijeka/Zagreb, Croatia

<sup>d</sup> Department of Pediatrics, University Hospital Centre Zagreb, Zagreb, Croatia

DOI: <https://doi.org/10.26800/LV-145-supl2-CR79>

 Dina Gržan 0000-0002-3312-5569, Marjan Kulaš 0000-0001-5140-8514, Lea Jukić 0000-0002-1976-7258, Petra Sulić 0000-0002-2474-4763, Mario Ćuk 0000-0002-7119-133X

**KEYWORDS:** Mitochondrial Diseases; Mutation; Whole Genome Sequencing

**INTRODUCTION/OBJECTIVES:** Pediatric genetic conditions are caused by a spectrum of genomic alterations, including non-coding variants, which often fail to be identified using low throughput methods. Whole genome sequencing (WGS) can detect the full spectrum of genome alterations simultaneously, comprehensively, and unbiasedly.

**CASE PRESENTATION:** We present a 3-year-old girl with a Mitochondrial complex I deficiency, nuclear type 3 (MC1DN3), caused by a biallelic mutation in the NDUFS7 gene, encoding a subunit protein of a complex forming the mitochondrial respiratory chain. As a newborn, she presented with progressive multiorgan deterioration, hypoglycemia, hypocalcemia, hypokalemia, lactatemia, metabolic alkalosis, hypernatremia, hypomagnesemia, hyperphosphatemia, and signs of mitochondrial dysfunction in organic acids. She was stabilized and started habilitation. Currently, she is uncoordinated, fatigued, and has impaired speech. A joint analysis of the child's and her family's entire genome was done under the "CroSeq-GenomeBank" project. As a result, a rare non-coding causative variant in the NDUFS7 gene in the homozygous composition was identified, and she was diagnosed with MC1DN3. This autosomal recessive disease causes dysfunction of energy production in the mitochondria with a heterogenous and unpredictable clinical course with symptomatic treatment.

**CONCLUSION:** With the evolution of diagnostic methods, more non-coding variants are being discovered and connected to various pathological conditions. Although diagnosing is challenging given the unspecific clinical presentation, early detection is possible using innovative and precise techniques such as Joint-WGS. The infrastructure of the "CroSeq-GenomeBank" has brought this foundation of personalized medicine to Croatia, keeping us in step with highly developed countries.


## CR80 USE OF IMMUNOTHERAPY IN THE TREATMENT OF A PATIENT WITH TWO SIMULTANEOUS METASTATIC DISEASES

Matej Penava<sup>a</sup>, Anđelo Kurtin<sup>a</sup>, Katarina Čular<sup>b</sup>, Tajana Silovski<sup>b</sup>

<sup>a</sup> School of Medicine, University of Zagreb, Zagreb

<sup>b</sup> Department of Oncology, University Hospital Center Zagreb

DOI: <https://doi.org/10.26800/LV-145-supl2-CR80>

 Matej Penava 0009-0006-7833-407X, Anđelo Kurtin 0009-0002-7121-8982, Katarina Čular 0000-0002-0454-4270, Tajana Silovski 0000-0002-4699-5432

**KEYWORDS:** Immunotherapy; Metastatic disease; Nivolumab

**INTRODUCTION/OBJECTIVES:** Immunotherapy is an evolving and promising cancer treatment proven to significantly prolong survival in a multitude of oncological diseases. Nivolumab, a monoclonal antibody to the PD-1 receptor, is an immunotherapy used in the treatment of several cancers, including melanoma and renal cell carcinoma (RCC). **CASE PRESENTATION:** Initially, 44-year-old patient underwent nephrectomy due to RCC and two years later an excision of melanoma on the lower leg. 23-years later, he reported with fatigue, weight loss and anemia. PET/CT detected metabolically active mass in the pancreas and subcutaneous accumulation on the left leg. Biopsy confirmed RCC metastasis in the pancreas while the excision of leg lesion revealed melanoma metastasis with BRAF mutation. As melanoma metastasis was removed, and the only confirmed active malignancy was RCC metastasis, treatment with sunitinib was started. After four months, the patient was admitted to emergency room due to small intestine obstruction which was surgically treated and PHD revealed melanoma metastasis. Sunitinib therapy was continued due to good response for five months when new melanoma metastases occurred, and instead of sunitinib, nivolumab immunotherapy was started. Follow-up PET/CTs showed lower metabolic activity in all metastases. Patient is still receiving the same treatment – nivolumab for more than three years, without any major side effects. The latest PET/CT evaluation showed no pathological uptake and reduction in size of the metastases.

**CONCLUSION:** Both the RCC and melanoma are highly immune mediated diseases which could explain the concurrent reactivation and metastatic spread of both diseases as well as positive and lasting therapeutic response to immunotherapy.

## ABSTRACTS

## Clinical Medicine


**CM01 Efficacy of oral formulation of semaglutide in obese patients with type 2 diabetes mellitus - a retrospective study**

Matea Živko<sup>a</sup>, Laura Vidović<sup>a</sup>, Vedrana Verić<sup>a</sup>, Tomislav Božek<sup>a,b</sup>

<sup>a</sup> School of Medicine, University of Zagreb, Zagreb, Croatia

<sup>b</sup> Vuk Vrhovac University Clinic for Diabetes, Endocrinology and Metabolic Diseases, Merkur University Hospital

DOI: <https://doi.org/10.26800/LV-145-supl2-CM01>

 Matea Živko 0000-0001-5033-3506, Laura Vidović 0000-0003-4168-0973, Vedrana Verić 0000-0002-2595-8464, Tomislav Božek 0000-0001-5646-6203

Keywords: HbA1c; obesity; semaglutide; type 2 diabetes mellitus

**INTRODUCTION/OBJECTIVES:** Semaglutide is a glucagon-like-peptide-1 receptor agonist, an innovative drug for managing type 2 diabetes mellitus and obesity. The oral formulation of semaglutide represents an alternative treatment option in patients that decline the subcutaneous injection form. **MATERIALS AND METHODS:** In this retrospective study, 28 diabetic patients (18 male, 10 female) were prescribed the oral formulation of semaglutide as an add-on to their established antidiabetic prescription. At baseline, patients were 62,3 ± 10,2 years old, obese with BMI 32,9 ± 3,5 kg/m<sup>2</sup>, had a body weight of 98,4 ± 15,5 kg, HbA1c 8,3 ± 1,3 %, and with the disease duration of 13,3 ± 9,1 years.

**RESULTS:** At 8 month follow-up, 23 patients completed the treatment - 18 patients (73,9%) lost weight and 19 patients (82,6%) had a reduction in HbA1c. The patients lost 6,1 ± 2,8 kg of body weight and had a reduction in HbA1c by 1,6 ± 1,3 %. 13 patients (56,5%) achieved HbA1c < 7%. 5 patients (17,8%) discontinued the drug after the first 2 weeks of use because of the adverse gastrointestinal symptoms (nausea, vomiting, diarrhea).

**CONCLUSION:** More than half of the patients achieved HbA1c < 7%, alongside losing weight, which proves that oral formulation of semaglutide is beneficial for obese patients with moderately longstanding type 2 diabetes mellitus. Gastrointestinal side effects should be taken into consideration, as around 1/5 of patients did not manage to use the oral formulation of semaglutide at all.

**CM02 Intraoperative floppy iris syndrome: comparison of two different alpha-adrenergic blockers**

Jurica Putrić Posavec<sup>a</sup>, Sanja Masnec<sup>b</sup>, Miro Kalauz<sup>b</sup>, Matija Kalauz<sup>c</sup>, Matea Severin<sup>d</sup>


<sup>a</sup> Department of Emergency medicine, Krapina-Zagorje County, Croatia

<sup>b</sup> Department of Ophthalmology, University Hospital Center Zagreb, Zagreb, Croatia

<sup>c</sup> School of Medicine, University of Zagreb, Zagreb, Croatia

<sup>d</sup> Health Center Zagreb - Center, Zagreb, Croatia

DOI: <https://doi.org/10.26800/LV-145-supl2-CM02>

 Jurica Putrić Posavec 0000-0003-1667-802X, Sanja Masnec 0000-0003-1472-0511, Miro Kalauz 0000-0001-7616-9871, Matija Kalauz 0009-0002-1680-2000, Matea Severin 0000-0002-4851-679X

KEYWORDS: doxazosin; intraoperative floppy iris syndrome; prophylaxis; tamsulosin

**INTRODUCTION/OBJECTIVES:** AIM: To compare the incidence and severity of intraoperative floppy iris syndrome (IFIS) in patients taking tamsulosin or doxazosin.

**MATERIALS AND METHODS:** Prospective study included 1892 patients on systemic tamsulosin or doxazosin therapy over a 2 years period (November 2013- November 2015). Phacoemulsification with intraocular lens implantation was performed, by the same surgeon, without using phenylephrine or epinephrine. The presence of IFIS was evaluated and graded. Grading was performed as follows: 1: none or presence of iris fluttering only; 2: iris fluttering with pupil constriction ≥ 2 mm or iris prolapse; 3: iris fluttering, pupil constriction ≥ 2 mm and iris prolapse. For statistical analysis chi square test was used.

**RESULTS:** Of 1892 patients enrolled, IFIS was noted in 53 patients (2.8%) taking tamsulosin and in 15 patients (0.8%) taking doxazosin. In tamsulosin group, 20.75% of patients had symptoms of mild IFIS, 47.17% moderate and 32.08% severe IFIS. 20% of doxazosin group showed symptoms of mild, 60 % of moderate and 20% of severe IFIS. There was no statistically significant difference between the two groups (X<sup>2</sup>=0,48; P=0,616). Also no significant difference between the groups analyzing moderate + severe IFIS was noted (X<sup>2</sup>=0,96; P=0,327). There were no significant surgical complications in either groups.

**CONCLUSION:** When phenylephrine or epinephrine are omitted intraoperatively as a prophylaxis, moderate to severe IFIS can occur. Although both tamsulosin and doxazosin significantly increase the risk of intraoperative floppy iris syndrome, our data indicate that there is no statistically significant difference between them regarding the severity of iris fluttering, pupil constriction and iris prolapse.

### CM03 Prevalence of hepatitis E antibodies in solid organ and hematopoietic stem cell transplant candidates


Ana-Marija Petani<sup>a</sup>, Vesna Pečevski<sup>a</sup>, Tatjana Vilibić Čavlek<sup>b</sup>, Anna Mrzljaka<sup>a,c</sup>

<sup>a</sup> School of Medicine, University of Zagreb, Zagreb, Croatia

<sup>b</sup> Division for virological serology, Croatian Institute of Public Health, Zagreb, Croatia

<sup>c</sup> Division for gastroenterology and hepatology, University Hospital Centre Zagreb, Zagreb, Croatia

DOI: <https://doi.org/10.26800/LV-145-supl2-CM03>

 Ana-Marija Petani 0000-0001-9421-4867, Vesna Pečevski 0000-0001-6624-9093, Tatjana Vilibić Čavlek 0000-0002-1877-5547, Anna Mrzljak 0000-0001-6270-2305

**KEYWORDS:** Hepatitis E virus; seroprevalence; transplant recipients

**INTRODUCTION/OBJECTIVES:** Hepatitis E virus (HEV) is a single-stranded positive-sense RNA virus that belongs to the *Hepeviridae* family, genus *Orthohepevirus*. Of eight HEV genotypes (1-8) identified, the first four cause diseases in humans. In Croatia, the HEV seroprevalence differs widely depending on the geographical region and population group studied.

**MATERIALS AND METHODS:** This study aimed to analyze the seroprevalence of HEV in solid organ and hematopoietic stem cell transplant candidates. The study included 178 patients aged 19-75 years, of which 91 were liver transplant candidates (LCT), 47 were kidney transplant candidates (KCT) and 40 were hematopoietic stem cell transplant (HSCT) candidates. HEV IgG antibodies were detected in serum samples using a commercial enzyme immunoassay (ELISA; Euroimmun, Lübeck, Germany).

**RESULTS:** In the tested group there were 124/69.7% of men and 54/30.3% of women. HEV IgG seroprevalence differed significantly ( $p=0.009$ ) among population groups. The highest seropositivity was observed in LCT (16/17.5%) compared to 2/4.3% in KTC and 1/2.5% in HSCT candidates. Although males showed a higher seroprevalence (15/12.1%, 95%CI=6.9-19.2) compared to females (4/7.4%, 95%CI=2.1-17.8), this difference was not statistically significant ( $p=0.351$ ). In addition, there was no difference in the median age of HEV IgG seropositive (61.5 years, IQR=39.5-66.5) and seronegative (median 59 years, IQR=52-65) patients.

**CONCLUSION:** In conclusion, this study showed a significant number of LCT have HEV antibodies compared to KCT and HSCT candidates. However, due to the small number of participants, further studies are needed to determine the true seroprevalence and risk factors for hepatitis E in this population group.

### CM04 Travel-related imported dengue infections in Croatia


Vesna Pečevski<sup>a</sup>, Ana-Marija Petani<sup>a</sup>, Vladimir Savić<sup>b</sup>, Tatjana Vilibić Čavlek<sup>c</sup>

<sup>a</sup> School of Medicine, University of Zagreb, Zagreb, Croatia

<sup>b</sup> Croatian Veterinary Institute, Zagreb, Croatia

<sup>c</sup> Croatian Institute of Public Health, Zagreb, Croatia

DOI: <https://doi.org/10.26800/LV-145-supl2-CM04>

 Vesna Pečevski 0000-0001-6624-9093, Ana-Marija Petani 0000-0001-9421-4867, Vladimir Savić 0000-0003-0398-5346, Tatjana Vilibić Čavlek 0000-0002-1877-5547

**KEYWORDS:** Croatia; dengue virus; travel; epidemiology

**INTRODUCTION/OBJECTIVES:** Dengue virus (DENV) is an emerging flavivirus that causes dengue fever, a mosquito-borne viral disease that is common in tropical and subtropical regions of the world. There are four DENV serotypes (DENV1-4). The virus is transmitted to humans through the bite of infected *Aedes* mosquitoes (*Ae. aegypti* and *Ae. albopictus*). Symptoms of dengue include fever, headache, joint and muscle pain, and rash. The aim of this study was to analyze the prevalence of dengue fever in febrile travelers returning from endemic areas.

**MATERIALS AND METHODS:** DENV IgM and IgG antibodies were detected using a commercial ELISA (Euroimmun, Lübeck, Germany), while DENV RNA was detected using an RT-PCR. One DENV strain was Sanger sequenced. **RESULTS:** A total of 56 patients (31/55.4% males) tested from 2016 to 2022 were included. In addition to fever, reported in all patients (56/100%), the clinical symptoms were: headache (10/17.9%), myalgia (19/33.9%), arthralgia (22/39.3%), and rash (15/26.8%). Areas of potential exposure were Central or South America (23/41.1%), Asia (22/39.3%), and Africa (11/19.6%). Acute dengue fever was detected in 12 (21.4%) patients. In 11 patients, DENV infection was confirmed serologically, while DENV RNA was detected in a blood sample in one patient. Phylogenetic analysis of the detected strain confirmed the presence of DENV1. In addition, 6 patients (10.7%) showed previous exposure to DENV (IgG antibodies). Areas of importation/number of patients were: Maldives/1, Somalia/1, Tanzania/1, Sri Lanka/1, South Africa/1, Central America/2, India/2, Indonesia/2, Philippines/2, Cuba/2, and Thailand/3. **CONCLUSION:** Since *Ae. albopictus* is present in Croatia, vector control measures, dengue surveillance, and health education should be performed continuously.




## CM05 Correlating prostate imaging reporting and data system (PIRADS) version 2 scores with results of targeted biopsy of the prostate

Domagoj Šarić<sup>a</sup>, Tomislav Kuliš<sup>a,b</sup>, Zoran Zimak<sup>b</sup>, Bojan Čikić<sup>b</sup>, Toni Zekulić<sup>b</sup>, Željko Kaštelan<sup>a,b</sup>

<sup>a</sup> School of Medicine, University of Zagreb, Zagreb, Croatia

<sup>b</sup> Department of Urology, University Hospital Centre Zagreb, Zagreb, Croatia

DOI: <https://doi.org/10.26800/LV-145-supl2-CM05>

 Domagoj Šarić 0000-0001-6309-0419, Tomislav Kuliš 0000-0002-0895-5691, Zoran Zimak 0000-0002-3776-8203, Bojan Čikić 0000-0002-4605-5184, Toni Zekulić 0000-0002-3498-0217, Željko Kaštelan 0000-0002-9262-3234

KEYWORDS: biopsy; mpMRI; prostate cancer

**INTRODUCTION/OBJECTIVES:** Targeted prostate biopsy using multiparametric magnetic resonance imaging (mpMRI) has become a valuable addition to the standard systematic transrectal ultrasonography biopsy. Suspicious lesions on mpMRI are graded using the PIRADS scoring system. In our institution, patients with PIRADS 3-5 undergo a targeted biopsy in addition to the systematic 12-core biopsy. This study aims to provide data on the correlation between PIRADS score and clinically significant prostate cancer (csPCa), i.e. cancers with a Gleason score of 3+4 or higher.

**MATERIALS AND METHODS:** This is a retrospective study of patients with PIRADS 3-5 who underwent a targeted+systematic prostate biopsy in our institution between 2018 and 2022.

**RESULTS:** A total of 743 patients underwent a targeted biopsy in this time period. There were 394 (53.1%) positive biopsies, 66.4% of which were diagnosed with csPCa. Of 340 PIRADS 3 lesions, 35.6% were positive, 45.1% of which were csPCa. Of 257 PIRADS 4 lesions 61.1% were positive, and 72.6% were csPCa. Of 133 PIRADS 5 lesions 85% were positive, 80.5% of which were csPCa. In the PIRADS 5 category there were only 1.8% negative targeted biopsies in patients with positive systematic biopsy while 13.3% had positive targeted cores with negative systematic biopsy.

**CONCLUSION:** This study demonstrates that the diagnosis of csPCa increases with higher PIRADS scores. More data on the correlation between csPCa and mpMRI findings may reduce both the overdiagnosis of clinically insignificant prostate cancer and the risks of performing unnecessary prostate biopsies.

## CM06 Dry eye disease and phacoemulsification cataract surgery


Mia Edl<sup>a</sup>, Suzana Matic<sup>a,b,c</sup>, Lucija Matic<sup>b</sup>, Lucija Čolaković<sup>a</sup>, Bruno Bumčić<sup>a</sup>

<sup>a</sup> Faculty of Medicine, Josip Juraj Strossmayer University of Osijek, Osijek, Croatia

<sup>b</sup> Faculty of Dental Medicine And Health, Josip Juraj Strossmayer University of Osijek, Osijek, Croatia

<sup>c</sup> Department of Ophthalmology, Osijek University Hospital Centre, Osijek, Croatia

DOI: <https://doi.org/10.26800/LV-145-supl2-CM06>

 Mia Edl 0000-0002-7818-5741, Suzana Matic 0000-0002-8040-2784, Lucija Matic 0009-0004-3354-2700, Lucija Čolaković 0000-0002-0212-3843, Bruno Bumčić 0009-0004-8981-1113

KEYWORDS: cataract; dry eye disease; phacoemulsification; visual acuity

**INTRODUCTION:** Dry eye disease (DED) is a multifactorial disease of the ocular surface with contributing factors including tear film instability, hyperosmolarity, and inflammation. Cataract surgery can impact visual acuity recovery by contributing to and prolonging corneal restitution. This prospective cohort study aims to investigate the best corrected visual acuity (BCVA) after phacoemulsification cataract surgery (PHACO) in patients with DED.

**MATERIALS AND METHODS:** 60 patients with cataracts were divided into two groups; the first group of 29 patients had healthy corneal surfaces, while the other (31 patients) had DED, and all underwent PHACO surgery. Before and 30 days after surgery, all patients underwent ophthalmic examination including corneal fluorescein staining (fl), tear film break-up time test (TBUT), and the BCVA assessment. DED was defined with a positive fl test and TBUT < 5 mm. All patients had PHACO surgery with intraocular lens implantation performed by the same surgeon using the Infinity (Alcon 2008 device).

**RESULTS:** The mean age of patients was 76 ± 7. Most of the patients were females (52%) versus males (48%), with no statistically significant difference between gender. There was a statistically significant improvement (Wilcoxon test, p < 0,001) in BCVA after surgery in both groups. TBUT tests before and after surgery were significantly higher in the control group than in the DED group. There were significantly more positive results of the fl test after surgery in both groups (Wilcoxon test P < 0,001).

**CONCLUSION:** DED influences corneal tear film tests after uncomplicated phacoemulsification cataract surgery, but doesn't significantly impact postoperative BCVA.

### CM07 Effectiveness of bare sclera technique versus conjunctival autograft transplantation for pterygium treatment

Nina Krobot Čutura<sup>a</sup>, Goran Tomičić<sup>a</sup>

<sup>a</sup> Department of Ophthalmology and Optometry, Varaždin General Hospital, Varaždin, Croatia

DOI: <https://doi.org/10.26800/LV-145-sup12-CM07>

 Nina Krobot Čutura 0009-0005-7167-5886, Goran Tomičić 0009-0001-2682-8485

**KEYWORDS:** conjunctiva\*/transplantation; pterygium\*/surgery; treatment outcome

**INTRODUCTION/OBJECTIVES:** Pterygium is a common ocular surface disease encountered in everyday ophthalmology practice. It represents an abnormal fibrovascular growth of conjunctiva that can affect the cornea and cause a significant visual impairment such as irregular astigmatism and blurred vision. In case of disease progression, surgical treatment is required. Due to the high recurrence rate, various surgical techniques are used with different success rates. The aim of this study is to compare effectiveness of bare sclera technique and conjunctival autograft transplantation for pterygium treatment.

**MATERIALS AND METHODS:** Medical records of 53 patients with primary and recurrent pterygia were analysed retrospectively. This study included patients that underwent pterygium surgery between September 2021 and April 2022 in Varaždin General Hospital using bare sclera technique (n= 24) and conjunctival autograft transplantation (n=29). Recurrence rates at the follow-up examination 6 months after surgery were compared using chi-square test.

**RESULTS:** The mean±SD age of the patients was 63.66±10.56. The recurrence rate of pterygium 6 months after surgery with bare sclera technique was 37.5% (n=9), while the recurrence rate in conjunctival autograft transplantation was 10.34% (n=3). A statistically significant difference in recurrence rates between groups was found (chi-square: 5.529, p=0.02).

**CONCLUSION:** Pterygium treatment using conjunctival autografting results in a lower rate of pterygium recurrence compared to the bare sclera technique 6 months after surgery. Due to a high recurrence rate, bare sclera technique should be avoided when possible.


### CM08 Higher occurrence of chronic kidney disease in JAK2 V617F mutated MPN patients with higher mutant allele burden

Petra Veić<sup>a</sup>, Ena Sorić<sup>b</sup>, Marko Lucijanić<sup>a,b</sup>, Rajko Kušec<sup>a,b</sup>

<sup>a</sup> School of Medicine, University of Zagreb, Zagreb, Croatia

<sup>b</sup> Division of Hematology, Department of Internal Medicine, University Hospital Dubrava Zagreb, Croatia

DOI: <https://doi.org/10.26800/LV-145-sup12-CM08>

 Petra Veić 0009-0000-7183-0632, Ena Sorić 0009-0007-98310-1905, Marko Lucijanić 0000-0002-1372-2040, Rajko Kušec 0000-0002-2131-3861

**KEYWORDS:** Chronic renal insufficiency; JAK-2 Protein Tyrosine Kinase; Myeloproliferative Disorders

**INTRODUCTION/OBJECTIVES:** Patients with chronic myeloproliferative neoplasms (MPN) often have a chronic kidney disease (CKD) at the time of diagnosis. Two diseases may be causally related as pathohistological studies suggest existence of MPN-related glomerulopathy.

The aim of this study was to examine the correlation between renal function and JAK2-mutation allele burden in MPN patients.

**MATERIALS AND METHODS:** In this retrospective analysis, MPN patients with quantification of JAK2-mutation allele burden, treated in University Hospital Dubrava from January 2006 till December 2022 were included. Quantification of the JAK2-mutant allele burden was performed using 7300 RealTime PCR System. Clinical and laboratory data were analysed at the time of the diagnosis and after six months. Creatinine clearance rate was estimated using CKD-EPI formula.

**RESULTS:** 230 MPN patients were enrolled: 98 polycythaemia vera, 94 essential thrombocythemia, 20 primary myelofibrosis, 18 MPN not classified. Median age was 67 years, 50.2% of patients were female. At the time of the diagnosis 24.9% of patients had CKD. MPN patients with higher mutant allele burden stratified at median value (>26.3%) had higher occurrence of CKD at baseline (32.6% vs 16.7%, P=0.012). Also, dynamics of kidney function significantly differed regarding baseline allele burden with mean 2% worsening and 7% improvement in serum creatinine levels in patients with higher vs lower baseline mutant allele burden, respectively, P=0.032.

**CONCLUSION:** JAK2 V617F mutated MPN patients with higher mutant allele burden may have higher occurrence of CKD and unfavorable dynamics of kidney function over time.


### CM09 Patient-Oriented Severity Index (MD POSI) as Quality of Life (QoL) Assessment Tool for Patients with Menier's disease

Stela Marković<sup>a</sup>, Jelena Bošnjak<sup>a</sup>, Andro Košec<sup>b</sup>

<sup>a</sup> School of Medicine, University of Zagreb, Zagreb, Croatia

<sup>b</sup> Department of Otorhinolaryngology, Sestre milosrdnice University Hospital Centre, Zagreb, Croatia

DOI: <https://doi.org/10.26800/LV-145-supl2-CM09>

 Stela Marković 0000-0003-2149-2422, Jelena Bošnjak 0000-0002-9598-8642, Andro Košec 0000-0001-7864-2060

**KEYWORDS:** Meniere Disease; sensorineural hearing loss; Quality of Life

**INTRODUCTION/OBJECTIVES:** Vertigo, tinnitus, and hearing loss cause physical and emotional challenges, affecting daily activities and even causing social isolation.

**MATERIALS AND METHODS:** This retrospective study, conducted from 2014-2020 at University Hospital Centre Sisters of Mercy Zagreb, aimed to investigate the impact of Meniere's disease QoL using MD POSI questionnaire.

**RESULTS:** The study included 60 patients (24 men and 36 women, mean age 58.05). The average MD POSI score for the entire group was 29 (range 0-80). Based on audiogram results, the group was divided into three categories: good hearing, hard of hearing, and deaf. To compare total MD POSI scores and hearing, one-way ANOVA with post-hoc Bonferroni test was used. The test revealed a significant difference ( $p=0.008$ ) between normal hearing and hearing loss groups. Chi-squared test with Yates' correction was performed to determine the relationship between balance problems between attacks and the ability to perform daily activities ( $p<0.001$ ). Additionally, the correlation between overall mood and the ability to perform daily activities between attacks was also significant ( $p=0.014$ ). The study found a significant association between the presence vertigo during attacks and poor QoL score ( $p<0.001$ ) and hearing loss ( $p<0.001$ ). This association was also present for vertigo between attacks, although to a lesser degree ( $p=0.005$ ,  $p=0.079$ , independent-samples t-test). Additionally, the total score on the questionnaire was found to significantly correlate with the impact on social life and overall mood.


**CONCLUSION:** We have demonstrated vertigo the most significant detrimental factor for the QoL in this cohort of patients with Meniere's disease.

### CM10 What makes women in Croatia satisfied with childbirth?

Klara Miljanić<sup>a</sup>, Iva Tkalčec<sup>a</sup>, Stela Majetić<sup>a</sup>, Aida Mujkić<sup>a</sup>

<sup>a</sup> School of Medicine, University of Zagreb, Zagreb, Croatia

DOI: <https://doi.org/10.26800/LV-145-supl2-CM10>

 Klara Miljanić 0000-0002-5049-6783, Iva Tkalčec 0009-0005-5690-5030, Stela Majetić 0000-0003-2296-6853, Aida Mujkić 0000-0002-1795-8229

**KEYWORDS:** Childbirth; Healthcare Quality Assurance; Pregnancy

**INTRODUCTION/OBJECTIVES:** There is a growing body of evidence on the importance of the "first 1,000 days" of early child development. Birth as a turning point within that time is increasingly recognized in all its complexity and far-reaching influence. This study aimed to explore and collect information about what women who gave birth in Croatia consider an important positive aspect of care during and after childbirth and emphasize the importance of patient-centered healthcare.

**MATERIALS AND METHODS:** This research was conducted as part of the international project COST EU Birth Research Project - Babies Born Better. Data was obtained using an internationally validated questionnaire, accessible online from March until August 2018. The collected data was later analyzed.

**RESULTS:** The study involved 619 women who had given birth in Croatia five years before participating in the BBB survey. As a positive experience related to childbirth, 257 (22.8%) respondents mentioned the friendliness and attitude of medical staff toward the mother, while 106 (9.4%) mentioned their general quality and expertise. When asked what they would change regarding childbirth, 139 (15.8%) respondents listed a lack of information during childbirth and respect for the mother's needs and right to make decisions, while 97 (11%) mentioned material conditions in the hospital, and 89 (10.1%) emphasized kindness and attitude toward the mother.

**CONCLUSION:** This study confirmed that the overall attitude of the medical staff toward the mother is the most crucial factor in their subjective evaluation of the birth experience.



## ABSTRACTS

## Literature review

**CM11 Original research - COVID 19 pandemic impact on newly discovered cancer in family medicine practice: a five-year comparison**Eva Pleško<sup>a</sup>, Mladen Pospišil<sup>a</sup>, Marina Nađ<sup>b</sup><sup>a</sup> Krapina-Zagorje County Community Health Center, Gornja Stubica, Croatia<sup>b</sup> School of Medicine, University of Zagreb, Zagreb, CroatiaDOI: <https://doi.org/10.26800/LV-145-supl2-CM11> Eva Pleško 0000-0003-2925-359, Mladen Pospišil 0000-0002-9462-2593, Marina Nađ 0000-0003-1356-7551

KEYWORDS: cancer; COVID-19; neoplasm


**INTRODUCTION:** The COVID 19 pandemic has significantly changed our lives. Fear of virus infection during 2020 caused the postponement of numerous examinations and diagnostic procedures.

**AIM:** The aim of the research is to show the change in the number of newly discovered cancers in two family medicine offices (FMO) during the years 2018-2022.

**MATERIALS AND METHODS:** This research was conducted in two FMOs of the County Community Health Center of the Krapina-Zagorje in the municipality of Gornja Stubica, which have (2234) persons of a similar age structure in their care. Data on the total number of newly opened cases under diagnosis of C-neoplasm (MKB classification) were collected and analyzed through the IN-CON system. Differences between the number of newly discovered cases are expressed as absolute values and their percentage change between years.

**RESULTS:** During 2018- 2019, no significant differences were found in the number of patients with newly discovered cancers (19 vs. 21), while in 2020, only 10 cancers were newly discovered, which is 52.38% less than in 2019. An increase in the number of newly discovered cancers was recorded in 2021, when 18 newly discovered cancers were recorded, and in 2022, when 18 newly discovered cancers were also recorded. At that time, the number of diagnosed cancer patients reached 85.7% compared to 2019.

**CONCLUSION:** During 2020, a significant decrease in the number of newly discovered cancers was recorded. With the easing of epidemiological measures, these values stabilized in 2021 and 2022 and almost reached the values from 2019.

**LR01 HIV and depression**Mirta Peček<sup>a</sup>, Ante Orbanic<sup>b</sup>, Lea Tomašić<sup>c</sup><sup>a</sup> School of Medicine, University of Zagreb, Zagreb, Croatia<sup>b</sup> City Pharmacy Zagreb, Zagreb, Croatia<sup>c</sup> University Psychiatric Hospital Vrapče, Zagreb, CroatiaDOI: <https://doi.org/10.26800/LV-145-supl2-LR01> Mirta Peček 0000-0003-4350-4025, Ante Orbanic 0000-0003-4333-1646, Lea Tomašić 0000-0001-7546-5361

KEYWORDS: depressive disorders; HIV; suicide

**INTRODUCTION/OBJECTIVES:** The most prevalent neuropsychiatric comorbidity of the human immunodeficiency virus (HIV) is a major depressive disorder. The rate of depression among people living with HIV (PLHIV) is three times higher than in the general population and is associated with lower quality of life, additional somatic comorbidities, reduced medication adherence, worse disease progression, and a higher risk of transmission to others. This review aims to raise awareness of depression and its consequences among PLHIV.

**MATERIALS AND METHODS:** The PubMed database was searched using the keywords: HIV and depression. 8325 papers were found.

**RESULTS:** Prevalence rates of depression in PLHIV range from 0 to 80%. The increased incidence of depression among PLHIV is a result of dysfunction in immunometabolism, inflammation, and neurotransmitter cascades. Female gender, older age, food insecurity, exposure to abuse, and internalized stigma are risk factors for depression, while disclosure of HIV status, satisfaction with relationships, and social support are protective. Women with HIV exhibit a significantly higher risk of antenatal (36% vs 26%) and postnatal (21% vs 16%) depressive symptoms compared with controls. PLHIV suffering from depression were found to have high suicidal ideation (22,3%), attempted suicide (9,6%), and deaths by suicide (1,7%).

**CONCLUSION:** Depressive disorders deserve more attention from HIV healthcare providers for improved detection and overall proper management. The findings indicate the need for targeted interventions specific to PLHIV that address the psychological challenges, stigma, and discrimination these people and their families face, which would ultimately lead to reducing psychological consequences and improving the quality of life in PLHIV.

## ABSTRACTS

## Other

**001 How to have perfect skin and an even better workshop – our experience with organizing a cricothyrotomy workshop**


Josip Kajan<sup>a</sup>, Jelena Pokos<sup>a</sup>, Nenad Nešković<sup>b</sup>, Josip Grbavac<sup>c</sup>, Slavica Kvolik<sup>b</sup>

<sup>a</sup> Faculty of Medicine, Josip Juraj Strossmayer University of Osijek, Osijek, Croatia

<sup>b</sup> Department of Anesthesiology, Clinical Hospital Osijek, Osijek, Croatia

<sup>c</sup> Centre for Emergency Medicine, Osijek-Baranja County, Osijek, Croatia

DOI: <https://doi.org/10.26800/LV-145-supl2-O01>

 Josip Kajan 0000-0002-4844-3260, Jelena Pokos 0009-0002-2375-0368, Nenad Nešković 0000-0003-1160-163X, Josip Grbavac 0009-0006-1129-6080, Slavica Kvolik 0000-0002-5244-9585

**KEYWORDS:** Clinical Competence; Education; Laryngeal Cartilages; Skin

**AIM:** Our goal of this paper is to describe our derivative of cricothyrotomy model and the whole impact of the workshop on the attendees.

**MATERIALS AND METHODS:** The skin is made from gelatin, water and glycerol mixture (mixed in a 1:3:3,5 ratio), food color, and gauze. Subcutaneous tissue was made the same only without gauze. Cricothyrotomy model consist of 3D printed model of laryngeal cartilage, duct tape, and aforementioned subcutaneous tissue and skin simulation. We also used all the necessary items for performing an emergency cricothyrotomy. The educational part of the workshop was based on George and Doto's five-step method for teaching clinical skills. At the beginning and end the workshop attendees were asked to complete an exam and a survey regarding their experience with the workshop.

**RESULTS:** Workshop had 18 attendees, all of whom completed the exams and surveys. The average score on the pre-workshop exam was 4,28 (on a scale from 1 to 7) and 6,22 on the post-workshop exam. In the surveys, the attendees gave the workshop quality an average rating of 4,94, while the average rating for the educational value was 4,83. The lectures had an average rating of 4,89 and the hands-on practice session was rated with an average score of 4,89 (all ratings are on a scale from 1 to 5, with 5 being the best possible rating).

**CONCLUSION:** This kind of model used in hands-on practice and whole workshop was favorable by attendees, who displayed a statistically significant improvement in knowledge about cricothyrotomy by the end of the workshop.

**002 Anticipating Moral Injury In Medical Students**


Laura Ivanović Martić<sup>a</sup>, Borna Katić<sup>b</sup>, Lada Zibar<sup>a,c</sup>

<sup>a</sup> Faculty of Medicine, Josip Juraj Strossmayer University of Osijek, Osijek, Croatia

<sup>b</sup> School of Medicine, University of Zagreb, Zagreb, Croatia

<sup>c</sup> Clinical Hospital Merkur, Zagreb, Croatia

DOI: <https://doi.org/10.26800/LV-145-supl2-O02>

 Laura Ivanović Martić 0000-0002-4946-0310, Borna Katić 0009-0002-6159-8395, Lada Zibar 0000-0002-5454-2353

**KEYWORDS:** Ethics; Stress Disorders; Students

**INTRODUCTION:** Moral injury is an emotional and psychological distress caused by disbalance between the situation a person finds itself in and personal beliefs. Characteristics are feeling of guilt and shame, loss of trust and confidence, as well as anxiety and depression symptoms. The main research goal was to anticipate the risk of moral injury among medical students in future situations.

**MATERIALS AND METHODS:** The cross-sectional study was conducted by an online questionnaire, consisting of sociodemographic questions and 10 possible situations they could encounter in their future work. It was questioned if these situations bothered them considering their personal beliefs.

**RESULTS:** 376 students (28.2 % males, 75.8 % religious) of medical schools in Croatia, Serbia and Bosnia and Herzegovina participated in the research. In 6 out of 10 situations, more than 80 % of the participants would feel like the situation bothered them morally, while in another 4 more than 50 % felt the same. The most immoral trigger was when a colleague won a competition for specialization unfairly (92.6 %), while only 52.4 % of students felt morally injured if they witnessed inappropriate research conduct. Being religious was accompanied by higher risk of moral injury.

**CONCLUSION:** Results showed that most of the participants were at risk of developing moral injury. Some immoral situations did not cause appropriate perception. Efforts should be made to reduce the situations that render such injury. Nevertheless, medical students should be taught about ethical principles, thus they would better recognize situations that are not ethically acceptable.

## ABSTRACTS

# Workshop Invitations

## Every breath you(r patient) take(s)

A stands for??? Awesome?!? Yes, this workshop will be awesome, but it stands for airway. Every breath your patient takes, every chest movement he makes, every silence he breaks, every effort he takes you'll be watching it and we will teach you how to preserve it. Ever heard of VL, fiber or cric? They are not just fancy slang words, but things that can save a life! The best part? You can learn everything about them and try them on models, completely free of charge! You may become breathless while witnessing the amazing spectrum of airway management modalities, but your patients won't be ever again!!!



*Student Society of Anesthesiology, Resuscitation and Critical Care, School of Medicine, University of Zagreb*  
*Student Society of Anesthesiology, Resuscitation and Critical Care, Faculty of Medicine Osijek, Josip Juraj Strossmayer University of Osijek*

### AUTHORS

Đidi Delalić, Josip Kajan

Professor Ingrid Prkačin, M.D., PhD

## Resus for Rookies

Sick and tired of sitting through lectures on resuscitation without actually having the chance to practice? Want hands-on training, simulated clinical scenarios and guidance by some of the coolest resus instructors around? Have we got an offer for you! Make your CROSS 18 registration worthwhile and learn how to save someone's life, regardless of whether you plan on being an outpatient Emergency medical services physician, a hospital resident or a primary care physician. Turn the afternoon siesta into a FIESTA and join us for a bunch of resus goodness!



*Student Society of Anesthesiology, Resuscitation and Critical Care, School of Medicine, University of Zagreb*

### AUTHORS

Delalić Đidi, Isaković Adnan, Kuzmić Romana, Palijan David, Zvekić Luka, Šušak Frano, Grzelja Mihael

Professor Ingrid Prkačin, M.D., PhD

## From cortex to coiling - an integrative approach

Do you want to experience working in a lab on brain tissue? Do you think that science is your calling? But then again, clinical path in life is also appealing? Maybe something more hands-on? Come join us in our workshop where you'll first experience sample preparation and results analysis but then after you'll get to try out the skills of an interventional neuroradiologist.



*Student Society for Neuroscience, School of Medicine, University of Zagreb*

### AUTHORS

Ana Adžić, Melita Klaić, Pavel Marković, Mario Zelić

Associate Professor Goran Sedmak, M.D., PhD, Associate Professor Željka Krsnik, M.D., PhD, Alisa Junaković, M.D., Janja Kopic, M.Sc.



## Parkinson's, potentials and pretty lights

How do we control our movements and what happens in Parkinson's disease? In this interactive workshop, we'll try to visualize this with the use of little blinking neuron simulators. Can we stimulate our neurons to work better when we get sick? A neurosurgeon will tell us more about deep brain stimulation and what amazing results can be achieved when technology and medicine come together.



*Student Society for  
Neuroscience, School  
of Medicine, University  
of Zagreb*

### AUTHORS

Ana Adžić, Melita Klaić, Pavel Marković, Mario Zelić

Associate Professor Goran Sedmak, M.D., PhD, Assistant Professor Fadi Almahariq, M.D., PhD

## How FAST can you diagnose me?

We invite you to be a part of our e-FAST and ultrasound-guided vascular access workshop. During the workshop, you will learn the basics of using ultrasound as well as how to acquire basic diagnostic images of each component of an e-FAST examination. You will also learn what the basic pathological findings of each diagnostic window are. In addition, you will have the opportunity to learn how to access blood vessels under ultrasound guidance.



*Students' Section for  
Radiology, School of  
Medicine, University of  
Zagreb*

### AUTHORS

Nera Golub, Dinea Bučić, Erin Kos, Bruno Mioč, Anđela Deak

Vjekoslav Štambuk, M.D.

## Far More Than TV Drama: What is Forensic Psychiatry?

Murder? Police investigation? Trials? No, this is not Navy CIS or CSI: Miami with Leroy Gibbs or Horatio Cane as the main characters. Welcome to something better than crime series - the workshop titled „Far More Than TV Drama: What is Forensic Psychiatry?“ Together with the Student Section for Psychiatry and Aleksandar Savić, MD, PhD, you will discover the truth between mental disorders and criminal behavior! Furthermore, we will challenge you to assess the competence of a person who committed a crime to stand trial!



*Student Section for  
Psychiatry, School of  
Medicine, University of  
Zagreb*

### AUTHORS

Eva Podolski, Mara Parentić

Aleksandar Savić, M.D., PhD

## Window to the world: How to diagnose the invisible?

The senses of smell, taste, hearing and ability to speak are extremely important for the quality of life and enjoyment of everyday things. Find out how we examine these sensations invisible to the eye and how to make the right diagnosis.



*Student Society for  
Otorhinolaryngology  
and Head and Neck  
Surgery, School of  
Medicine, University of  
Zagreb*

### AUTHORS

Anna Braniša, Jelena Bošnjak,  
Ozana Jakšić, Stela Marković,  
Rea Novak

Andro Košec, M.D., PhD

## Trauma step by StEPP

Dear colleagues,

We would like to invite you to participate in our Emergency Medicine workshop. You will have an opportunity to see a simulated scenario of a major trauma patient and how would a real emergency team recognize and treat the patient's injuries. We will go over the entire trauma algorithm and put special emphasis on evaluation and extrication of the patient from the vehicle. A car crash is one of the most common and challenging situations an ER team will encounter. Afterwards you will be able to practice and learn the essential skills of an emergency medicine team yourself. As students today, and first line responders tomorrow, now is the time to learn these life saving techniques!



*StEPP, School of  
Medicine, University of  
Zagreb*

### AUTHORS

Fran Naletilić, David Miklenić,  
Dino Salopek, Nika Senjanović,  
Klara Šinka, Matija Valečić

## I (don't) love myself

Why do we tend to be harshest on ourselves when the going gets tough? How can we transform the commonly used "I don't love myself" to "I love myself"? Although neither question can have a definitive answer, this workshop can lead us in the right direction. Join our workshop if you're eager to learn and practice new self-care skills! You'll progressively and gently begin to uncover aspects about yourself that you did not notice beforehand. The workshop is a space where we discover more about ourselves, meet new friends, and acquire new skills to look out for our wellbeing.



*Croatian Medical  
Students' International  
Committee - „Working  
on mental health –  
Inside out“*

### AUTHORS

Matilda Sabljak, Ivan Petrik,  
Marin Cvitić, Stella Sara Worman,  
Lucija Relja, Josipa Vlahović

Katarina Skopljak, M.D.

## ORTHObasics

We kindly invite you to the Orthobasics 1 – lower extremities workshop where you can learn how to clinically examine patients with lower limb pathology with the guidance of our instructors. The clinical examination is composed of patient history, inspection, palpation and clinical tests that help the Orthopedics surgeon set a diagnosis.



*Student Society for  
Orthopaedics and  
Traumatology, School  
of Medicine, University  
of Zagreb*

### AUTHORS

Afan Ališić, David Glavaš  
Weinberger, Martin Čemerin,  
Branimir Bradarić Šluju, Luka  
Šižgorić

Assistant Professor Ivan Boháček,  
M.D., PhD

## Think outside the body

If you are interested in how 3D printing technologies save lives, how spare parts for people are created or you just want to experience what is like to be a cyborg, you are in the right place. Participants will have the opportunity to see the 3D printing process live, try out models for practicing procedures in emergency medicine as well as learn about the process of making bionic prosthetics and try using it.



*Student Society for for  
innovation in medicine,  
School of Medicine,  
University of Zagreb*

### AUTHORS

Lovro Jančić, Konrad Alexander  
Kiss, Luka Zvekić, Tea Pavičić,  
Nikola Klikić

Professor Vedran Katavić, M.D.,  
PhD

## Knot Your Average Workshop -Master your Surgical Knotting skills

Join our surgical knotting workshop and learn the art of precision and finesse! Perfect your technique and master the skills required for successful surgeries. Our experienced instructors will guide you through every step, ensuring you leave with the confidence to tie some complex knots with ease. Don't miss this opportunity!



*Student Surgical  
Society, School of  
Medicine, University of  
Zagreb*

### AUTHORS

Borna Vojvodić, Antonio Pudić,  
Dominik Vicković, Tea Rosandić,  
Lorena Stamičar, Filip Hrestak,  
Dea Maras

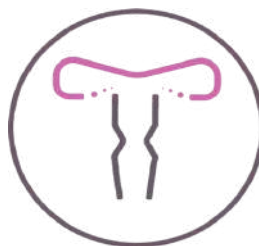
Assistant Professor Igor Rudež,  
M.D., PhD, Assistant Professor  
Hrvoje Silovski, M.D., PhD,  
Associate Professor Ivan Dobrić,  
M.D., PhD



## Preach the breech

Dear participants,

In our workshop we will try to dispel the myth that breech presentation is always hazardous. After this workshop, you will be less afraid of attending the breech birth and more confident in intervening when necessary. Come and re-learn traditional concepts of obstetrics which are nowadays unfortunately falling into oblivion. Let's reestablish vaginal breech birth together, as a viable option for low-risk mothers!



*Student society for  
gynecology and  
obstetrics, School of  
Medicine, University of  
Zagreb*

### AUTHORS

Krunoslav Budimir, Eva Podolski

Assistant Professor Josip Juras,  
M.D., PhD

## Meet the Zebras

Throughout the workshop students will be able to experience the work of the Student's Line for Rare Disease first-hand through presentation of real-life cases Line's volunteers received from members of the Croatian Alliance for Rare Diseases. Students will learn the importance of understanding rare diseases and how to effectively gather reliable information about rare diagnoses that are commonly the cause of confusion in the minds of students and soon-to-be young doctors due to oftentimes sparse sources. Through a series of case presentations, we will assume the role of detectives who must respond to a patient with a specific problem or an unknown diagnosis within a given time frame. All literature is available, but will you be able to solve the case in time? After all, we're talking about a rare disease so when you hear hoofbeats *think zebras, not horses!*



*Student's Line for Rare  
Diseases, School of  
Medicine, University of  
Zagreb*

### AUTHORS

Manuela Bajan, Jelena Benčić,  
Dorotea Kozić, Veronika Lendvaj,  
Tin Rosan, Anamaria Yago

Danijela Petković - Ramadža,  
M.D., PhD

## How do I (ultra)sound?

Dear CROSS 18 attendees,  
we are happy to introduce you to our ultrasound workshop - "How do I (ultra)sound?" If you are looking to improve your diagnostic skills and enhance your knowledge of ultrasound imaging, this workshop is the right place for you! Come and learn about the ultrasound of the abdomen in this interactive workshop, under the guidance of experts in this valuable skill.



*Student Section for  
Gastroenterology and  
Hepatology, School of  
Medicine, University of  
Zagreb*

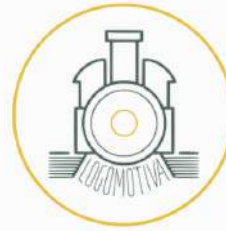### AUTHORS

Jakov Markić

Nina Blažević, M.D., Associate  
Professor Anna Mrzljak, M.D.,  
PhD

## Breaking the Silence

On behalf of the Croatian Student Summit (CROSS) 18, we would like to invite you to our interactive workshop. It arose from the desire of students of speech and language pathology to spread awareness about the problems and the growing prevalence of hearing impairment and to educate students of other faculties on ways to communicate with patients with hearing impairment. The workshop interactively dispels students' most common myths about the population of people with hearing impairments, brings them closer to possible situations in which they may find themselves in practical work, and clarifies communication guidelines tailored to their professions. It is intended for all those who want to know more about this specific population and ways of communicating with its members. We are looking forward to sharing our own and hearing about other people's experiences on this interesting subject.



*Association of  
Students of Speech and  
Language Pathology  
– Logomotiva,  
Faculty of Education  
and Rehabilitation  
Sciences, University of  
Zagreb*

### AUTHORS

Members of the Association of Students of Speech and Language Pathology – Logomotiva (Student Section for Hearing Impairments)

Assistant Professor Marina Milković, PhD, Associate Professor Luka Bonetti, PhD

## R you Ready to work in R?

Have you heard of the R program? If you're interested in research, you'll have to encounter "the big and scary" statistical analysis. We promise it doesn't have to be that scary. Come to our interactive workshop, learn how to use the R program to make data analysis more effortless, and how to present your work through top-quality visuals.

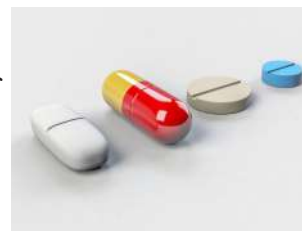

### AUTHORS

Andrea Gelemanović, PhD

## In scientists we trust. Or should we?

Are all of the randomized controlled clinical trials trustworthy or should we be critical when reading them? In this workshop, we will discuss examples of complementary and alternative medicine (CAM) for the treatment of anxiety and depressive disorders.



### AUTHORS

Professor Vladimir Trkulja, M.D., PhD

## Esthetic analysis and Digital Smile Design

Have you ever wondered if you could participate as a patient when designing your future smile? The future of communication between patient and stomatologist lies in cooperative designing of ones ideas and proceeding with them as precisely as possible. In this workshop, you will learn about smile and face analysis, and basic steps in Digital Smile Design as its benefits and drawbacks. After the presentation, it's time for you to become a dentist. Everybody will have the chance to make their own smile design for their patient following the basic rules of design. After the workshop you will have better insight into new technology in dentistry and maybe in the future you'll be able to design your own smile with your dentist.



Udruga studenata dentalne medicine

*Croatian Dental  
Students' Association,  
School of Dental  
Medicine, University of  
Zagreb*

### AUTHORS

Ana Gabud, Aneta Benković

Associate Professor Marko  
Jakovac, D.M.D, PhD

## Experience the unseen

This workshop is designed in an interactive form to provide knowledge and raise awareness about the everyday functioning of visually impaired people. The main focus of the workshop is to lay out key information regarding the implications of visual impairment on an individual. Through experiential activities, the participants will be able to learn and cognize a small part of what visually impaired people supervene in their day-to-day functioning. These activities include trying out doing a set of tasks while using glasses that simulate certain visual conditions, orientating with a white cane, and more.



*Students of Faculty  
of Education and  
Rehabilitation  
Sciences, University of  
Zagreb*

### AUTHORS

Doris Marie Greppin, Borna  
Mihaljević, Ana Runac, Amalija  
Petric

Associate Professor Sonja  
Alimović, PhD, Dominik Sikirić,  
M.Sc.





# Invited Workshop Authors



## Andrea Gelemanović, PhD

*Mediterranean Institute for Life Sciences, Split, Republic of Croatia*

Andrea Gelemanović is a molecular and computational biologist with a doctoral degree in genetic epidemiology obtained at the University of Split School of Medicine in Split, Croatia. She is currently employed as a postdoctoral researcher at the Mediterranean Institute for Life Sciences in Split, Croatia and works on several projects as a bioinformatic analyst of various -omics data. During her PhD her main research focus was the impact of human genetic polymorphisms on the susceptibility to various infectious diseases, while she is currently working on a project to understand the importance of cell-to-cell communication in cancer metastasis. She was awarded a British Scholarship Trust for a short-term research visit to the MRC Institute of Genetics and Molecular Medicine in Edinburgh, UK, and was

a winner candidate of the 2016 New Voices in Global Health initiative held at the World Health Summit in Berlin, Germany. She is also involved in various projects for education (Erasmus+ PROMISE), science popularization (runner-up at the international science communication competition FameLab 2013) and organizes summer schools in bioinformatics (since 2021) and science communication (2022).




## Professor Vladimir Trkulja, M.D., PhD

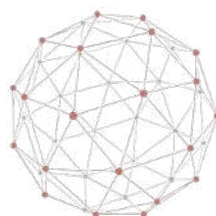
*Department of Pharmacology, School of Medicine, University of Zagreb*

Professor Vladimir Trkulja, MD, Ph.D., is a full-time professor of pharmacology at the School of Medicine, University of Zagreb. He graduated from the School of Medicine in Zagreb. After completing his internship as a doctor, he participated in the Croatian Army Medical Corps from 1991 to 1994. He was then employed at the Department of Pharmacology, School of Medicine, University of Zagreb. In 1995, he received his master's degree, and in 1997, his doctorate. He is an editor and reviewer in numerous scientific publications and the author or co-author of over a hundred professional papers. He gained experience in the areas of drug development and regulation, evaluation of therapeutic interventions, pharmacokinetics, and systematic reviews/meta-analyses at the Center for Genetic Engineering and Biotechnology (Havana, Cuba), Baxter Healthcare International Renal Division (Chicago, USA), Serum Institute (Pune, India), Fumedica GmbH (Herne, Germany), Genera (Zagreb, Croatia), Hindustan Antibiotics (Pune, India), Elanex Pharma (Seattle, USA).

Cuba), Baxter Healthcare International Renal Division (Chicago, USA), Serum Institute (Pune, India), Fumedica GmbH (Herne, Germany), Genera (Zagreb, Croatia), Hindustan Antibiotics (Pune, India), Elanex Pharma (Seattle, USA).



# CROSS Partners



# Donations

**AGROPOŠTA**  
HANDMADE ORGANIC LEMONADES



**Bužan**  
ART·COFFEE·BAR

**CVH**  
CENTAR ZA VOZILA HRVATSKE



**chillout**  
hostel zagreb downtown sleep cheap | same for fun



**Curte**  
ZAGREB D.O.O.



**SONIMED** d.o.o.



**VEDRINI**  
prepusti se vedrini!

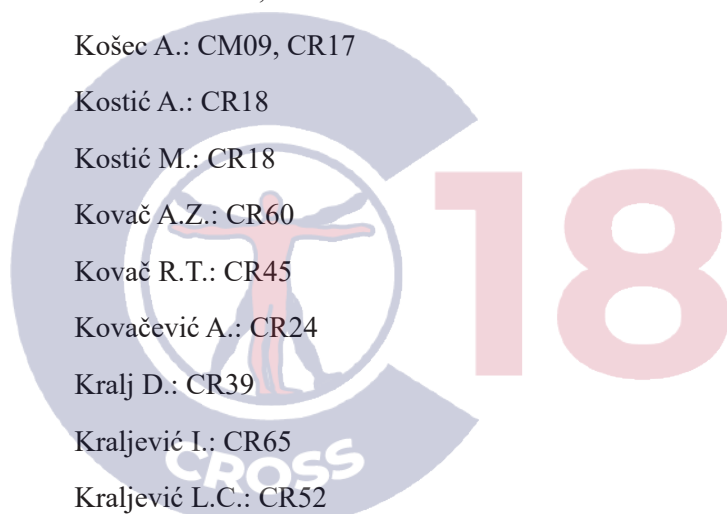




# Author Index

- Alaber M.: CR32, CR79  
 Alfirević A.: CR15, CR75  
 Ališić A.: CR05  
 Altabas V.: CR19, CR53  
 Andrešić M.: CR61  
 Arambašić L.: CR50  
 Babić M.: CR03  
 Babkova I.: CR09  
 Bagarić M.: CR47  
 Bajan M.: CR64  
 Baković D.: CR15  
 Bakula M.: CR67  
 Baldani N.: CR04, CR46  
 Bardač K.: CR33  
 Baretić M.: CR18, CR49  
 Barić I.: CR54, CR57  
 Barić P.: CR15, CR75  
 Barišić A.: CR58, CR75  
 Barišić I.: CR30, CR70, CR77  
 Barišić L.N.: CR33  
 Benčić J.: CR64  
 Bielen L.: CR76  
 Bilić H.: CR45  
 Bjelić Dž.: CR64  
 Blažević L.: CR77  
 Blažević L.D.: CR33, CR37  
 Boban M.: CR60, CR66  
 Bobek M.: CR41  
 Bognar S.: CR64  
 Borlinić I.: CR14, CR37  
 Borščak Tolić N.: CR66  
 Bošnjak J.: CM09, CR59  
 Botica A.: CR35  
 Božek T.: CM01  
 Brajković T.: CR11  
 Braniša A.: CR37  
 Brbora M.: CR03  
 Brekalo K.: CR14, CR37  
 Brenner E.: CR40  
 Budimir K.: CR11, CR45  
 Bukovac A.: CR44, CR71  
 Bukvić M.: CR45  
 Bulić L.: CR40  
 Buljan G.: CR44, CR71  
 Bumči B.: CM06, CR24, CR35  
 Burić S.: BS02, BS04, BS11  
 Canecki-Varžić S.: CR31  
 Centner H.: CR31  
 Chiddenton H.M.: BS01, BS02, BS11  
 Cvitanović M.: CR14  
 Čala A.: CR56  
 Čikić B.: CM05  
 Čolaković L.: CM06, CR24, CR35  
 Čuković-Čavka S.: CR06  
 Čular K.: CR81  
 Ćorić L.: BS08, BS09, BS10  
 Ćorić M.: BS10, CR45  
 Ćuk A.: CR28, CR63  
 Ćuk M.: CR47, CR48, CR79  
 Ćurković A.: CR08  
 Dedić Plavetić N.: CR64  
 Dolački L.: CR42  
 Dorešić K.: CR29, CR41  
 Duraković N.: CR72  
 Dušek T.: CR56  
 Đekić D.: CR28, CR63  
 Edl M.: CM06, CR24, CR35  
 Ercegovac L.: CR55

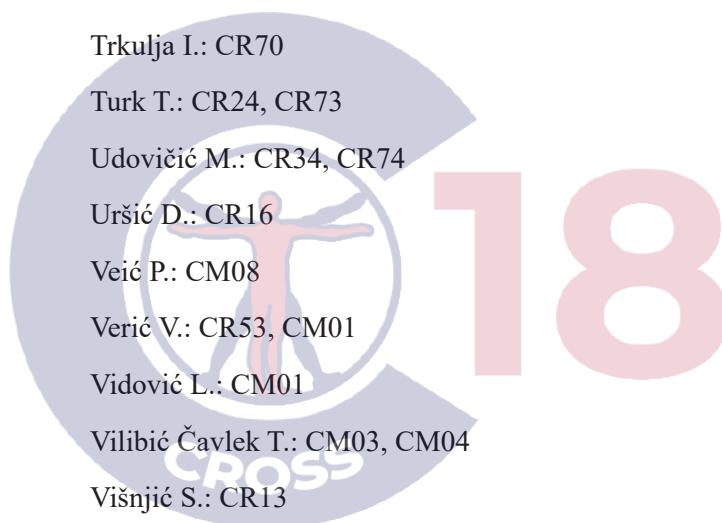
Fatyanova A.: CR09	Jelenić J.: CR67
Fejzić A.: CR58, CR68	Jeričević K.: CR20
Filipeć Kanižaj T.: CR14	Jugovac V.: CR04, CR46
Fotez La.: CR29, CR41, CR49	Jukić L.: CR80
Fotez Lu.: CR41, CR49, CR55	Jukić M.: CR60
Franić H.: CR58, CR68	Jukić T.: CR27
Gabrić A.: CR49, CR55	Kajan J.: O01
Galić P.: CR50	Kalauz Ma.: CM02
Galić S.: CR25	Kalauz Mi.: CM02
Galiot L.: CR29, CR43	Kalogjera L.: BS06, BS07, BS12
Gavrančić M.: CR04, CR46	Karas I.: CR58
Gečević R.: CR38	Kaštelan Ž.: CM05
Glavaš Weinberger D.: CR05	Katić B.: O02
Gliha A.: CR13	Kelčec L.: CR20
Goluža E.: CR36	Klepač L.: CR57
Gomerčić Palčić M.: CR03	Klobučar A.: CR17, CR72
Gračanin A.: CR01	Knežević V.: CR13
Grbavac J.: O01	Knez N.: CR20
Grgat M.: CR69	Knotek T.: CR30
Gripp M.: CR09	Komljenović S.: CR74
Grubeša M.: CR29	Koprivica J.: CR10
Gržan D.: CR48, CR80	Košar T.: CR17, CR72
Gudelj Gračanin A.: CR01	Košec A.: CM09, CR17
Gumzej Z.: CR08	Kostić A.: CR18
Guštek S.: CR34	Kostić M.: CR18
Harak K.: CR69	Kovač A.Z.: CR60
Hasnaš L.: CR07, CR22	Kovač R.T.: CR45
Hauptman D.: CR41	Kovačević A.: CR24
Herceg S.: CR66	Kralj D.: CR39
Horvat P.: BS03, BS05, BS10	Kraljević I.: CR65
Isaakyan Y.: CR09	Kraljević L.C.: CR52
Ister L.: CR69	Krišto M.: CR21
Ivanišević L.: CR69	Krobot Čutura N.: CM07
Ivanović Martić L.: O02	Kržak T.: CR51, CR54
Jakšić O.: CR25	Kukić S.: CR21, CR39, CR48



Kulaš M.: CR48, CR80  
Kuliš T.: CM05  
Kurtin A.: CR81  
Kušec R.: CM08  
Kvolik S.: O01  
Lacković M.: BS01, BS02, BS05  
Lauš K.: CR31  
Leskovar D.: CR63  
Letilović T.: CR23  
Linarić Lipnjak M.: BS01, BS03, BS05  
Listeš A.: CR73  
Ljubas Kelečić D.: CR75  
Ljubičić Đ.: CR38  
Ljubojević Hadžavdić S.: CR15  
Loje L.: CR51, CR54  
Lovrenčić A.: CR74  
Lovrenčić L.: CR48  
Lucijanić M.: CM08  
Lugović-Mihić L.: CR42  
Lukić M.: CR16  
Ljulj H.: CR74  
Majetić S.: CM10  
Marasović I.: CR38  
Marčinković N.: CR68  
Marić Brozić J.: CR29  
Marković M.: CR52  
Marković S.: CM09, CR59  
Masle A.M.: CR16  
Masnec S.: CM02  
Matek T.: CR12  
Matić L.: CM06, CR50  
Matić S.: CM06  
Matijašević L.: CR30, CR70, CR77  
Matijević A.: CR70  
Mažić I.: CR46  
Medaković P.: CR60  
Merćep I.: CR33  
Mikuc B.: CR12  
Mikulić D.: CR70  
Mikulić L.: CR07, CR22  
Miličević O.: CR30, CR77  
Miljanić K.: CM10, CR57  
Mioč P.: CR26  
Miočić Z.: CR50  
Miočinović F.: CR70  
Mitrović Z.: CR43  
Mokos M.: CR27  
Mrzljak A.: CM03  
Mujkić A.: CM10  
Nađ M.: CR78, CM11  
Negovetić P.: CR66  
Nešković N.: O01  
Nežić P.: CR34  
Nikše L.: CR26  
Ninković D.: CR54  
Novak N.: CR61  
Novosel L.: CR55  
Novoselović B.: CR05  
Orbanić A.: LR01  
Oroz K.: BS08, BS09  
Ožanić Bulić S.: CR40  
Pajić A.: CR13  
Palac L.: BS08  
Papeš D.: CR20  
Parać E.: CR66  
Pašić H.: CR35  
Pavičić Baldani D.: CR46  
Pavić T.: CR11, CR39  
Peček M.: LR01  
Pečevski V.: CM03, CM04



Penava M.: CR81  
 Perak E.: CR01  
 Perić S.: CR21  
 Periša K.: CR02  
 Periša M.: CR02, CR23  
 Petani A.: CM03, CM04  
 Petković Ramadža D.: CR57  
 Petračić I.: CR13  
 Plečko V.: CR01  
 Pleško E.: CR78, CM11  
 Pokos J.: O01  
 Pospišil M.: CR78, CM11  
 Potrebica P.: CR19  
 Precali A.: CR65  
 Prigl I.: CR16  
 Prkačin I.: CR44, CR71  
 Prnjak J.: CR42  
 Putrić Posavec J.: CM02  
 Radić-Krišto D.: CR37  
 Radoš I.: CR36  
 Ranilović D.: CR38  
 Ratkajec V.: CR11  
 Relota P.: CR23  
 Remenar L.: CR23  
 Rosan T.: CR67  
 Rubić F.: CR08  
 Rudež L.K.: CR27  
 Samardžić J.: CR10  
 Santini J.: CR26  
 Santini M.: CR26  
 Sarukhanyan I.: CR09  
 Savić V.: CM04  
 Schönberger E.: CR31  
 Schwarz L.: CR23  
 Sečan T.: CR07, CR22  
 Silovski T.: CR81  
 Skorić B.: CR28  
 Smoday I.M.: BS07, BS09, BS12  
 Sorić E.: CM08  
 Sorić M.: CR32, CR61, CR79  
 Stanković T.: CR32, CR79  
 Stemberger Marić L.: CR12  
 Sulić P.: CR80  
 Šagud M.: CR36  
 Šarić D.: CM05  
 Šimičević L.: CR63  
 Škrgatić L.: CR04  
 Šušak F.: CR76  
 Telarović S.: CR02, CR51  
 Terzić P.: CR06  
 Tiku A.: CR06  
 Tkalčec I.: CM10  
 Tkalec K.: CR06  
 Tokić I.: CR26  
 Tomašić L.: LR01  
 Tomičić G.: CM07  
 Trbušić M.: CR59  
 Trkulja I.: CR70  
 Turk T.: CR24, CR73  
 Udovičić M.: CR34, CR74  
 Uršić D.: CR16  
 Veić P.: CM08  
 Verić V.: CR53, CM01  
 Vidović L.: CM01  
 Vilibić Čavlek T.: CM03, CM04  
 Višnjic S.: CR13  
 Vlahek T.: CR20  
 Vraneš H.: BS04, BS06, BS07  
 Vrdoljak A.: BS03, BS08, BS10  
 Vukoja D.: CR38



Vuković V.: BS04, BS06, BS11

Vuksan-Ćusa Z.: CR36

Vusić L.: CR53

Zekulić T.: CM05

Zeljковиć I.: CR26

Zibar L.: O02

Zimak Z.: CM05

Žigman T.: CR57

Živko J.: CR61

Živko M.: CR53, CM01

Živković N.: CR47







STUDENT  
SKI ZBOR  
SVEUČILIŠTA  
U ZAGREBU

